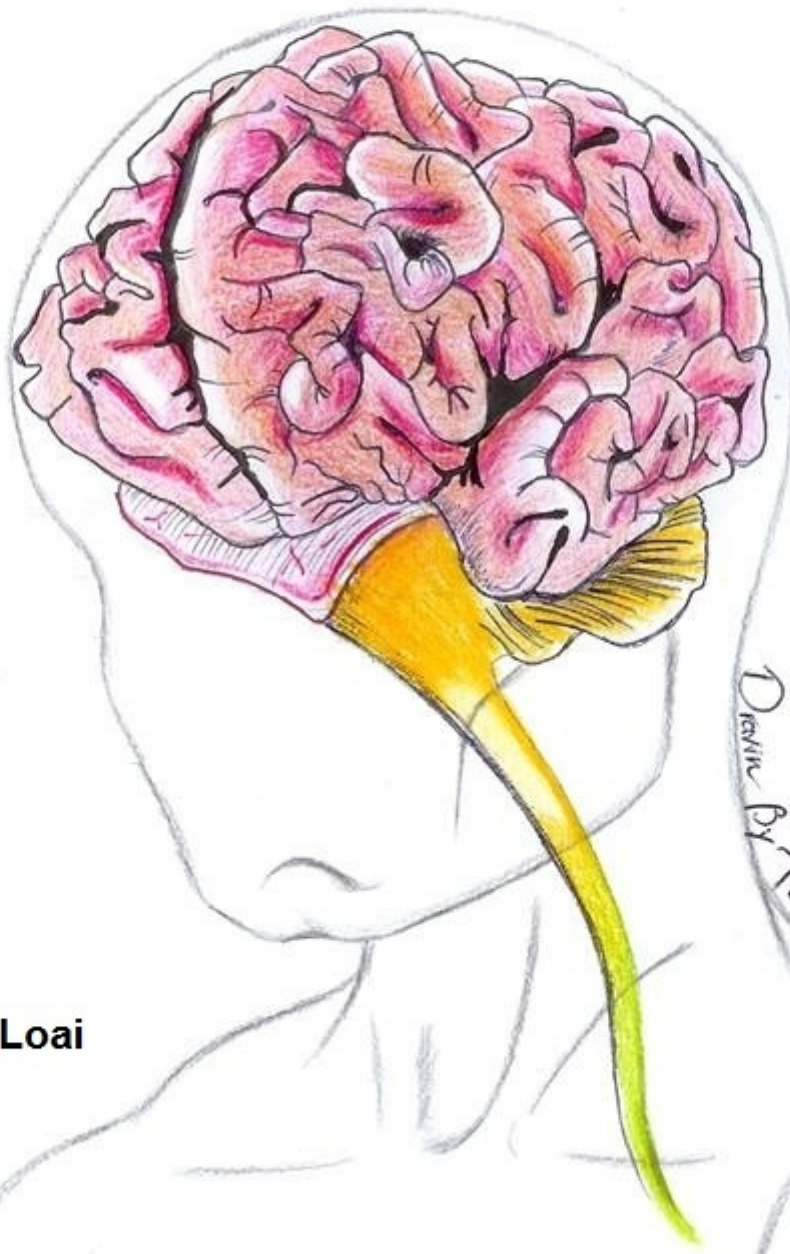


CENTRAL NERVOUS SYSTEM

- Handout
- Sheet
- Slide

- Anatomy
- Physiology
- Pathology
- Biochemistry
- Microbiology
- Pharmacology
- PBL



Drawn By Tariq Bushraaq...

Done By:

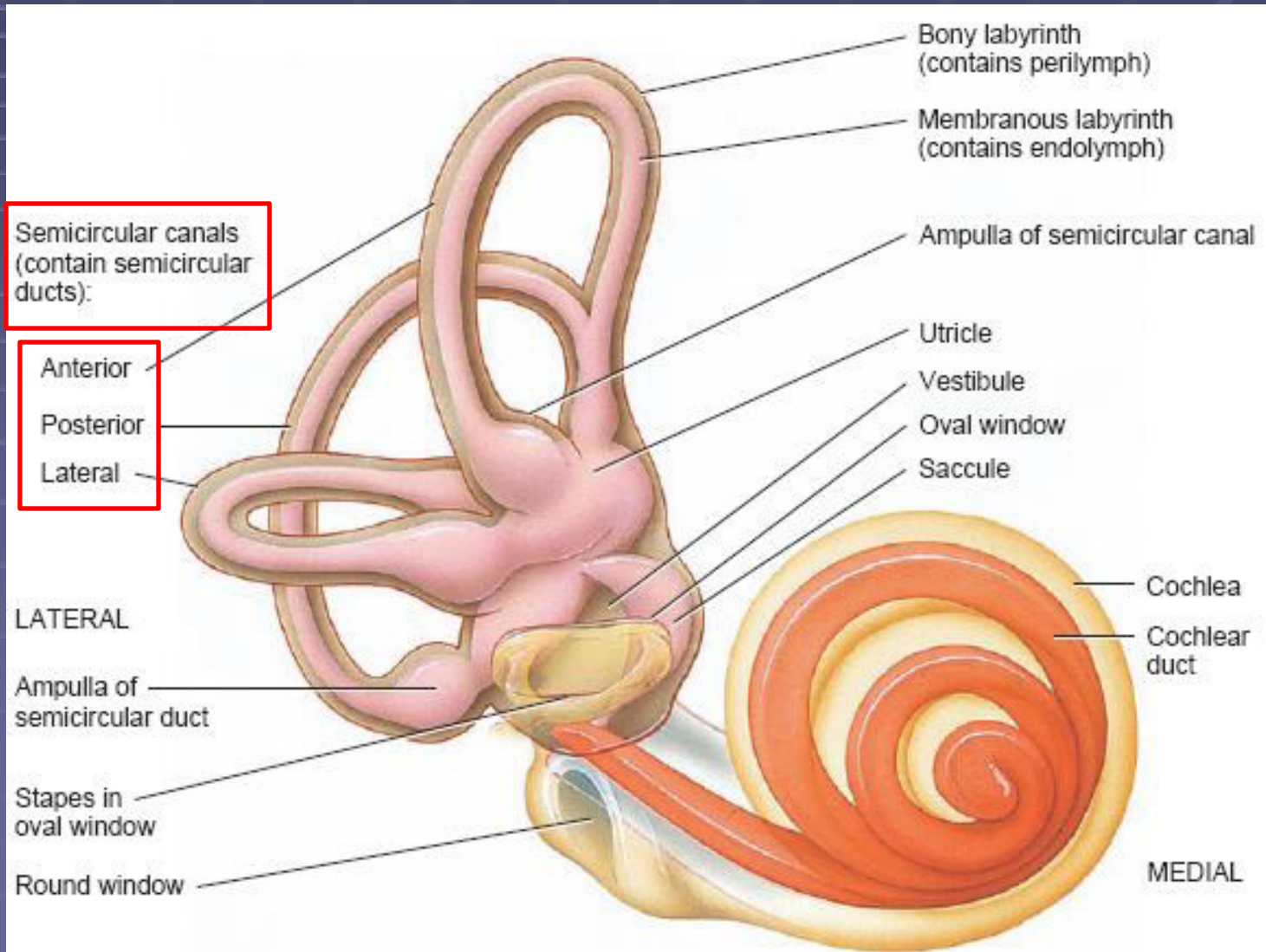
Dr. Name: **Dr. Loai**

Lec #: **11**

The Vestibular System

Anatomy of the ear

Internal ear

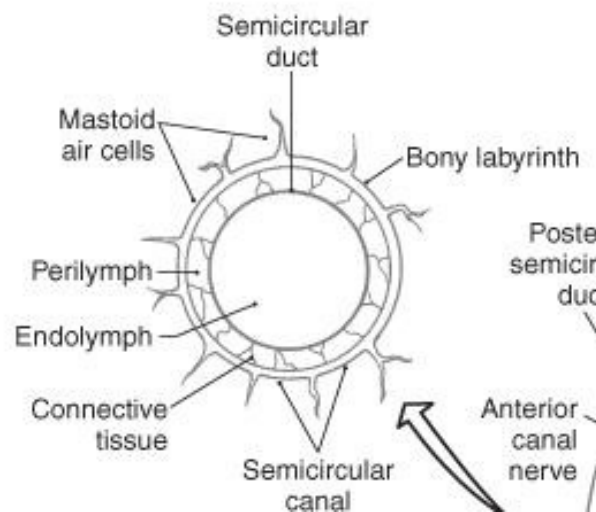
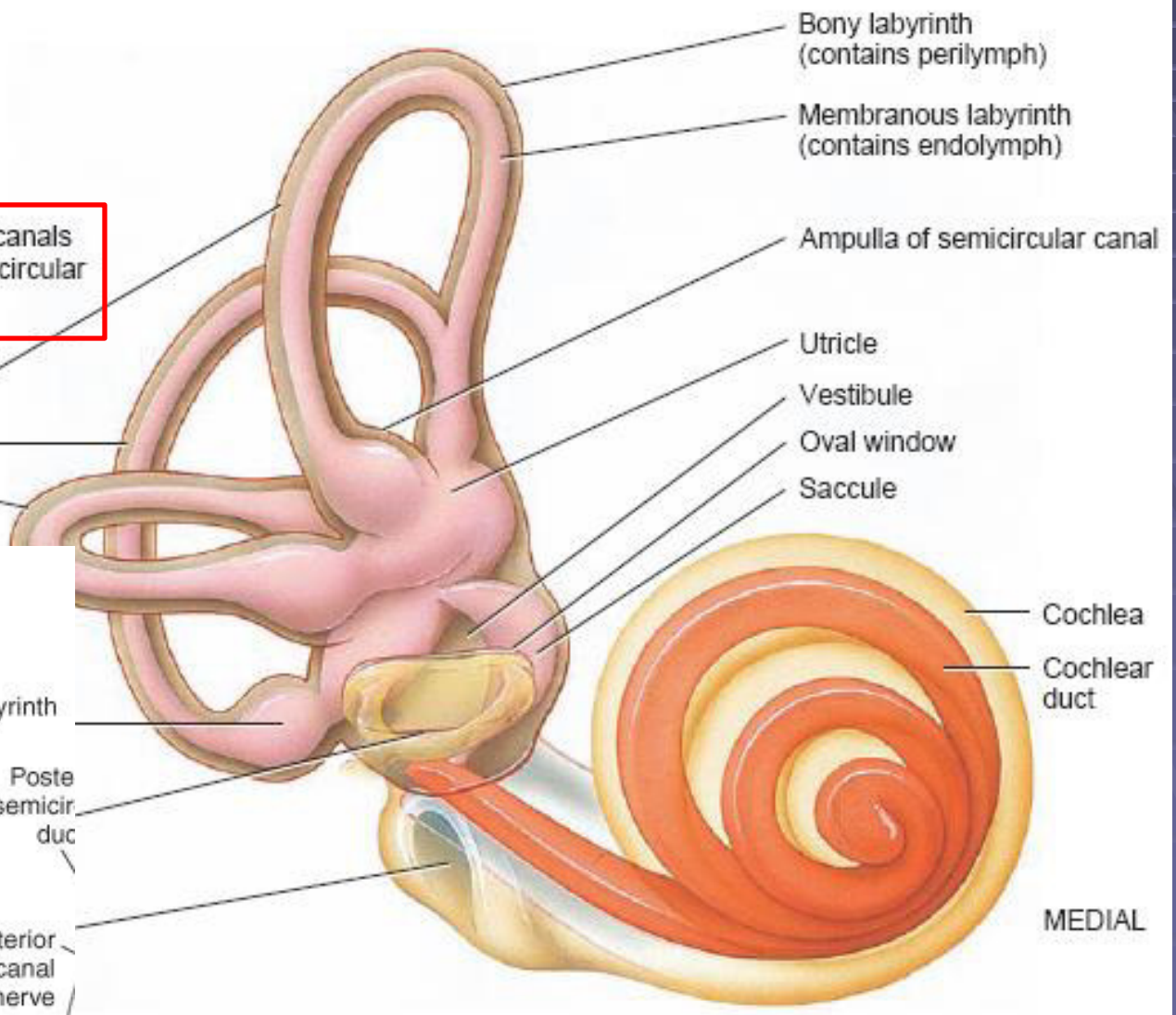


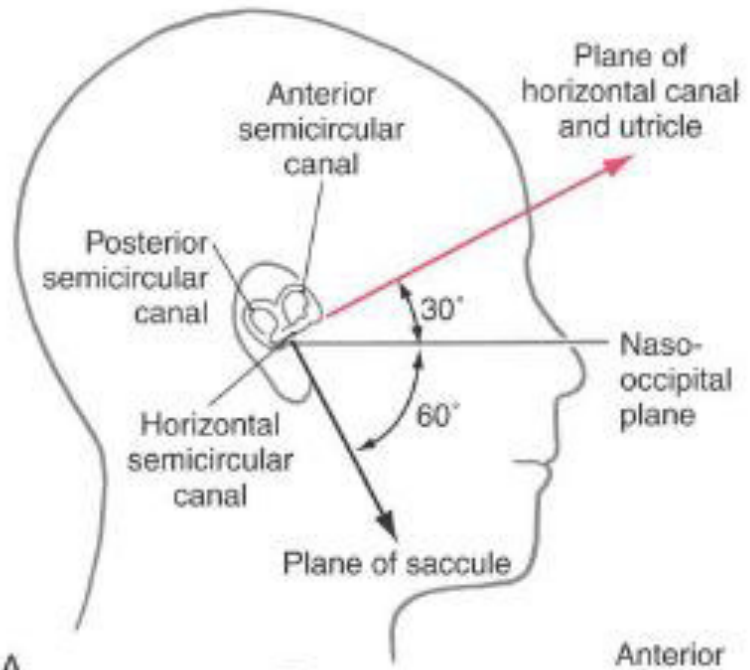
Anatomy of the ear

Internal ear

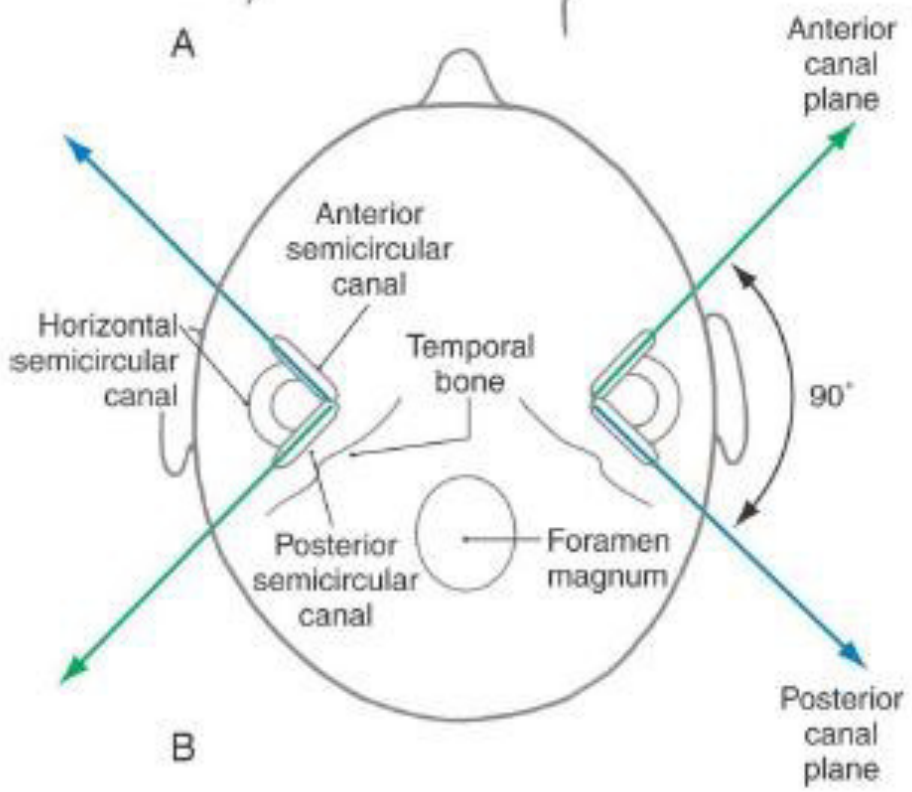
Semicircular canals (contain semicircular ducts):

- Anterior
- Posterior
- Lateral

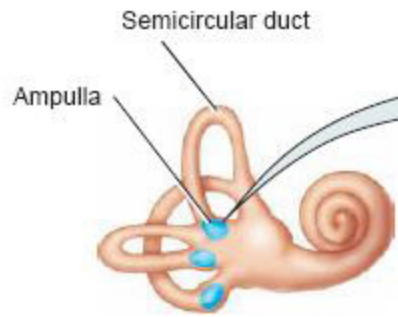




A

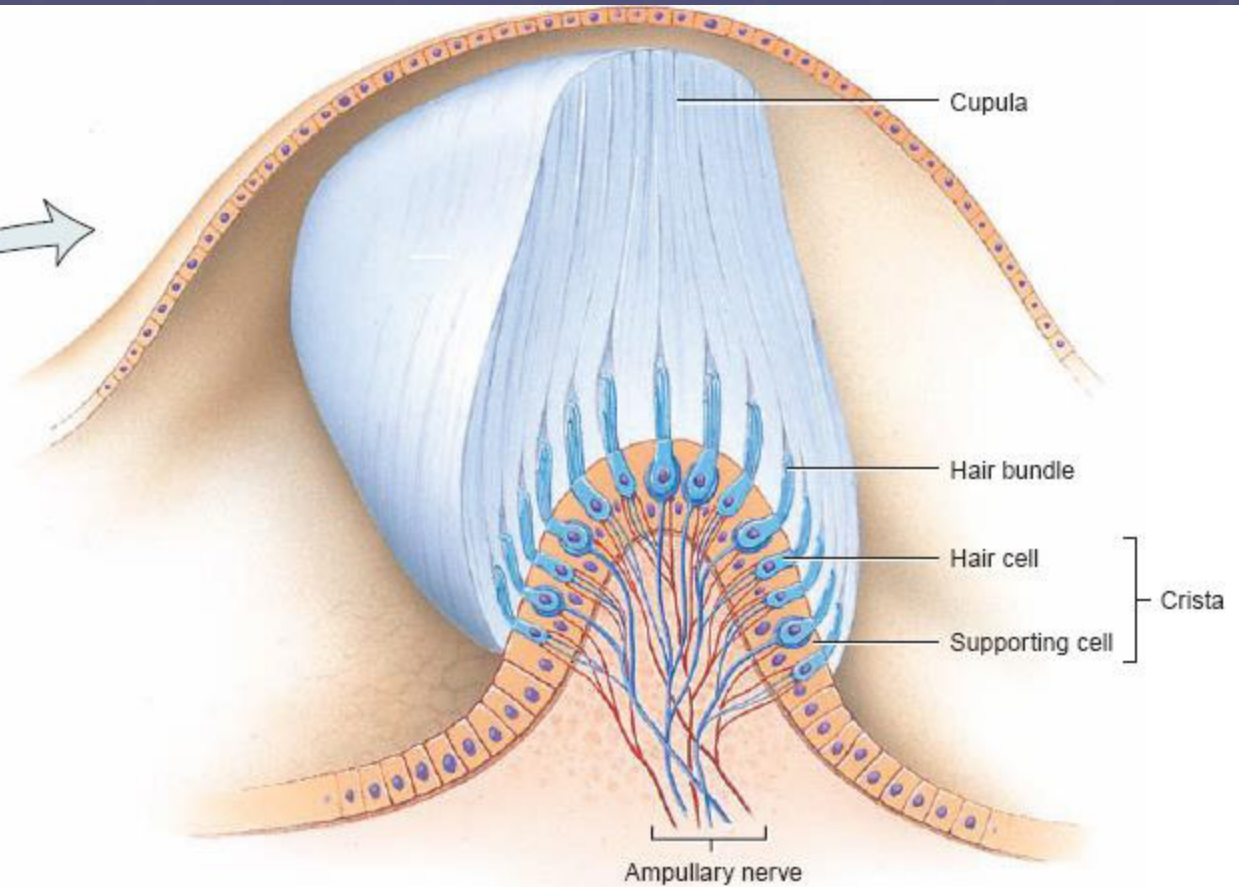


B



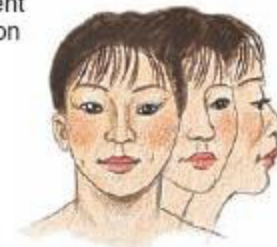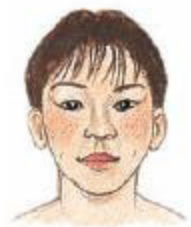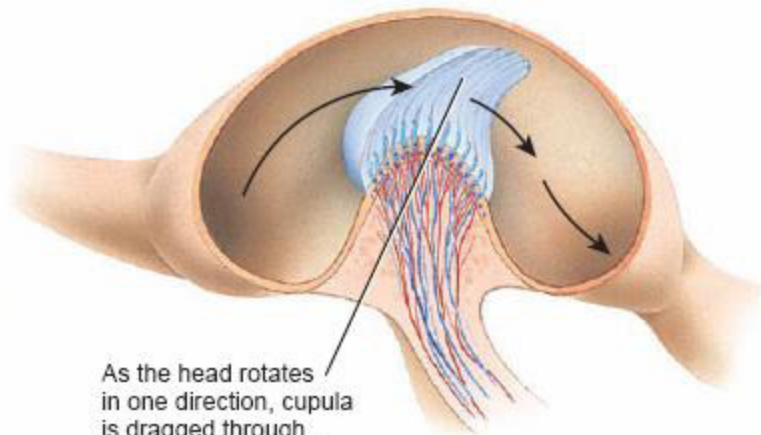
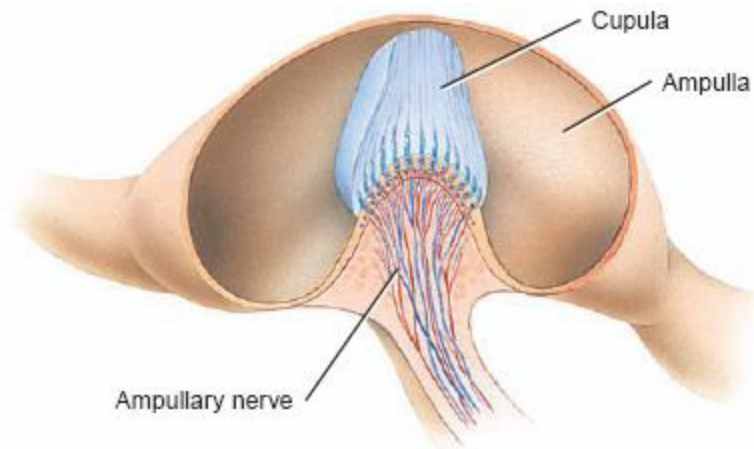
Location of ampullae of semicircular ducts (contain cristae)

Key:
Sensory fiber
Motor fiber

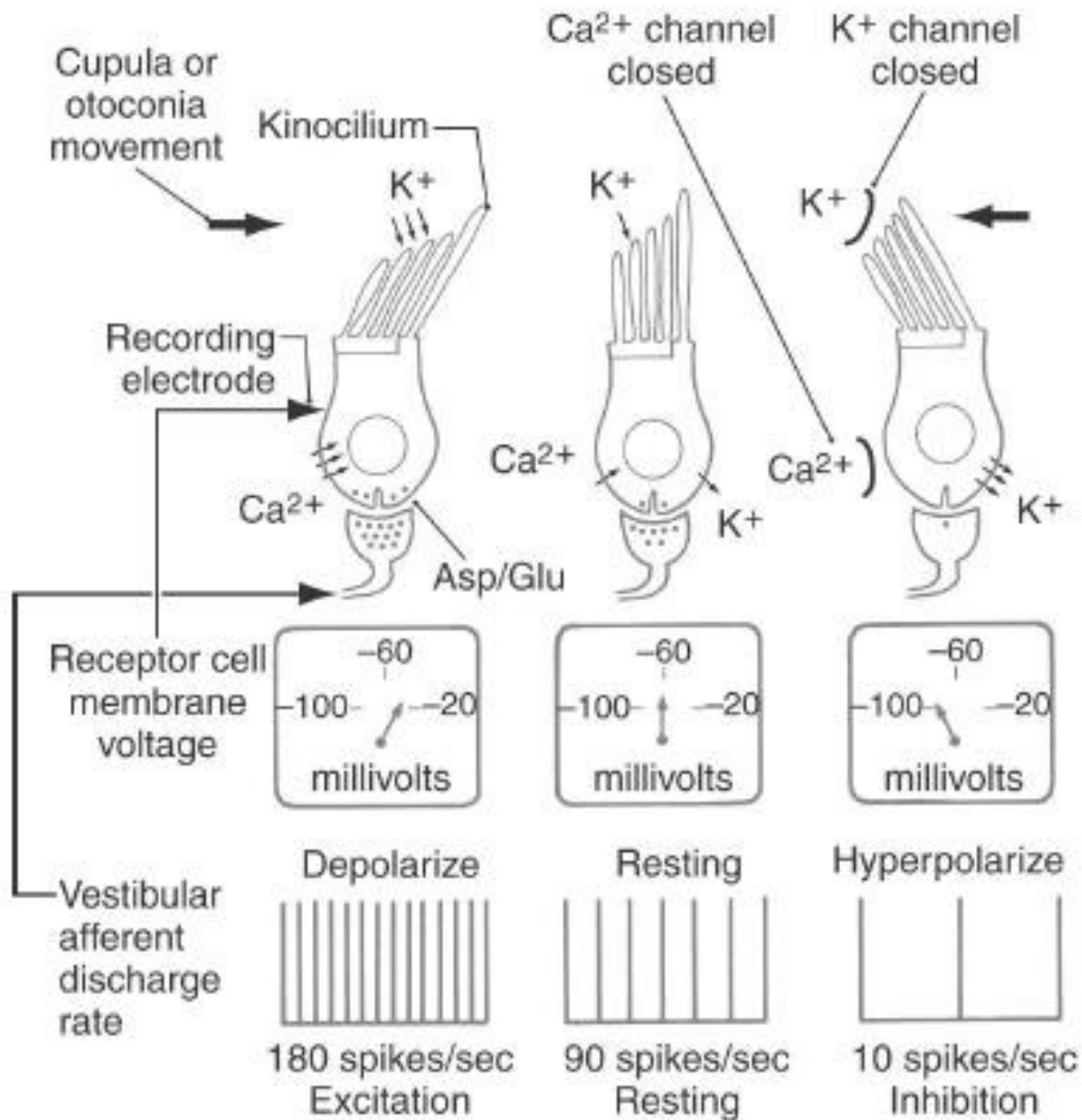


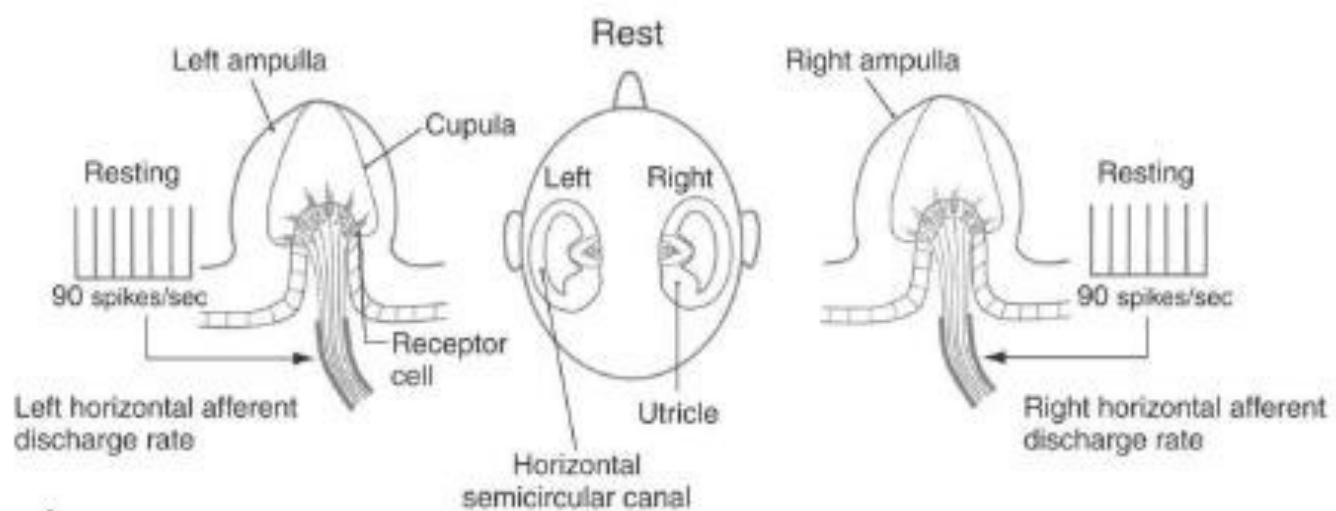
(a) Details of a crista

Ampulla of Semicircular canal

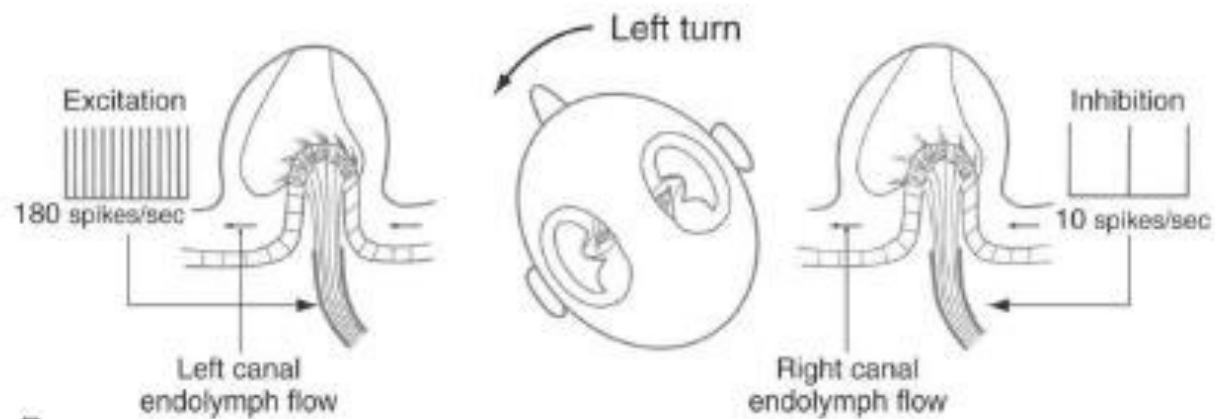


(b) Position of a cupula with the head in the still position (left) and when the head rotates (right)

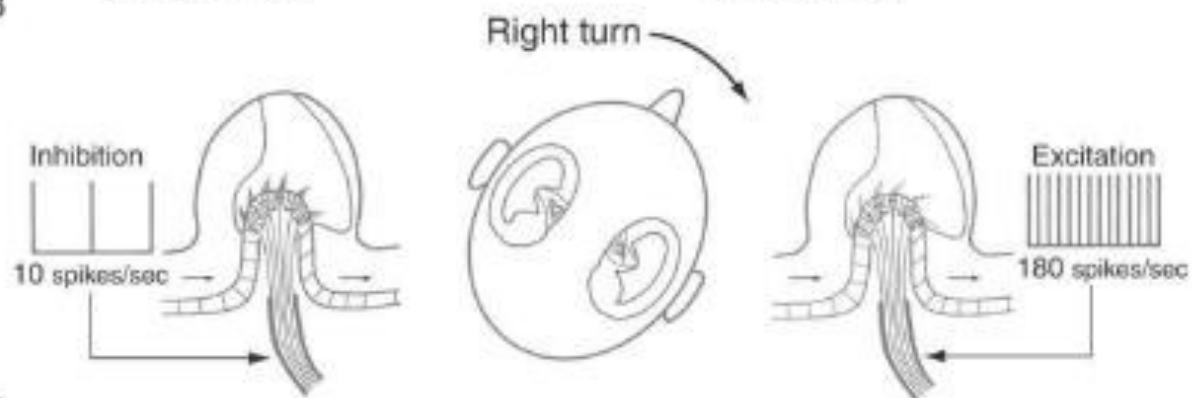




A



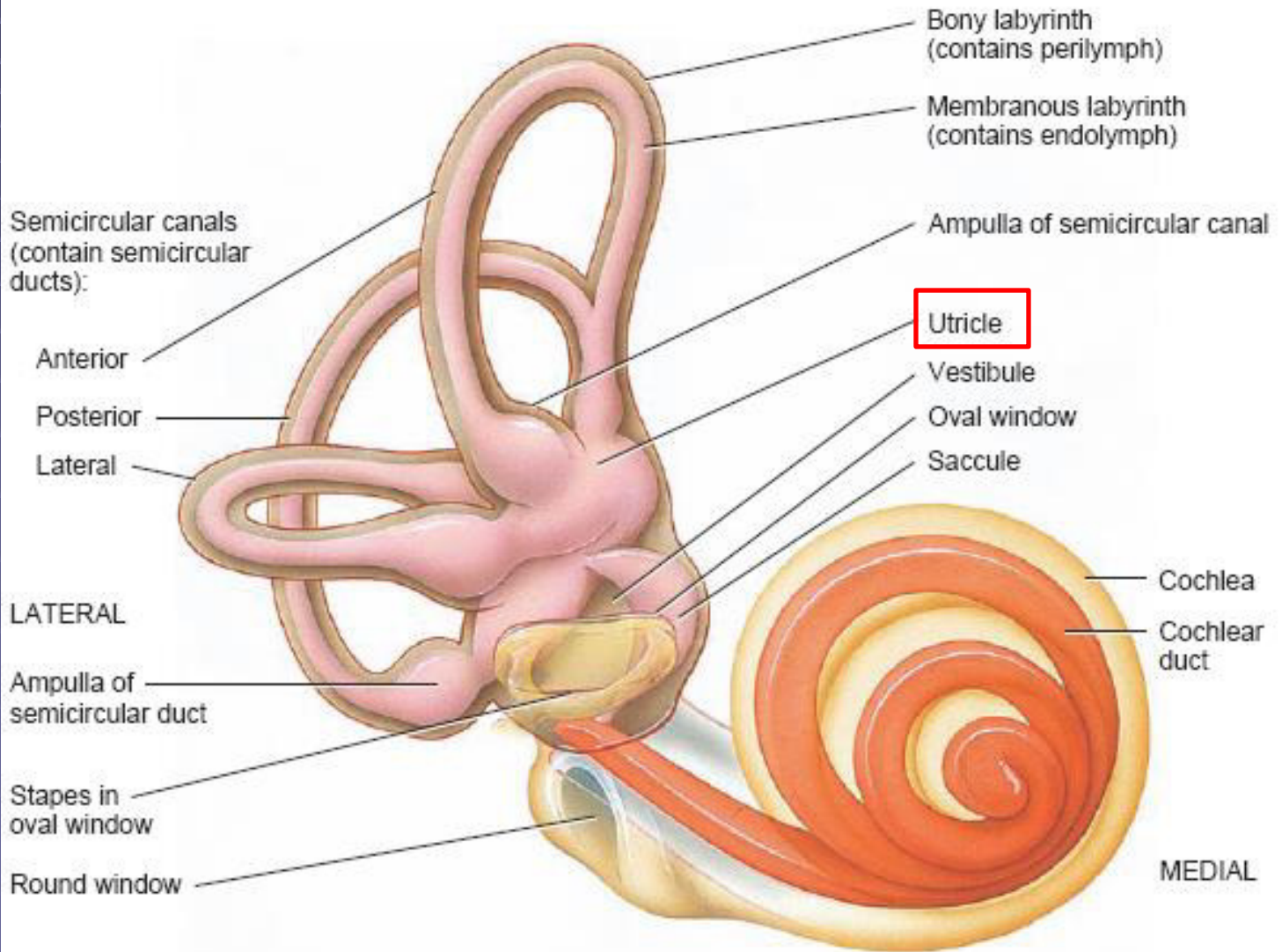
B



C

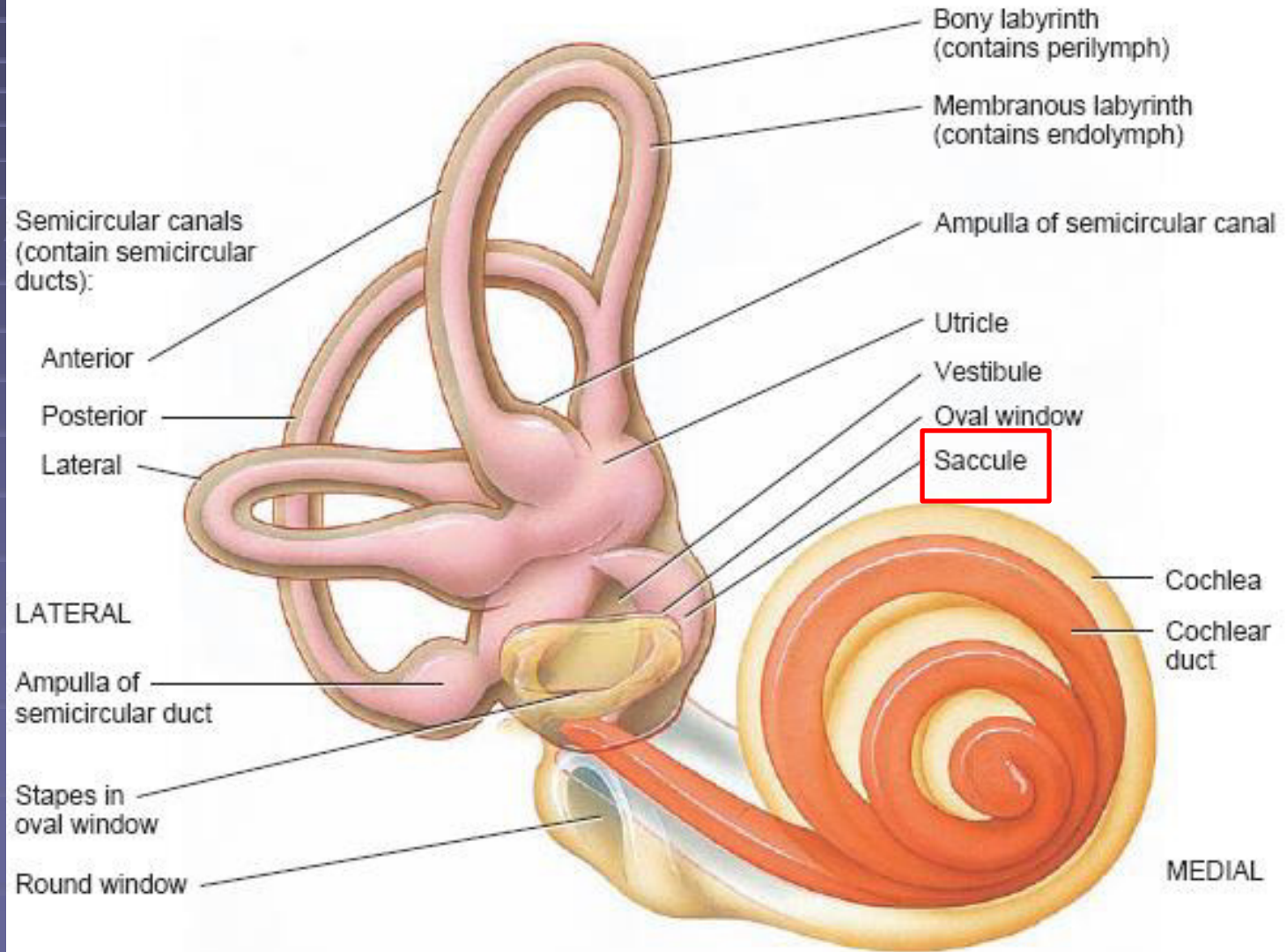
Anatomy of the ear

Internal ear



Anatomy of the ear

Internal ear



Macula and otolith organ

(C)

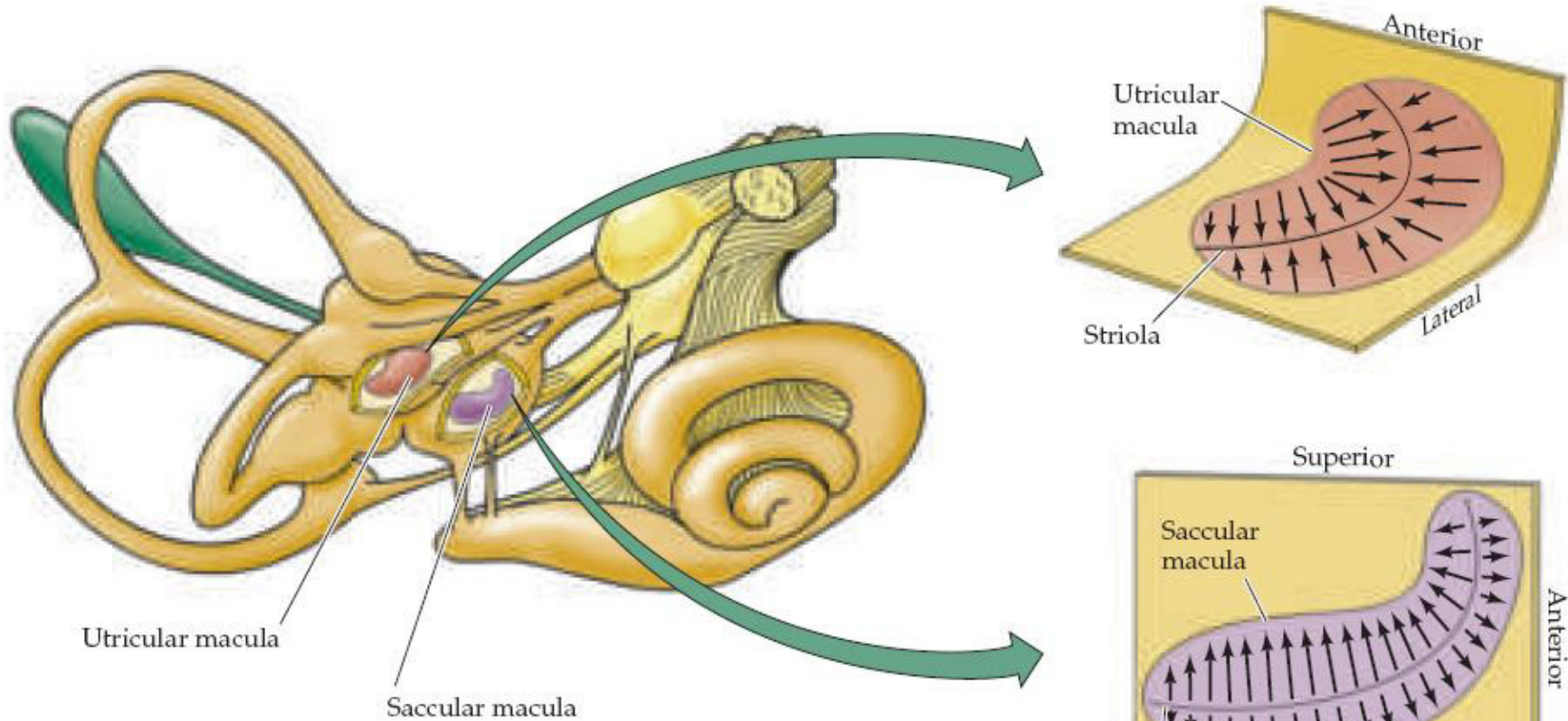
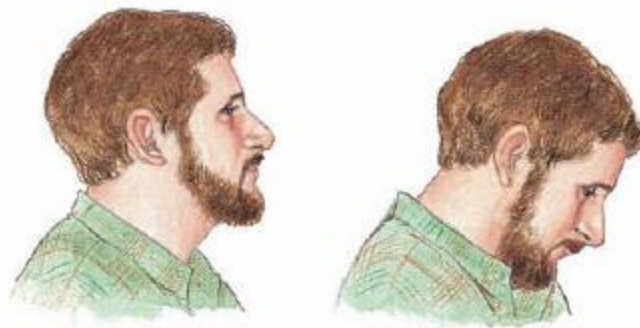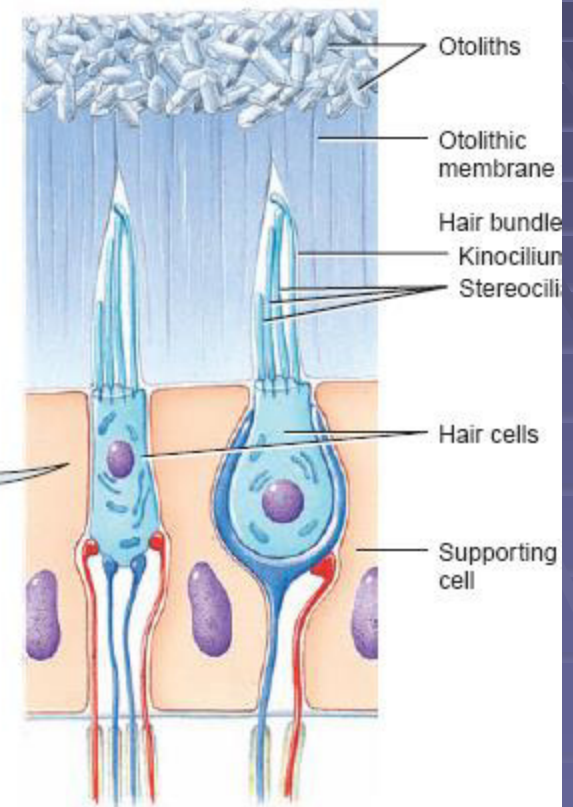
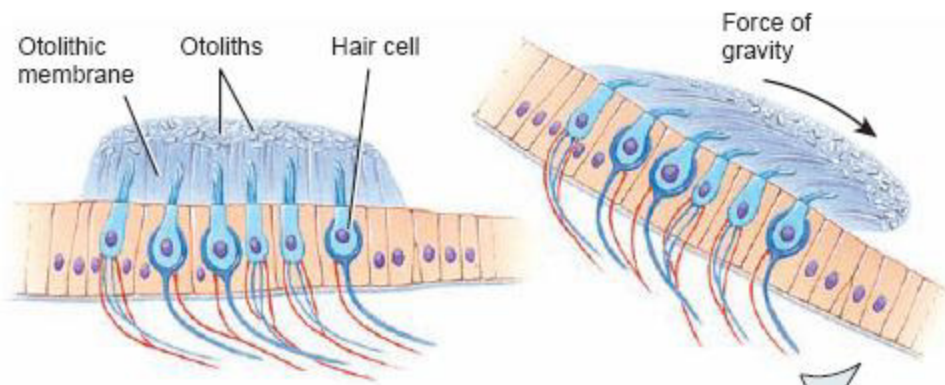


Figure 13.4 Morphological polarization of hair cells in the utricular and saccular maculae. (A) Cross section of the utricular macula showing hair bundles projecting into the gelatinous layer when the head is level. (B) Cross section of the utricular

Macula and otolith organ

(a) Overall structure of a section of the macula

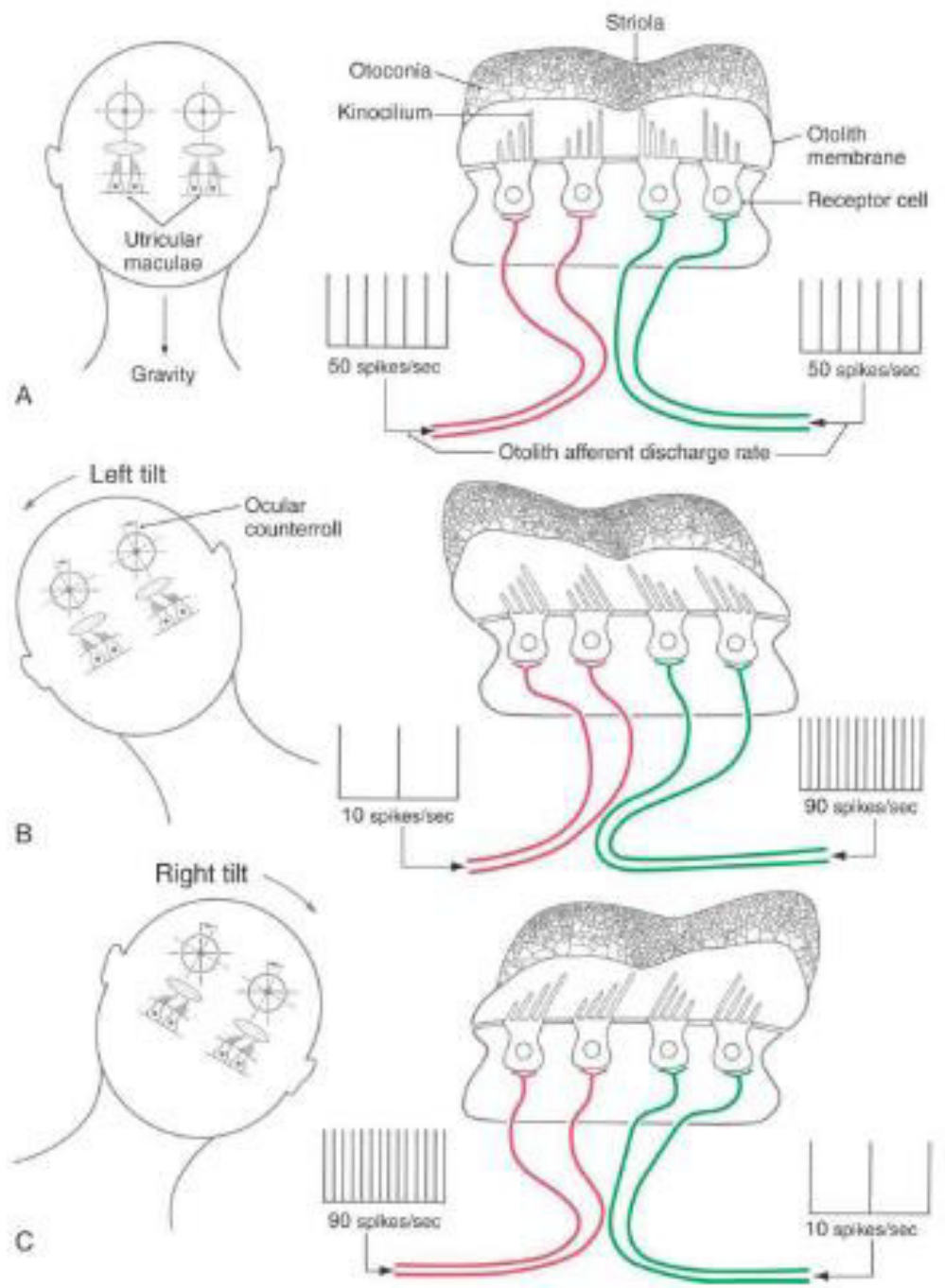


Head upright

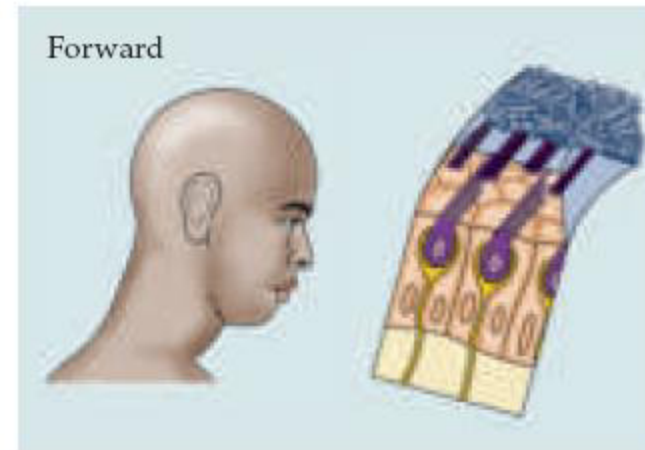
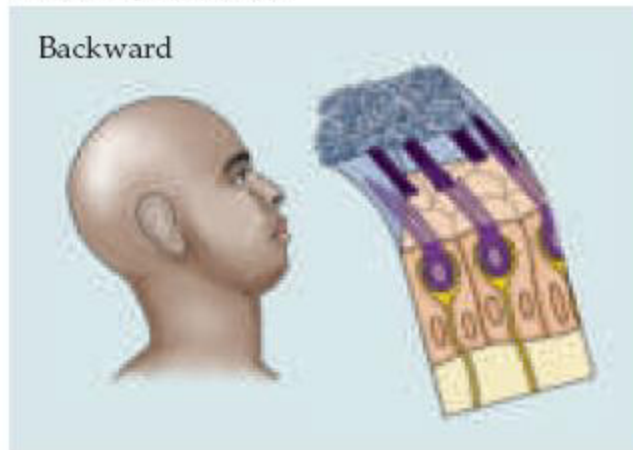
Head tilted forward

(c) Position of macula with head upright (left) and tilted forward (right)

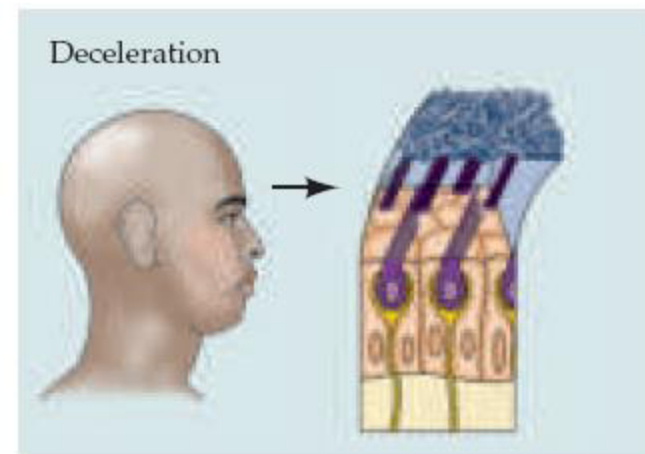
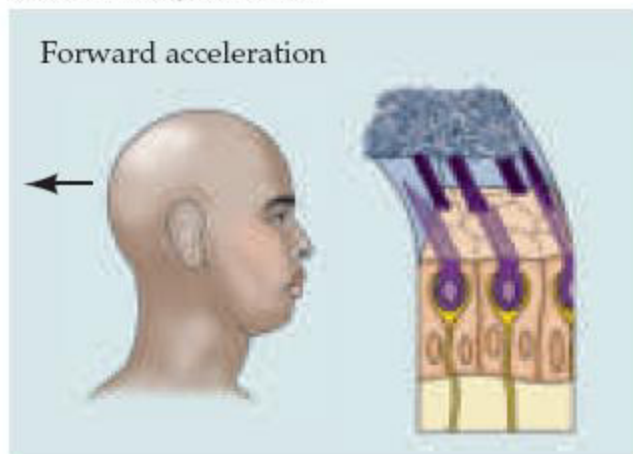
(b) Details of two hair cells



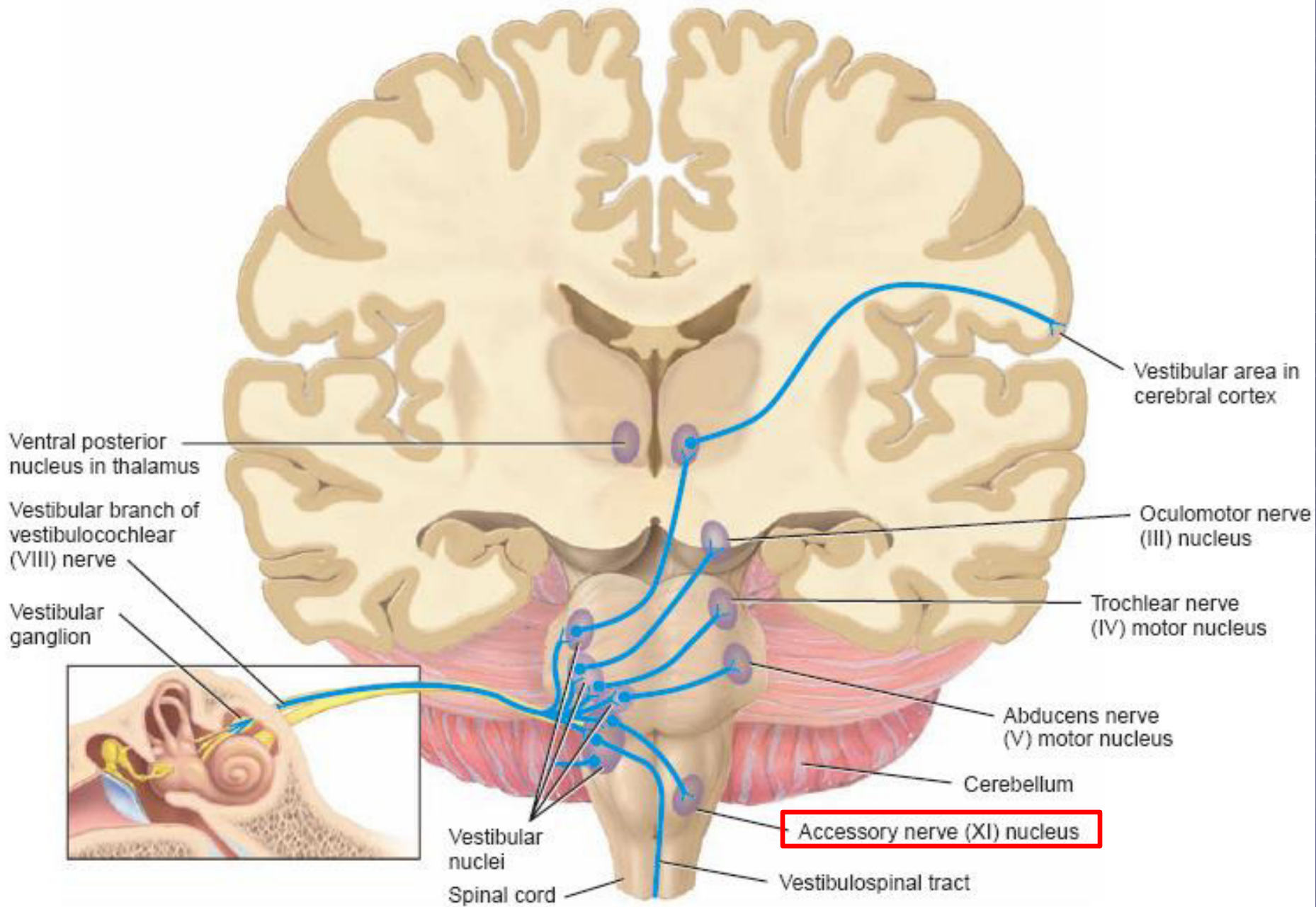
Head tilt; sustained

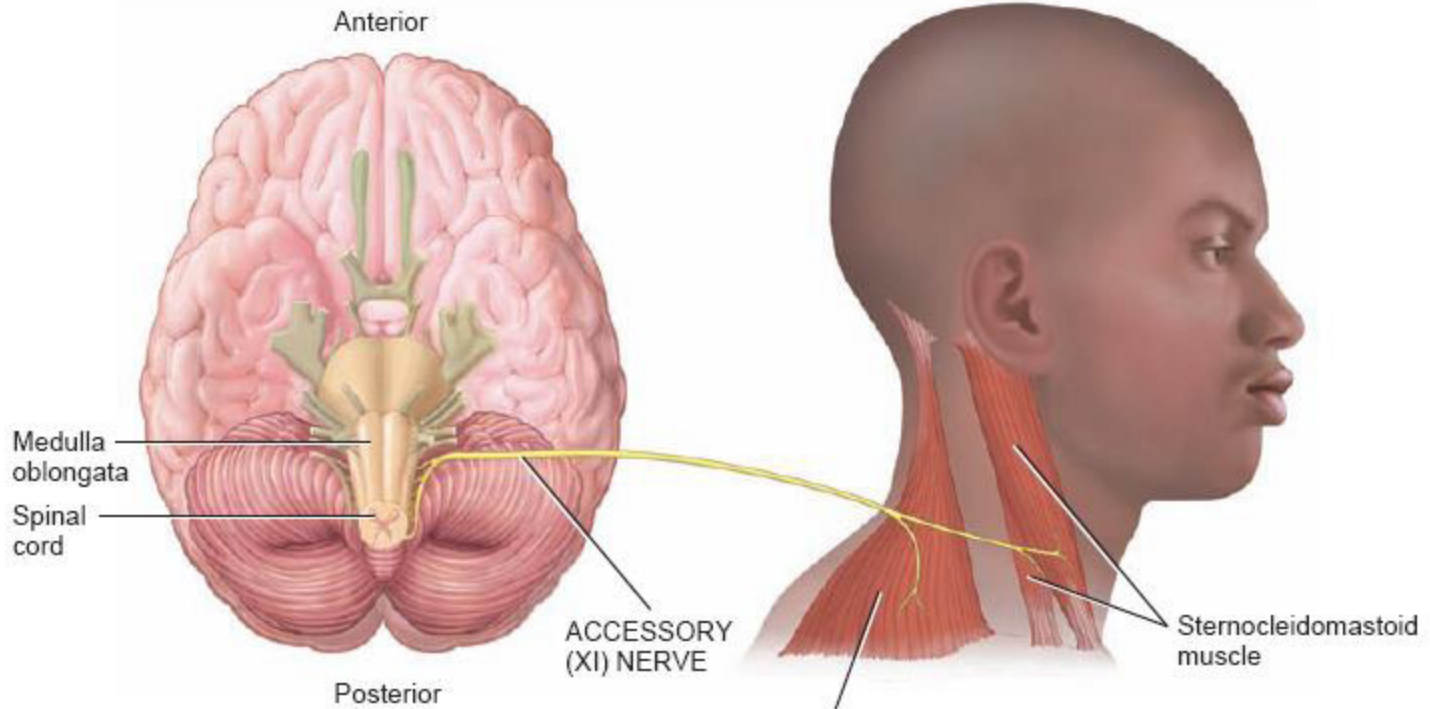


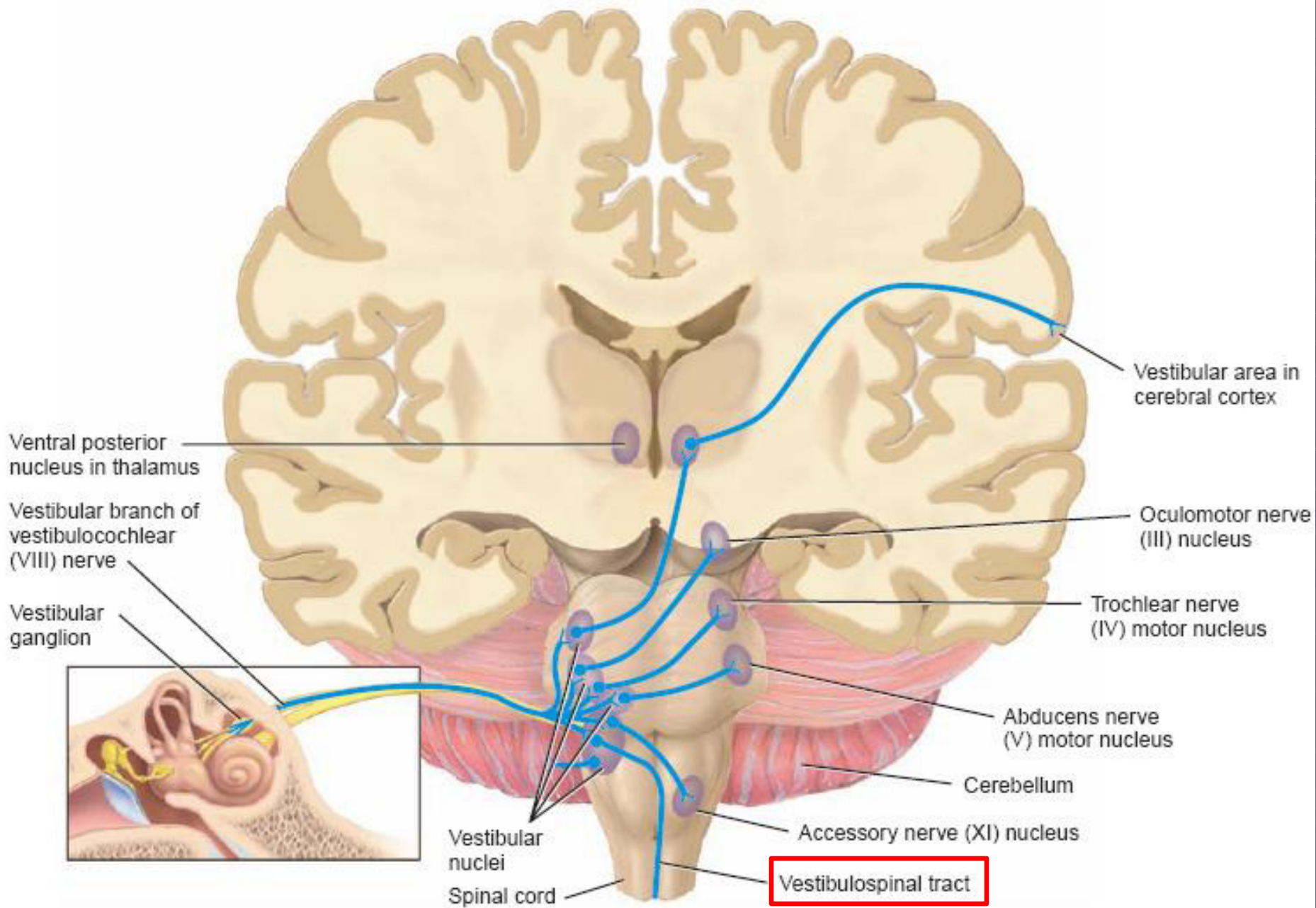
No head tilt; transient

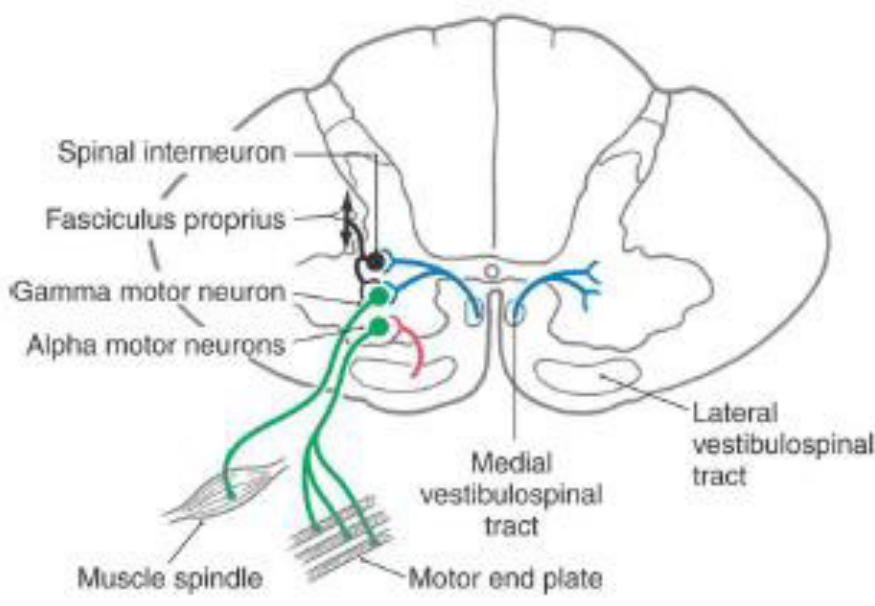
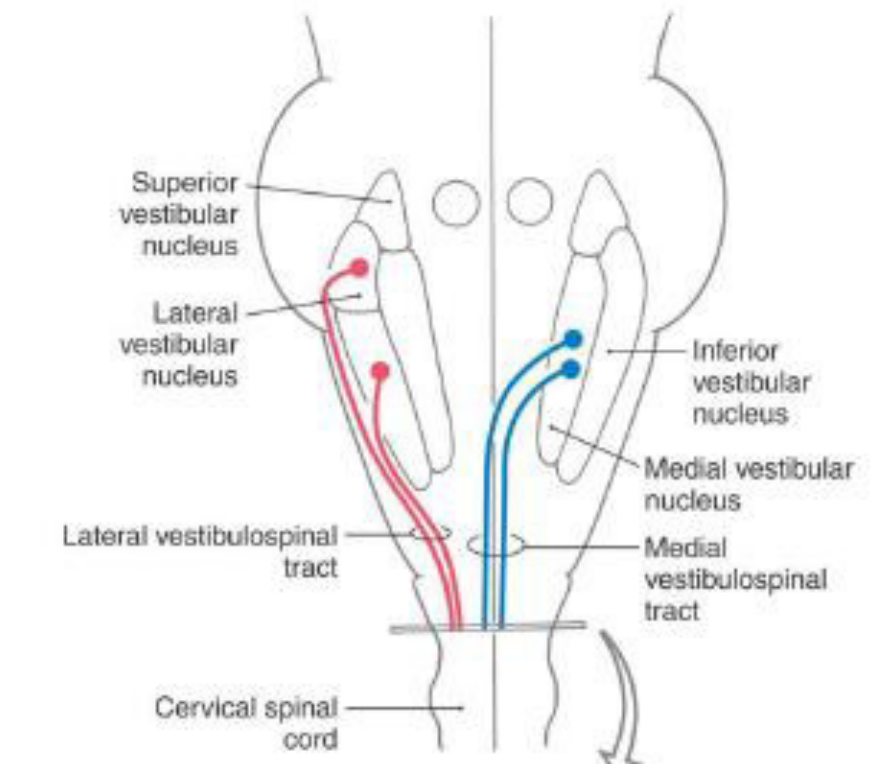


VESTIBULAR PATHWAY

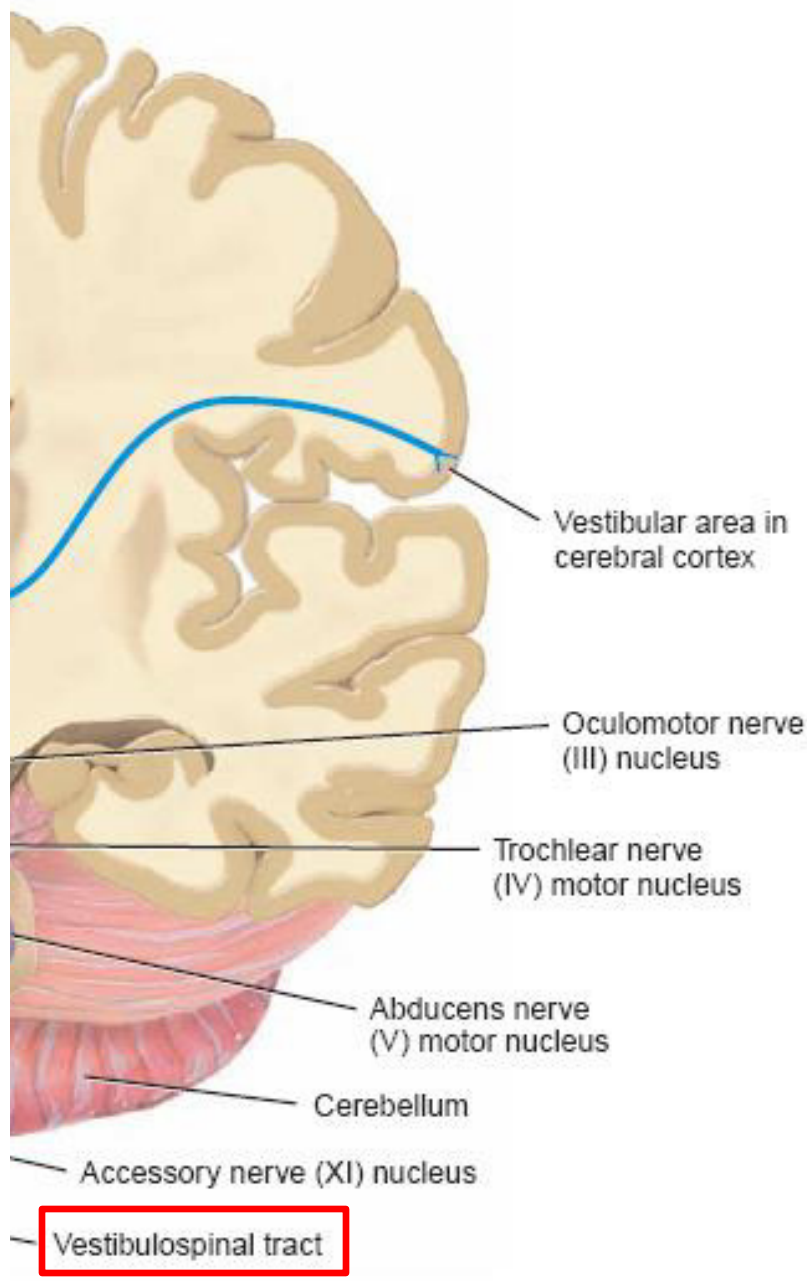


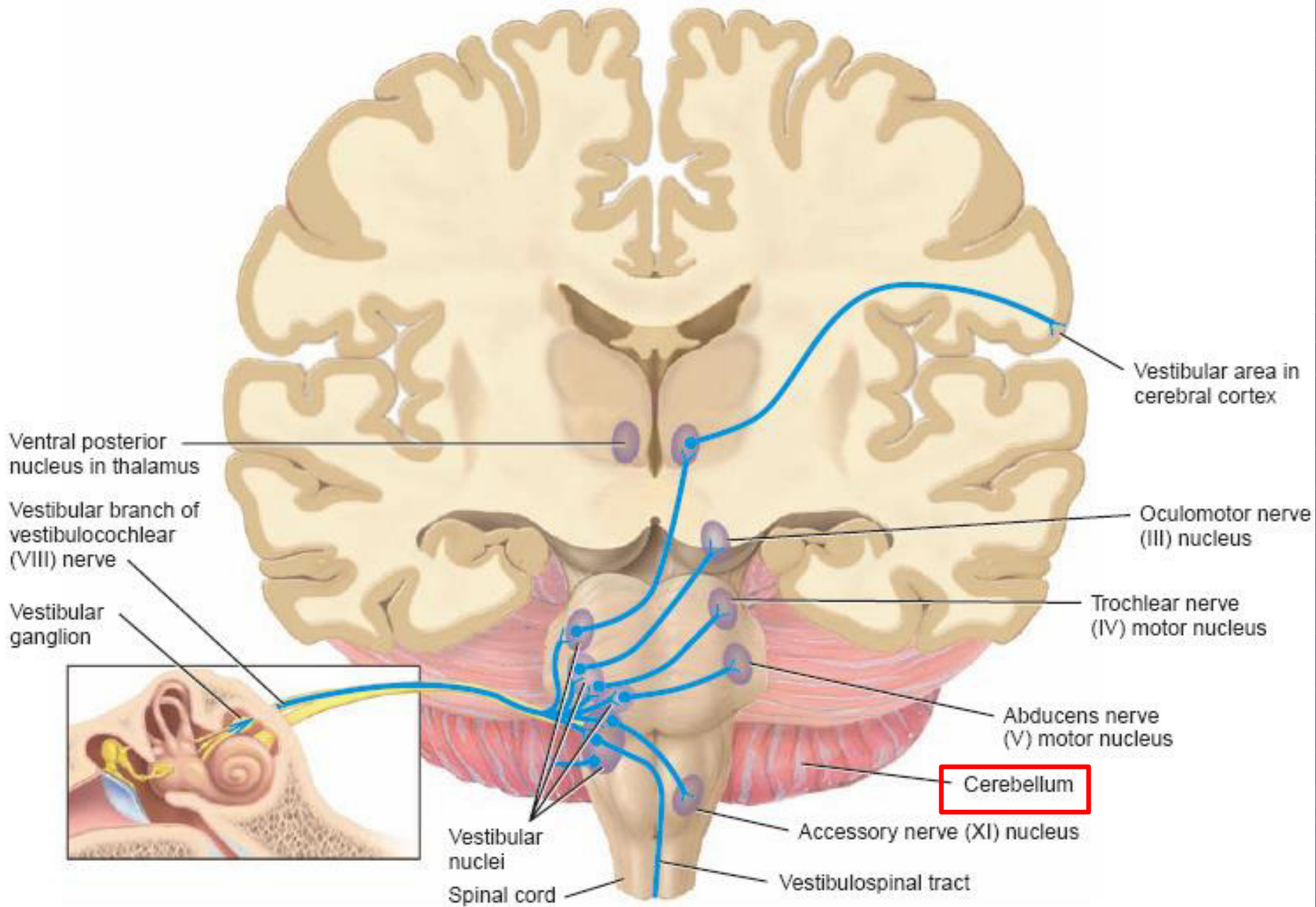


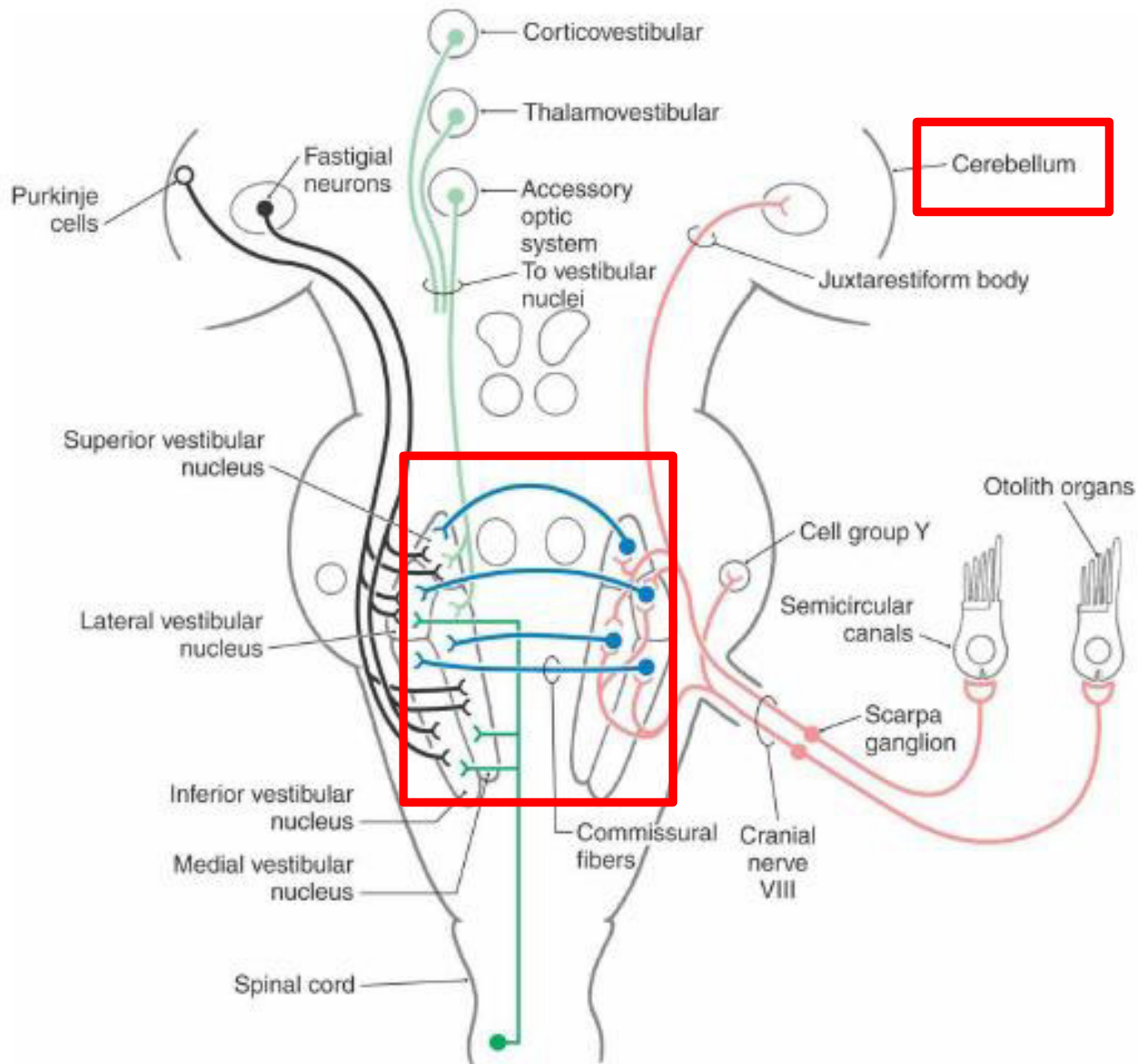


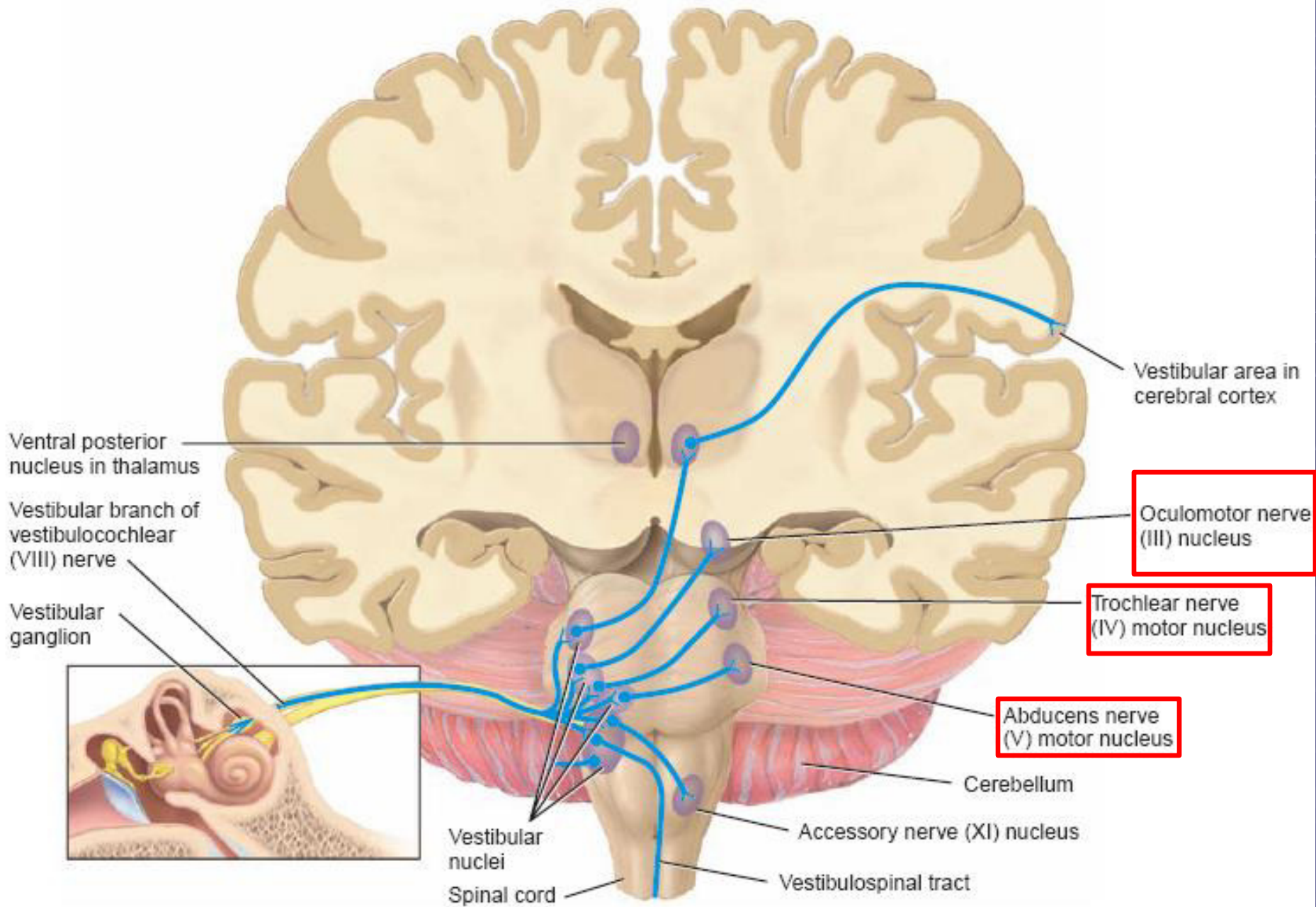


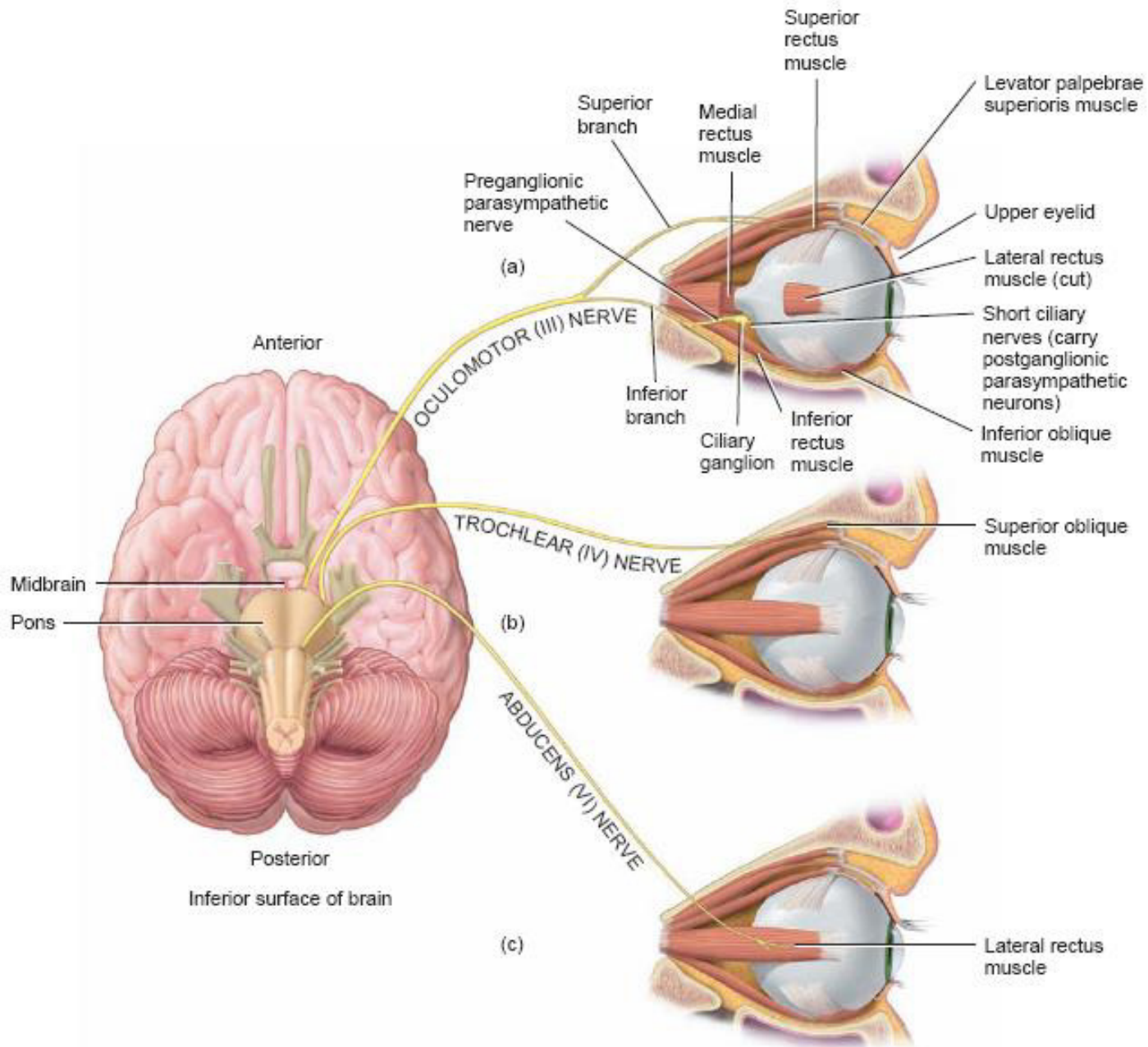
V
n
V
vi
(
V
g

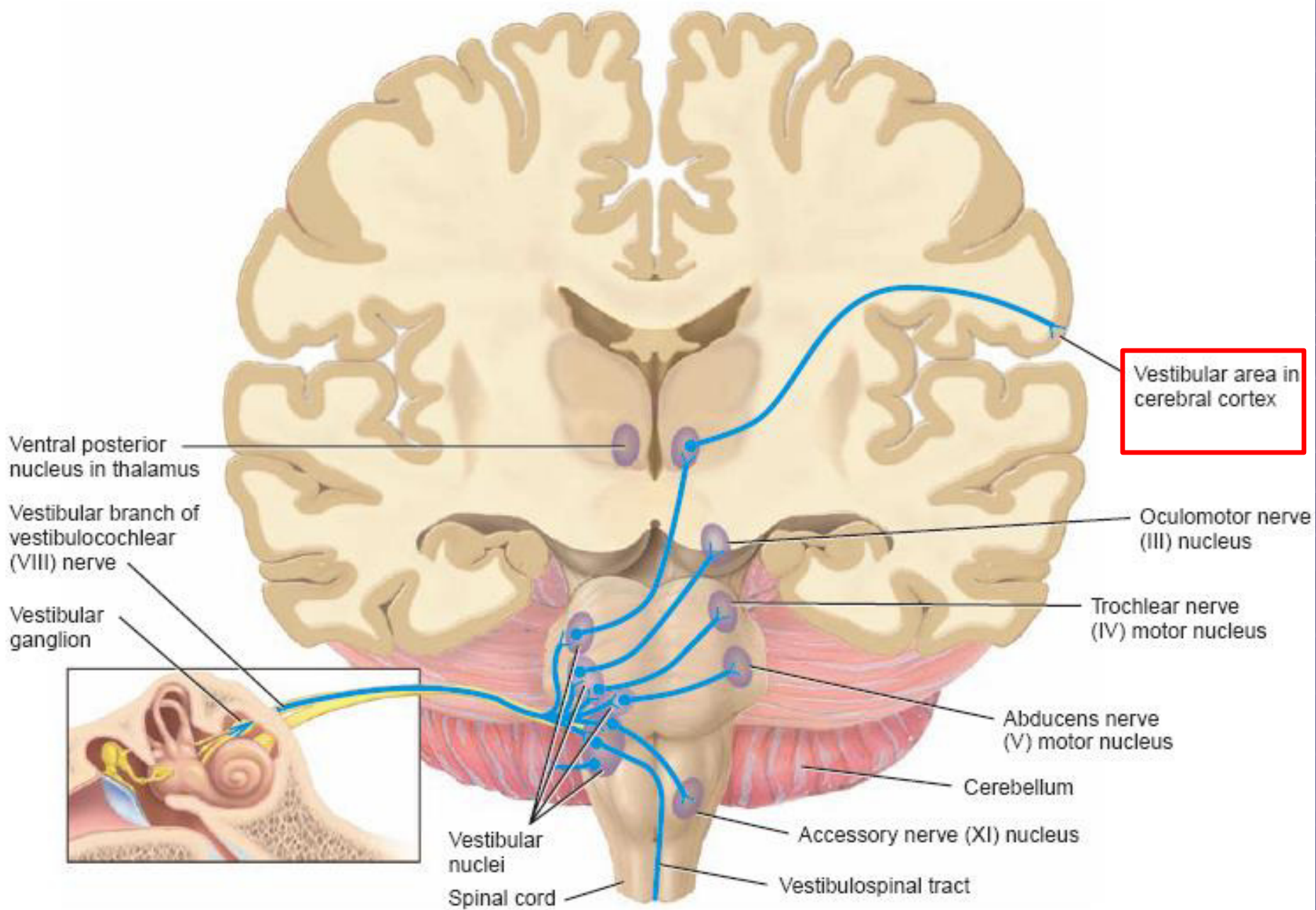


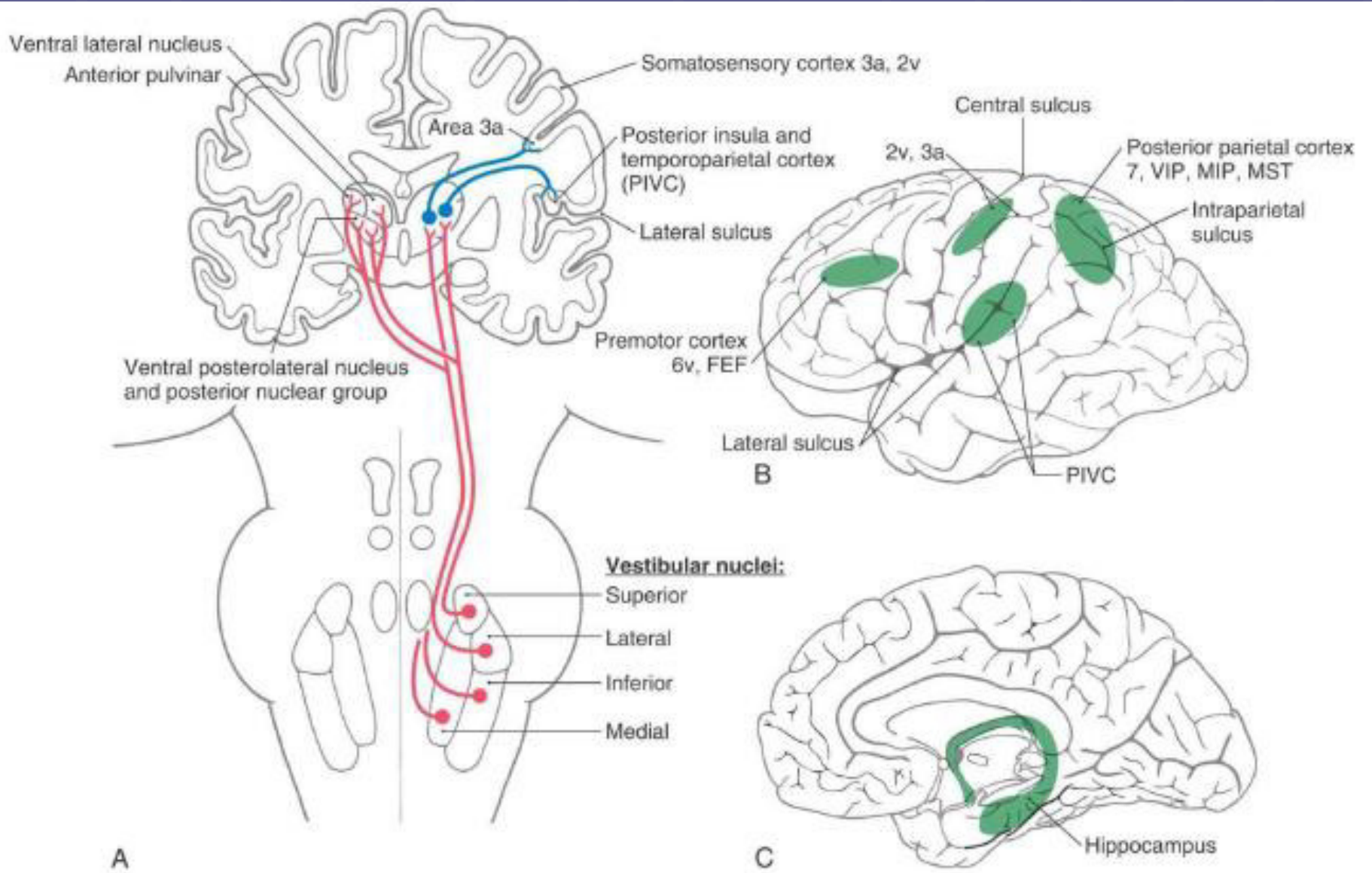






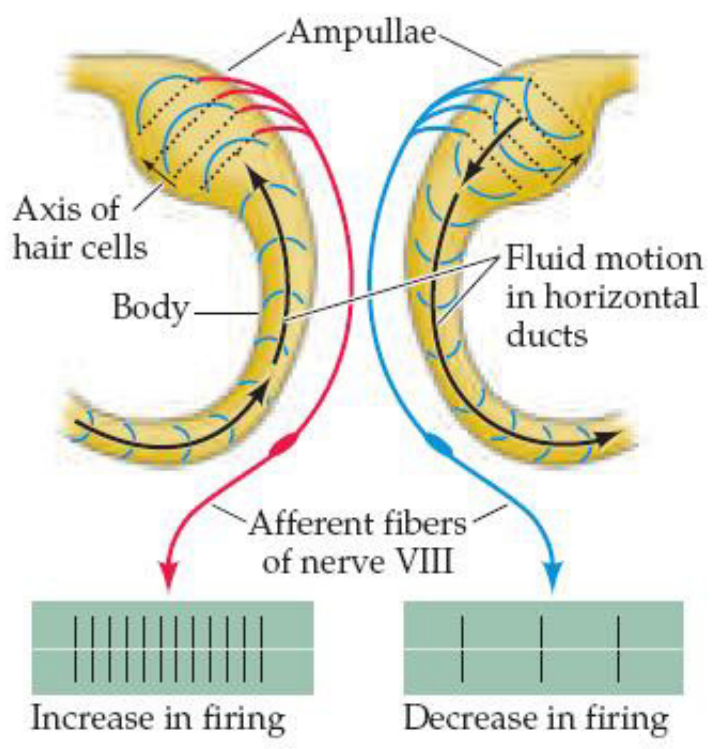
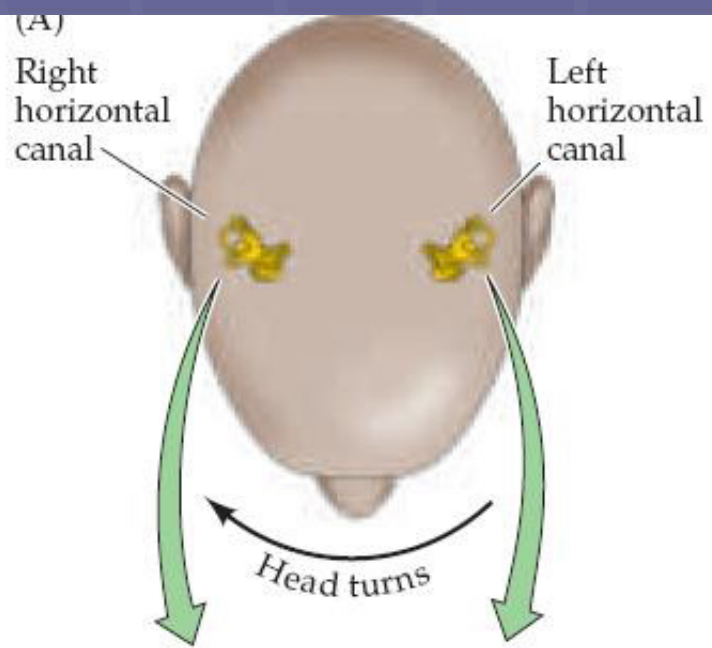


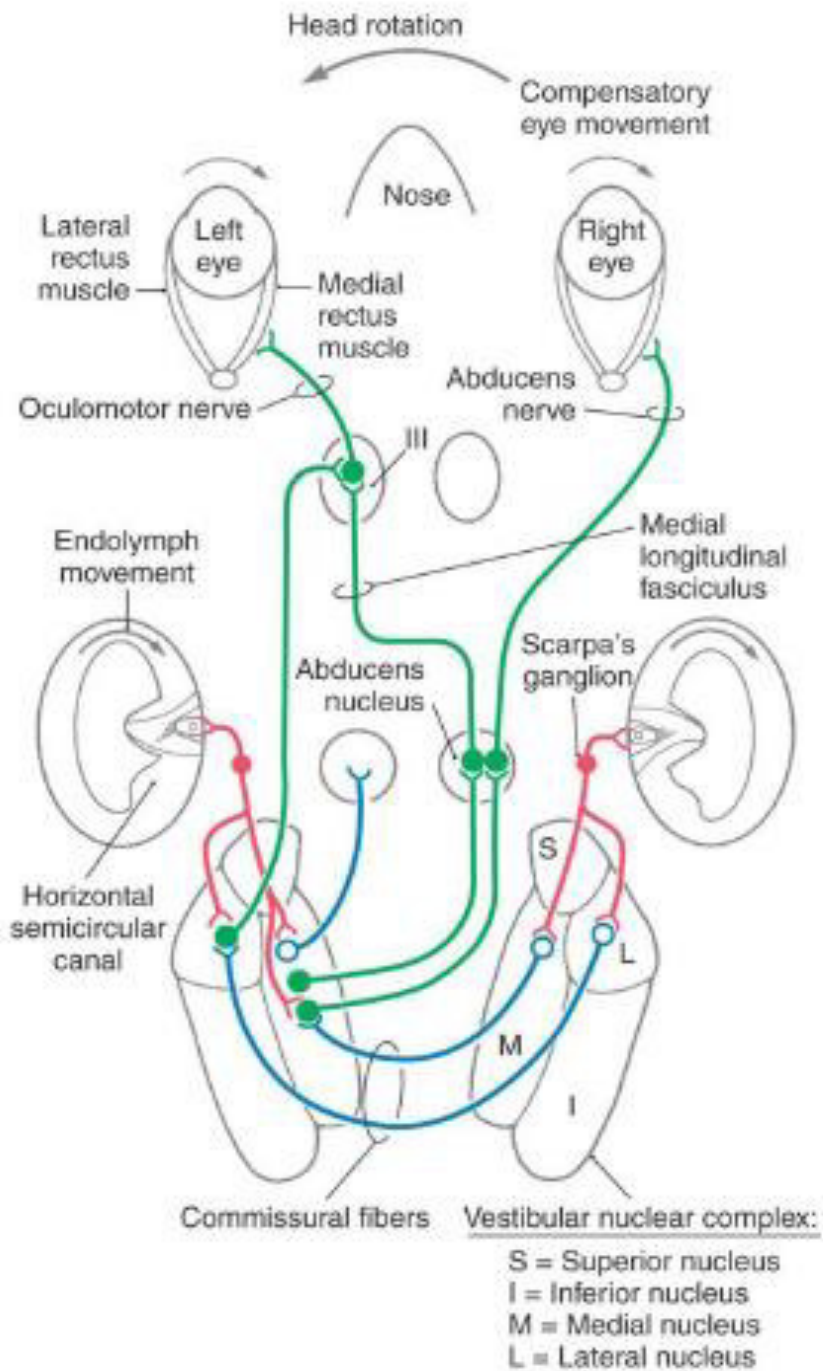




VESTIBULOOCULAR REFLEX

- **Compensatory for head movements**
 - *Rotational Reflex*
 - *Linear Reflex*





VESTIBULOOCULAR REFLEX

- **Compensatory for head movements**
 - *Rotational Reflex*
 - *Linear Reflex*
- *Nystagmus*


Head rotation



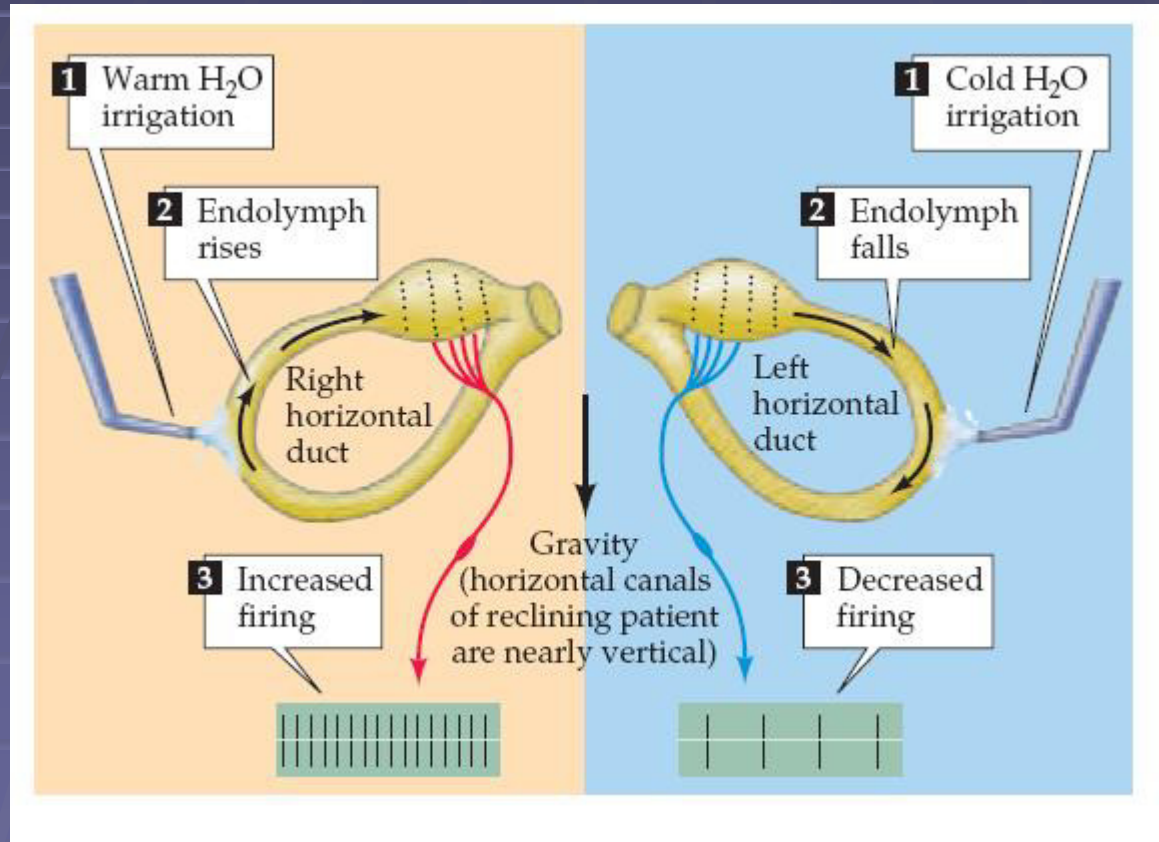
Slow eye movement



Fast eye movement

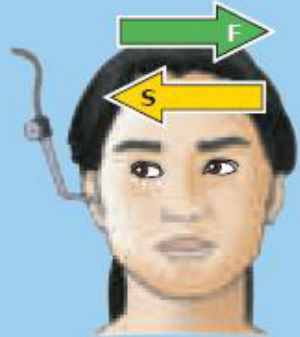

Caloric test

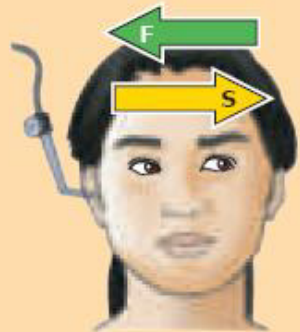

Ocular reflexes in conscious patients

(1) Normal



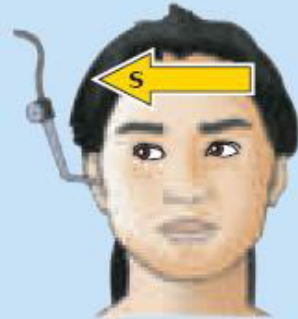Cold H₂O



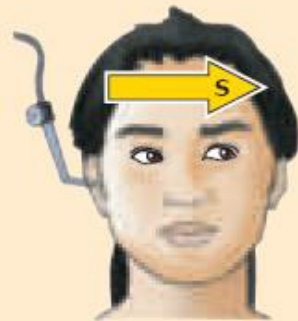Warm H₂O

Ocular reflexes in unconscious patients

(2) Brainstem intact

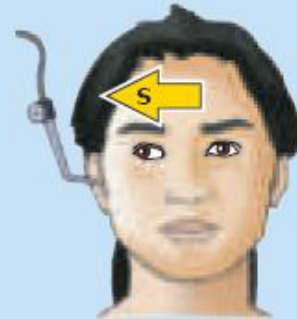


Cold H₂O

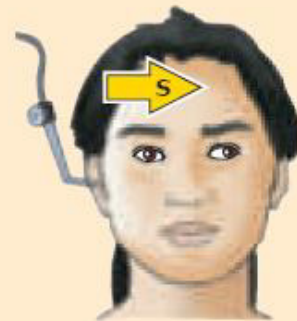

Warm H₂O

(3) MLF lesion (bilateral)

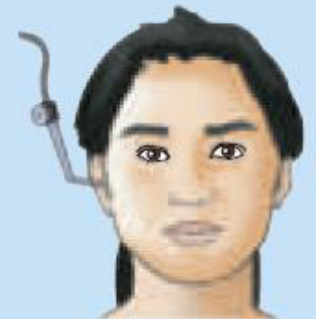

Cold H₂O

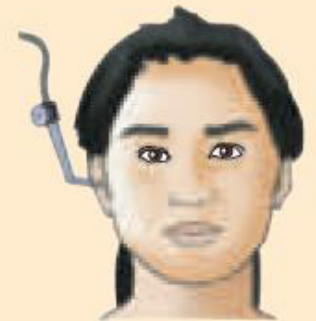

Warm H₂O

(4) Low brainstem lesion



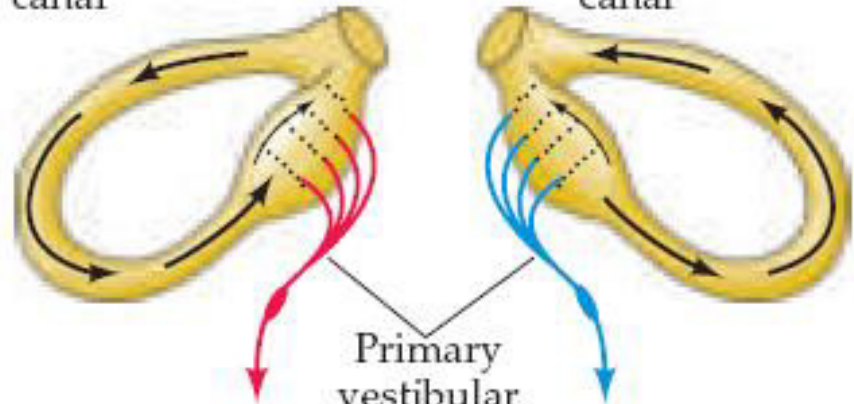
Cold H₂O




Warm H₂O

Right horizontal canal

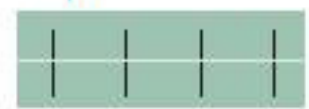
Left horizontal canal



Primary vestibular afferents

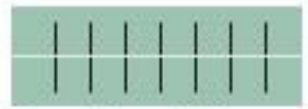

Increased firing




Decreased firing

(2) Spontaneous nystagmus



Baseline firing



No firing

Ménière Disease

Disease results from a disruption of normal endolymph volume

Symptoms include: Severe vertigo
Positional nystagmus (nystagmus when head in a particular position)
Nausea

Affected individuals can also experience-unpredictable attacks of auditory & vestibular symptoms:
Vomiting
Tinnitus (ringing in ears)
Inability to make head movements
Inability to stand passively
Low frequency hearing loss

Treatment: administration of a diuretic (hydrochlorothiazide) & a salt restricted diet

Persistent condition: shunt implantation into swollen endolymphatic sac, or delivery of a vestibulotoxic agents (gentamicin) into perilymph.

DIZZINESS AND VERTIGO

Dizziness is a **nonspecific** term that generally means a spatial disorientation that may or may not involve feelings of movement. Dizziness may be accompanied by nausea or postural instability. A large number of factors may produce a dizzy sensation, and many are not exclusively vestibular in origin.

Vertigo is a specific perception of body motion, often spinning or turning, experienced when no real motion is taking place. Vertigo may be perceived as **subjective** vertigo or as **objective** vertigo. In subjective vertigo, the patient experiences the sensation of spinning while things in the environment are not moving; in objective vertigo, the sensation is one of objects spinning while the patient is not moving. As children, we all learn to produce vertigo by whirling in place as fast as possible and then abruptly stopping. For a few moments, the world seems to be spinning in the opposite direction. Examination of the eyes during this phase will reveal a nystagmus that beats in the direction opposite to the original direction of rotation. **Vertigo can also be elicited optokinetically if the visual surroundings are revolved while the body remains stationary.** Many modern amusement games take advantage of this phenomenon to produce the sensation of motion.

Benign Paroxysmal Positional Vertigo

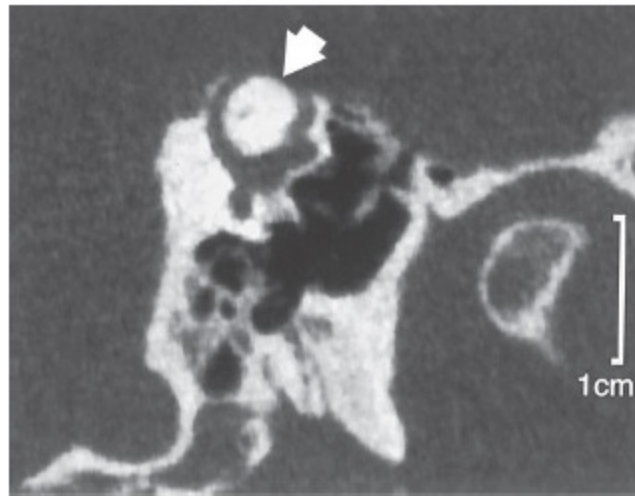
One of the most common vestibular disorders observed clinically is **benign paroxysmal positional vertigo**. This condition is characterized by brief episodes of vertigo that coincide with particular changes in body position. Typically, episodes may be triggered by turning over in bed, getting up in the morning, bending over, or rising from a bent position. The pathophysiologic mechanism of benign positional vertigo is not clearly understood, but posterior canal abnormalities are implicated. One possible explanation is that otoconial crystals from the utricle separate from the otolith membrane and become lodged in the cupula of the posterior canal (a condition called **cupulolithiasis**). The resulting increased density of the cupula produces abnormal cupula deflections when the head changes position relative to gravity.

Vestibular Neuritis

Patients often present with severe vertigo, nausea, and vomiting yet have no accompanying hearing loss or other central nervous system abnormalities. In many of these cases, **vestibular neuritis** is diagnosed and is thought to involve edema of the vestibular nerve (or ganglion). The edema is most commonly believed to be produced through an acute viral infection, such as herpes simplex virus. In fact, some patients report a recent history of upper respiratory tract infection, cold, or influenza. Treatment options include antiemetics, vestibular suppressants, corticosteroids to reduce inflammation, and antiviral agents.

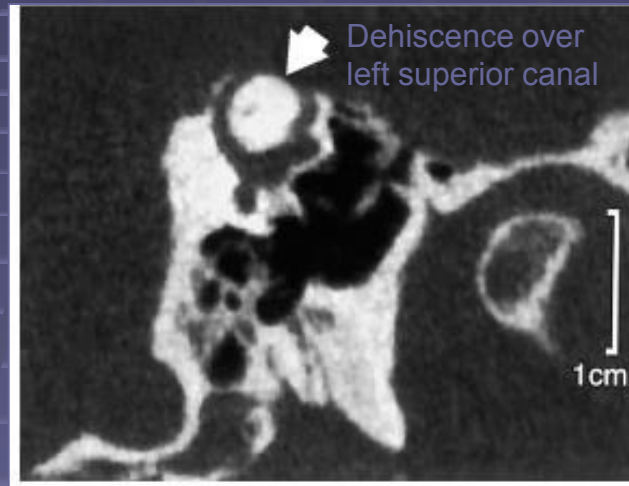Semicircular Canal Dehiscence

On occasion, a condition may develop in which a portion of the temporal bone overlying either the anterior or the posterior semicircular canal thins so much that an opening (dehiscence) is created next to the dura (Fig. 22-5). In affected patients, the canal dehiscence exposes the normally closed bony labyrinth to the extradural space. Symptoms can include **vertigo** and **oscillopsia** (a sense that objects are moving to and fro, oscillating, in the visual fields) in response to loud sounds (the **Tullio phenomenon**) or in response to maneuvers that change middle ear or intracranial pressure. The eye movements evoked by these stimuli (nystagmus) align with the plane of the dehiscent superior canal. Surgical closure of the defect by bone replacement is often performed.



Semicircular Canal Dehiscence (opening)

Temporal bone overlying the anterior or the posterior semicircular canal thins, creating an opening/dehiscence next to the dura.



Text Fig. 22-5

CT scan of the temporal bone projected into the plane of the left superior/anterior canal, in a patient with superior canal dehiscence syndrome.

The dehiscence exposes the bony labyrinth to the extradural space.

Symptoms: vertigo and oscillopsia in response to loud sounds (Tullio Phenomenon), or in response to maneuvers that change middle ear or intracranial pressure.

Nystagmus evoked by these stimuli aligns with the plane of the dehiscent superior canal.

Treatment: Surgical closure of the defect by bone replacement.

Dizziness: non-specific term.
generally means **spatial disorientation**.
may or may not involve feelings of movement.
may be accompanied by nausea or postural instability.
may be caused by factors other than vestibular dysfunction.

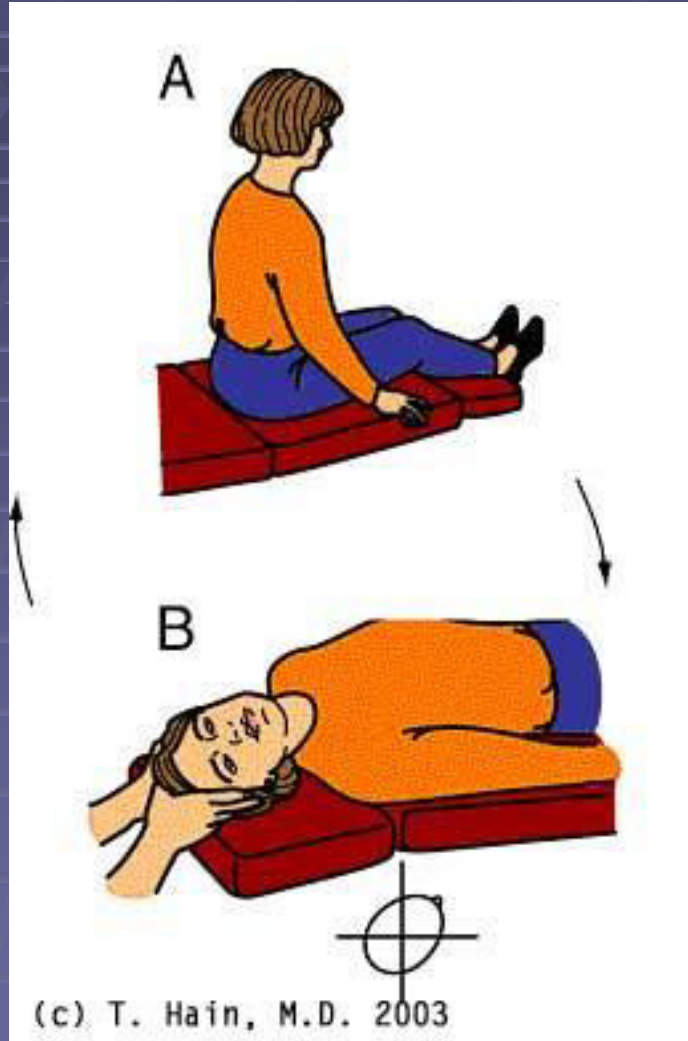
Vertigo: specific term.
perception of body motion.
spinning or turning sensation when no real motion is taking place.

Benign Paroxysmal Positional Vertigo
common clinical disorder.
condition characterized by **brief episodes of vertigo that coincide with particular changes in body position**.
pathophysiology poorly understood.
posterior canal abnormalities are implicated.
otoconia crystals in the utricle may separate from the otolith membrane and become lodged in the cupula, causing abnormal cupula deflections.

Vestibular Neuritis:
severe vertigo, nausea, vomiting
no hearing loss or other CNS abnormalities
possible edema of the vestibular nerve/ganglion.
thought to be produced by acute viral infection.
treated with antiemetics, vestibular suppressants, corticosteroids, & antiviral agents.

Dix-Hallpike test

The definitive diagnostic test for benign paroxysmal positional vertigo



- Patient from sitting to supine position.
- Head turned 45° to one side and extended 20° backward.
- Observe eyes for nystagmus (30 sec.).
- Bring back to a sitting position.
- Small delay, test other side.
- A positive test consists of a burst of nystagmus.
- Posterior canal BPPV (more common) – eyes jump upward.