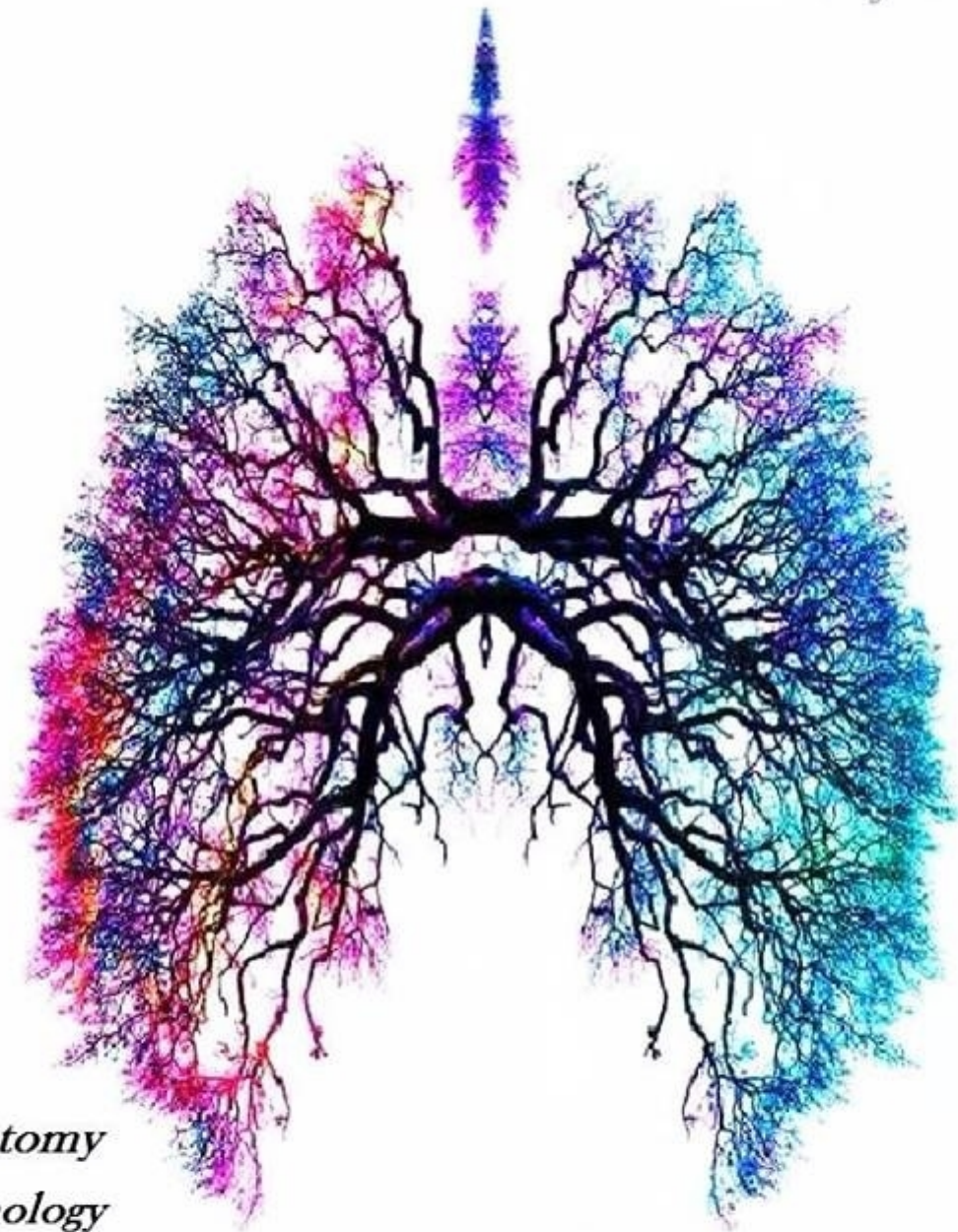


# RESPIRATORY SYSTEM

*Cover by: Aseel Khatib*



- *Anatomy*
- *Pathology*
- *Physiology*
- *Pharmacology*
- *Microbiology*
- *PBL*

*Dr Name: Al Muhtaseb*  
*Lecture # 4 (3- anatomy)*  
*Done By: Alaa Taha Roto*

*Sheet*

*Slide*

*Other*



## The larynx

In the previous lectures , we started talking about the upper respiratory tract; the nose ,nasal cavity ,the nasopharynx , and we have reached the larynx ; which is the last part of the upper respiratory tract.

So what is the larynx ? (الحنجرة)

It is a box of cartilage located in front of the neck . From inside it is lined by mucous membranes , and from the outside we have 9 pieces of cartilage that are linked together by membranes and ligaments , forming a single structure which is the larynx . Moreover , it contains intrinsic muscles and has also extrinsic muscles . There are also vocal cords that are moved by the intrinsic muscles . The only intrinsic muscle that is found on the external surface of the larynx is the cricothyroid muscle.

### Extension :

Above it opens into the laryngo-pharynx . It is Suspended from the hyoid bone above and attached to the trachea below by membranes and ligaments

Extends from the middle of C3 vertebra till the level of the lower border of C6 and Continue as Trachea.

Note : the hyoid bone is not part of the larynx.

### Functions of the larynx :

- 1- **Respiration** : the inlet is always open to allow the passage of air ( the epiglottis is not closing the inlet and the aryepiglottic muscle is relaxed ),and closed just during swallowing.
- 2- **Phonation** : it occurs just during expiration where we have vibration of the vocal cords , there is adduction of the True vocal folds and the air below it will be trapped to build a column of air that presses on the adducted vocal folds , then they will vibrate and the air column is partitioned between the nose , the mouth and the pharynx , so we can say the different letters .
- 3- **Effort closure** ( complete closure ) : we have to cases ;
  - 1) The cough reflex : there is a sudden closure( adduction ) , then a sudden opening (abduction ) of the vocal folds to throw out the foreign object .
  - 2) During lifting a heavy object ; you see that person putting a belt around his abdominal muscle and he can't breathe ( There Is NO respiration ) , after putting that heavy object on the ground , he will release a deep and long breath (expiration) , that occurred because during lifting the vocal cords were adducted , and the air collected below it.
- 4- Swallowing: closure of the inlet by the mechanism mentioned above.

\*\*\*\*\*



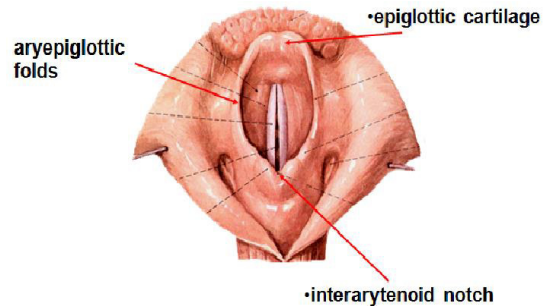
**Inlet of the larynx :**

Imagine you are looking to the larynx from above ( when putting an endotracheal tube for example ), what will you see ?

Anteriorly : the upper free margin of the **epiglottis**

Laterally : the **aryepiglottic fold** ( that contains the aryepiglotticus muscle and cuneiform cartilage , and the mucosa covering it)

Posteriorly : it is in the midline and formed by a mucosal fold that forms a depression (**interarytenoid notch**) between the two corniculate tubercles



In the center , deeply the vocal cords also are seen but they are not our subject now , we are just talking about the inlet

**What is the function of the inlet ?**

From it the air passes all the time , but when you eat , the inlet must close to prevent the food from entering the airway and causing lung aspiration

The question now is how the inlet closes upon swallowing and deglutition ?

As you know that the epiglottis is behind and below the posterior third of the tongue , so when the bolus forms at the posterior part of the tongue and descends from oropharynx to laryngopharynx to esophagus , it forces the epiglottis to descend downwards and backwards and close the inlet , at the same time, the aryepiglotticus muscle contracts to raise the larynx upward. Now the inlet is closed and the bolus can continue its journey toward the esophagus .

We have finished up with the inlet .

\*\*\*\*\*

**The laryngeal cavity :**

It is divided into 3 parts by the true and false vocal folds

- 1) Vestibular part : above the false vocal folds
- 2) Glottic part : between the false and true vocal folds
- 3) Infraglottic part: between the true vocal folds and the outlet of the larynx

Looking to the larynx superiorly , as we said we see the vocal folds ;true and false . Now there is a space between each two vocal folds named Rima , so we have two Rimas , as the following:

- 1- Rima glottidis : the space between the true vocal folds
- 2- Rima vestibuli : the space between the false vocal folds

Now , we said that the false cords are fixed , while the true are movable , but to be mentioned , both rimas can be closed by the movement of the arytenoid cartilages and associated membranes ( the aryepiglottic fold ) , and this is important during swallowing .

\*Remember that the posterior part of rima glottidis could be closed by the **Transverse Arytenoid muscle** ( just the posterior part , and this is not considered Adduction of the vocal cords )

\*\*\*\*\*

**Laryngeal Cartilages :**

As we said that the larynx is a box of cartilages , there are two types of cartilage:

- 1- Single cartilage : i.e one piece
  - ✓ Epiglottis
  - ✓ Thyroid
  - ✓ cricoid
- 2- Paired cartilage : i.e two pieces, one on the right and the other is on the left
  - ✓ Arytenoid
  - ✓ Cuneiform
  - ✓ Corniculate

**Histology Note :** all these cartilages are Hyaline , except the epiglottis , it is elastic cartilage .

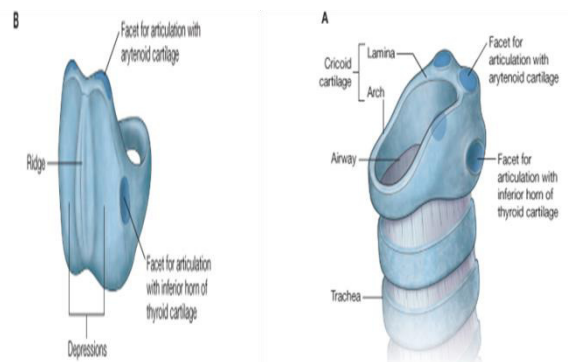
So we will explain them one by one .

Writer's note : I want you to think of each piece of theses cartilages as a bone that has its own processes , tubercles , ridges , facets , joints and other features that serve a specific function, like attachment of muscles for example , but it is a cartilage not a bone.

**Cricoid cartilage :**

It is the lower most piece of cartilage , it looks like a signet ring ; meaning that it forms a *complete* circle that is narrow anteriorly and broad posteriorly.

- 1- Anterior narrow part is called the arch
- 2- Posterior board part is called the lamina



© Elsevier. Drake et al: Gray's Anatomy for Students - www.studentconsult.com © Elsevier. Drake et al: Gray's Anatomy for Students - www.studentconsult.com

Now the lamina has specific features:

- 1- Posteriorly : A ridge- serves as attachment to the esophagus- separating two depressions

What is the function of these depression ?

Origin for a muscle called **Porterior Cricoarytenoid** muscle that is inserted in the arytenoid as the name implies , and it abducts the vocal cords



- 2- **Laterally** : Two lateral facets to articulate with the inferior horn of the thyroid cartilage . ( as we will see the thyroid cartilage has a superior horn and an inferior horn , the inferior one articulates with the lateral facet of the lamina of cricoids )
- 3- **Superiorly** : two superior facets to articulate with the two arytenoid cartilages
- 4- **Inferiorly** : there is a ligament connecting the lower border of the cricoids to the first cartilage of trachea , and it is called cricotracheal ligament.

\*\*\*\*\*

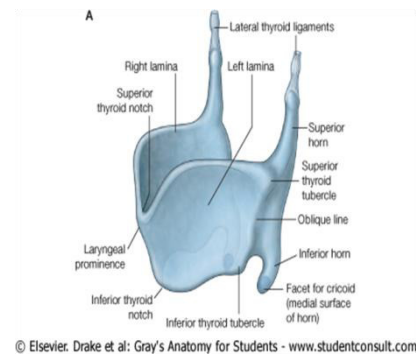
**Thyroid cartilage :**

It is the biggest laryngeal cartilage , single and it is open posteriorly ( deficient posteriorly , unlike the cricoids cartilage) . It has the following features:

- 1- **Two laminae** : they converge from both sides to meet anteriorly and form the laryngeal prominence , or what so called Adam's Apple.
- 2- **Two horns** : they are found on the lateral sides :

\***Superior horn** : is connected via a ligament called **thyrohyoid ligament** to the greater horn of hyoid bone

\***inferior horn** : has a facet that articulates with the lateral facet of the lamina of cricoid.

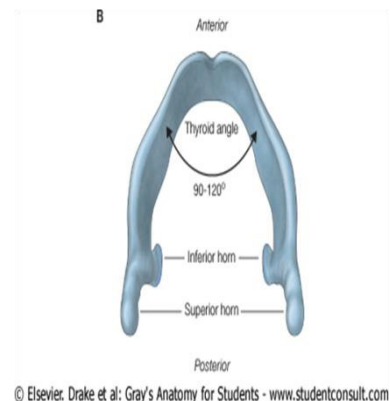


**#Notes about the lamina of thyroid cartilage:**

- 1- The meeting of the two laminae anteriorly forms an angle called the thyroid angle .

**What is the significance of the thyroid angle ?**

- ✓ It is different in both sexes at puberty :
    - In males it is acute ( near 90° degrees ), so males have longer vocal cords and this is the effect of testosterone
    - In females it is obtuse ( near 120° degrees ) , so females have shorter vocal cords due to estrogen and progesterone.
  - ✓ It is for the attachment of the true vocal cords
- 2- If you look to the lamina laterally , you can see two tubercles and there is an oblique line( a ridge ) connecting them, so you have :



- ✓ Superior thyroid tubercle
- ✓ Inferior thyroid tubercle
- ✓ Oblique line



### What is the significance of the oblique line ?

Attachment for two **infrahyoid** muscles ( they are extrinsic laryngeal muscle) :

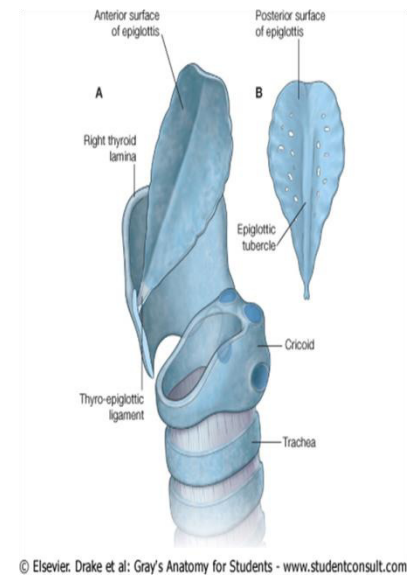
- 1- Insertion for Sternothyroid
- 2- Origin for Thyrohyoid
- 3- Inferior constrictor muscles

### Epiglottis :

It is an Elastic piece of cartilage( leaf shaped )that forms the anterior wall of the inlet of the larynx .

#### \*Attachments :

- ✓ Anterio – inferiorly : It has an fixed margin that is attached to the interior surface of the laryngeal prominence of Thyroid cartilage by **Thyro-Epiglottic ligament** .
- ✓ Anterio-superiorly : It is attached from the midline of its anterior surface to the hyoid bone by **Hyo-Epiglottic ligament** .
- ✓ Lateral sides : we have
  - 1- Attachment of the *quadrangular membrane* that links these lateral sides of the epiglottis to the Arytenoid & corniculate cartilages below.
  - 2- Insertion for the aryepiglotticus muscle
- ✓ Superio- posteriorly : Here is The upper free margin of the epiglottis that is behind and below the posterior third of the tongue .( important in the closure of the laryngeal inlet during swallowing )



© Elsevier. Drake et al: Gray's Anatomy for Students - www.studentconsult.com

### #Histology note :

If you look to the epiglottis , you will see that it has two surfaces :

- 1- Anterior surface : covered by oral epithelium ( stratified squamous non keratinized epithelium) . why it is not respiratory ? because this surface is subjected to friction by the bolus descending on it going to the pharynx
- 2- Posterior surface : covered by respiratory epithelium .It is rough and has a tubercle called epiglottis tubercle and a ridge

We finished with the single laryngeal cartilages , and we will continue now with the paired .

\*\*\*\*\*

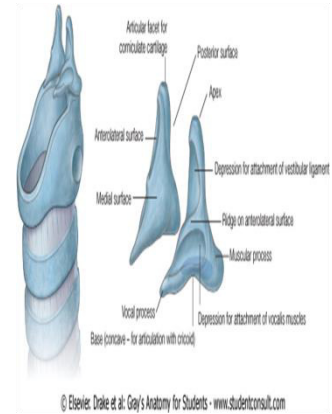
### Arytenoid cartilage:

Paired , pyramidal or triangular in shape and has the following features :

- 1- Apex : Articulating with the corniculate cartilage .
- 2- Base :



- ✓ Inferiorly : Articulates with the superior facets of lamina of cricoids
- ✓ Anteriorly : has a **vocal process** that is attached to the true vocal cords
- ✓ Posteriorly : **muscular process** , which is the site of Insertion of posterior and lateral cricoarytenoid muscles.



Remember we said before that the

Origin of **Posterior cricoarytenoid** muscle is the *posterior two depressions of lamina of cricoid* .

Posterior cricoarytenoid: Abducts the vocal cords

Lateral cricoarytenoid :Adducts the vocal cords

- 3- Medial surface : smooth surface
- 4- Lateral surface : it has a ridge separating two depressions :
  - ✓ The upper depression : attachment of a ligament called vestibular ligament ( which is part of the false vocal cords)
  - ✓ The lower depression : attachment of a muscle called vocalis muscle.

Notice that the **lower depression** is *above* the **vocal process** of arytenoid cartilage , the *lower depression* attaches to the *Vocalis muscle* ( which is a content of the true vocal cords ) , and the *vocal process* attaches to the *True vocal cords* which contain the vocalis muscle :p , each has its own attachment.

So what have we learned so far about the vocal folds ?

All are attached to the Arytenoid cartilage ;

- 1- False vocal cords : upper depression
- 2- Vocalis muscle : lower depression
- 3- True vocal cords : vocal process

Note : considering vocalis muscle

-Action: Relaxes vocal cords, opposite the action of cricothyroid which tenses them

-Origin & insertion: From the Inner surface of thyroid cartilage to the lower depression of Arytenoid cartilage

Nerve supply : Recurrent laryngeal nerve

**Corniculate Cartilage :**

Paired , conical , has a base that articulates with the apex of the Arytenoid cartilage.

**Cuneiform Cartilage :**

Paired , it doesn't articulate with anything , rather , it is suspended in the Ary-epiglottic fold to *strengthen it* during the contraction of the aryepiglottic muscle during closure of the inlet upon swallowing .

Finished with the cartilages ^\_\_^

\*\*\*\*\*

**Ligaments and membranes :**



As we said that the larynx is a box of pieces of cartilage that are connected via membranes and ligaments . Also ,theses membranes and ligaments connect the larynx to the trachea below and to the hyoid bone above

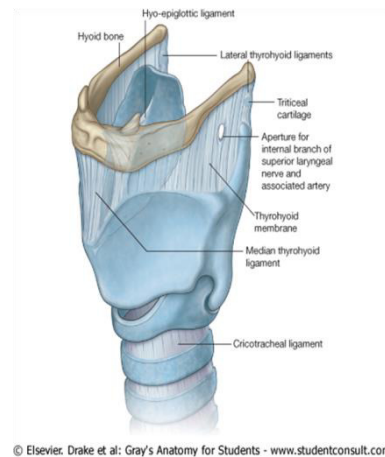
What it the difference between the membrane and the ligament?

Both are connective tissues ( fibro-elastic tissue) , but the ligament is a thickening of the membrane.

This thickening (ligament ) is seen in the midline and on both sides laterally , and the rest is the membrane( i.e. between the sides and midline is a membrane ).

The ligaments are of Two types :

- 1- Extrinsic ligaments : connect the larynx to the trachea below and to the hyoid bone above ; these are :
  - ✓ Thyrohyoid
  - ✓ Hyo-epiglottic
  - ✓ Crico-tracheal
- 2- Intrinsic ligaments : connect the larynx' cartilages ; and these are :
  - ✓ Crico-thyroid membrane or as clinicians call "Conus Elasticus"
  - ✓ Quadrangular membrane

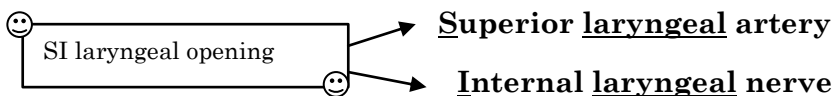
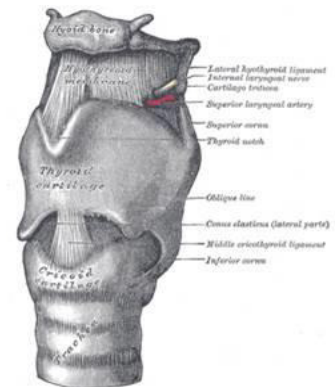


© Elsevier Drake et al: Gray's Anatomy for Students - www.studentconsult.com

#Notes about each membrane :

#### 1- Thyro-Hyoid membrane :

- ✓ It extends from the SUPERIOR border of the thyroid cartilage and its two superior horns toward the hyoid bone , and attaches to its the SUPERIOR border of the body and greater horns. ( from superior to superior )
- ✓ This membrane thickens in the midline to form the Median Thyro-Hyoid ligament , and on the lateral sides to form the Lateral Thyro-Hyoid ligament , which may contain a piece of cartilage called ( *triticeal cartilage*).
- ✓ Last thing about this membrane , it is pierced on its lateral sides by a an Artery and a Nerve , and I call it the SI laryngeal opening :p , so what passes through it ?





- 2- Hyo-epiglottic ligament : from the midline of the anterior surface of the epiglottis to the Body of hyoid bone
- 3- Crico-tracheal : lower border of cricoids to the upper border of the first tracheal cartilage ring

End of extrinsic laryngeal ligaments ^ \_\_ ^

\*\*\*\*\*

**Intrinsic laryngeal ligaments :**

They connect the laryngeal cartilages together and give the framework of the laryngeal cavity ; these are :

- 1- Conus Elasticus/ Crico-thyroid membrane :

Extends from the cricoid cartilage to the thyroid cartilage , thickened in two locations

- 1- In the **midline** to form the **Median Crico-Thyroid Ligament**.
- 2- In its **Upper Free Margin** inside the cavity of the thyroid cartilage to form the **vocal ligaments** ( which are True vocal cords ).

These vocal ligaments are attached :

- Anteriorly to the thyroid Angle.
- Posteriorly to the vocal Process of the base of the 2 Arytenoid cartilages.

End of story : Conus Elasticus or the Crico-thyroid membrane gives rise to the true vocal cords .

- 2- Quadrangular membrane:

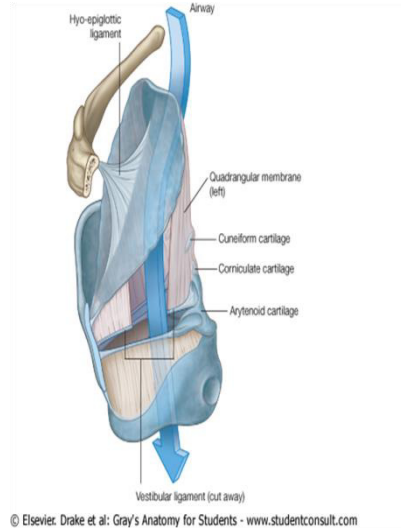
- Attachment : from the lateral sides of the epiglottis to the antero-lateral surface of Arytenoid and the corniculate cartilages.
- Importance : It has two free margins; superior and inferior . The Inferior thickens to give rise to the vestibular ligaments , which are the False vocal cords.

False vocal cords attachment :

- ✓ Anteriorly : to the Thyroid angle above the site of attachment of the true cords .
- ✓ Posteriorly: upper depression of Arytenoid Cartilages

End of story : the Quadrangular membrane gives rise to the false vocal cords.

#Relational note : \* The false vocal folds are Above & Lateral to the True cords



© Elsevier, Drake et al: Gray's Anatomy for Students - www.studentconsult.com



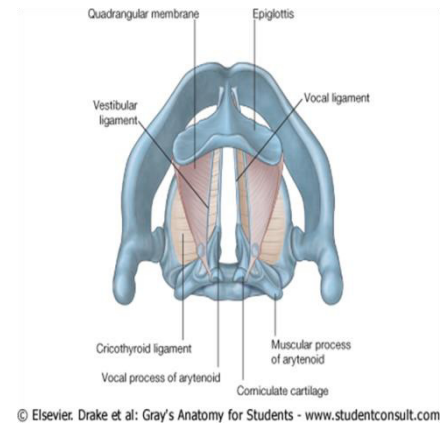
\* There is a Ventricle separating them and the space between the vestibular ligaments and the thyroid cartilage is called Saccul, where there is a lot of seromucous glands for lubrication of the vocal cords .

#Histology Note :

First : the vocal cord is a ligament ( connective tissue ) covered by mucosa .

1- **True vocal cords :**

- The epithelium covering the true vocal folds is stratified squamous non keratinized , because they are liable to injury when someone uses them for a long time singing or screaming , so they can undergo mitosis & regeneration , so if you lose your voice , it will return back to normal within two to three days .
- They have a muscle called vocalis muscle , which is not found in the False cords.
- There is no sub-mucosa in the true vocal cords , so they are protected from developing edema , as if they were prone to edema , they will be adducted closing the airway leading to suffocation and death
- There is no blood vessels , that's why the cords are white , and they obtain the nutrition by diffusion .



2- **False cords :**

- The epithelium covering them is Respiratory epithelium
- Vascularized ( they are red in color)
- They don't move as they have no muscles moving them like the true ones.
- The submucosa contains seromucous glands that secrete seromucous fluid , and this fluid will lubricate the false cords as well as the true vocal cords , remember that the false are above the true ( it is like a shower for them ;p )

\*\*\*\*\*

Joints of the larynx :

They are synovial joints ( have a synovial cavity and allow a rotation movement )

They are :

- 1- Crico-thyroid : between the inferior horn of the thyroid cartilage and the lateral facets of the lamina of cricoid
- 2- Crico-arytenoid : between the superior facets of cricoid and bases of arytenoid .

What is the significance of these joints ?

As we have already learned that each muscle must act on a joint to move a bone , here the muscles will contract acting on a joint and moving cartilages not bones ,So ?



- 1- In the case of **Crico-thyroid joint** , the muscle is the **Crico-thyroid muscle** ( origin is cricoid and insertion is thyroid ) , and the cartilage the muscle is working on to move is the **thyroid cartilage**, we will pull the insertion toward the origin , so the action is **moving the thyroid cartilage forwards and rotating it downwards** , or in other words , **tensing the vocal folds causing high pitch voice** . The last important thing to mention that this muscle has two heads ( oblique & straight ) , and it is the only intrinsic muscle that is supplied by the **External laryngeal nerve** branch of superior laryngeal nerve , which is a branch of vagus.

So what is the purpose behind moving the thyroid cartilage downward and forward ?

This will lengthen and tense the vocal cords , causing high pitch of the voice . That's why the crico-thyroid muscle is well developed in females than males , so females have high pitch voice because the tense is high , but remember the vocal cords are longer in males , the idea here is the tension created in the cord by lengthening it , not caused by the original length of the cord.

- 2- In case of the Crico-arytenoid joint , we have the adductors and the abductors of the vocal cords , these muscles originate from the cricoid and inserted in the muscular process of Arytenoid, so the contraction of the muscles will rotate the muscular processes posteriorly ( adduction or abducting them ) , and with them the vocal processes anteriorly will move also (and with them the vocal cords move) . These are supplied by the **Recurrent laryngeal nerve** , branch from vagal . So, let's mention these muscles :

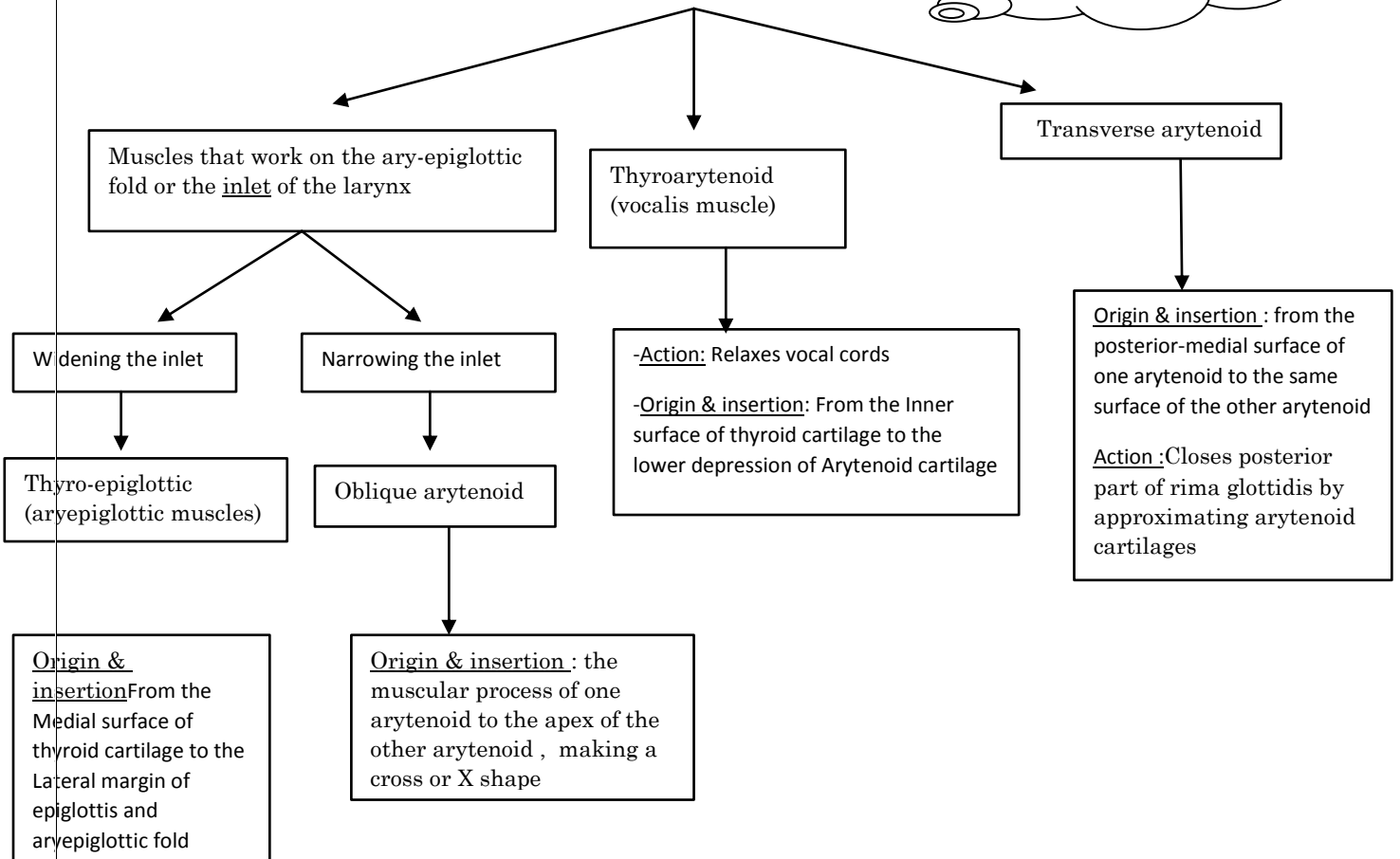
- ✓ Posterior crico-arytenoid:
  - \* Action : Abducts the vocal cords
  - \* Origin: from the posterior 2 depressions of the lamina of cricoid
- ✓ Lateral crico-arytenoid :
  - \* Action: Adducts the vocal cords
  - \* Origin: from the upper border of lamina of cricoid

And both are inserted in muscular process of Arytenoid



**Other intrinsic muscles of the larynx:**

Nerve supply to all these muscles is : **Recurrent laryngeal nerve**



**Extrinsic muscles of the larynx :** not important , just know their names and that they move the larynx as a whole organ :

Infrahyoid muscles : depresses the larynx

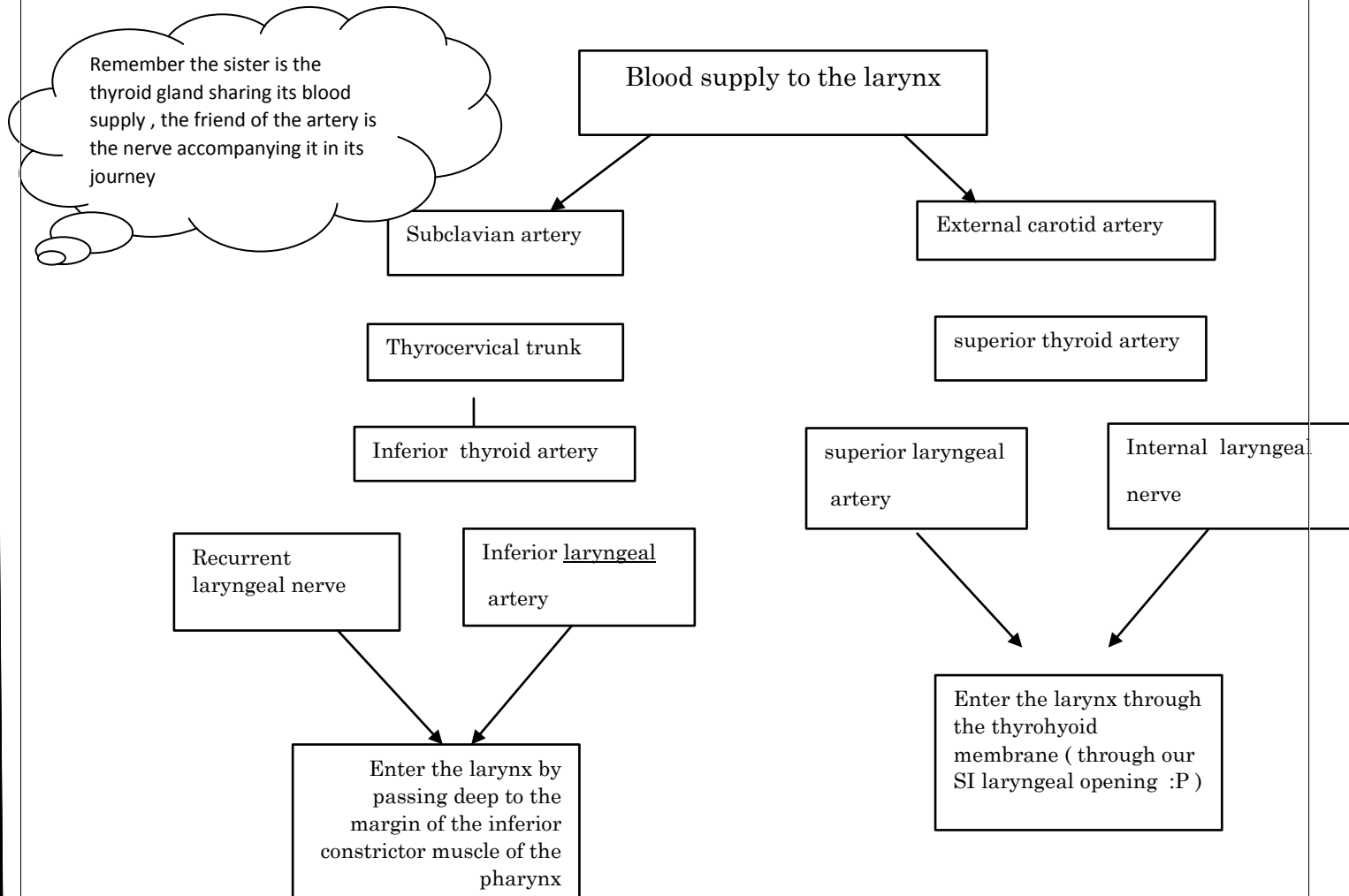
Suprahyoid muscles: elevates the larynx

**Blood supply to the larynx :**

Inferior and superior laryngeal arteries are the blood supply to the larynx. You have to understand the idea of the close relation between the larynx and the thyroid gland ( i.e. the blood supply to the larynx is coming from the arteries supplying the thyroid gland ) .Now our mission is to trace their origin and their entrance to the larynx . Also , we have to be careful about their friends , which



are the nerves accompanying them along their course . This friendship is really important clinically as when we cut the arteries , we could harm the nerves and harm the structures supplied by these nerves .



### Veins of the larynx :

The larynx drains into the superior and inferior laryngeal veins

- 1- Superior laryngeal vein → superior thyroid → internal jugular
- 2- Inferior laryngeal vein → inferior thyroid → the right and left inferior thyroid veins make one vein that goes to the left brachiocephalic vein .

### Lymphatics :

Here we divide the larynx according to the lymphatics into two regions :

- 1- **Above the vocal folds** : follow the superior laryngeal artery and terminate in *Deep cervical nodes*
- 2- **Below the vocal folds** :





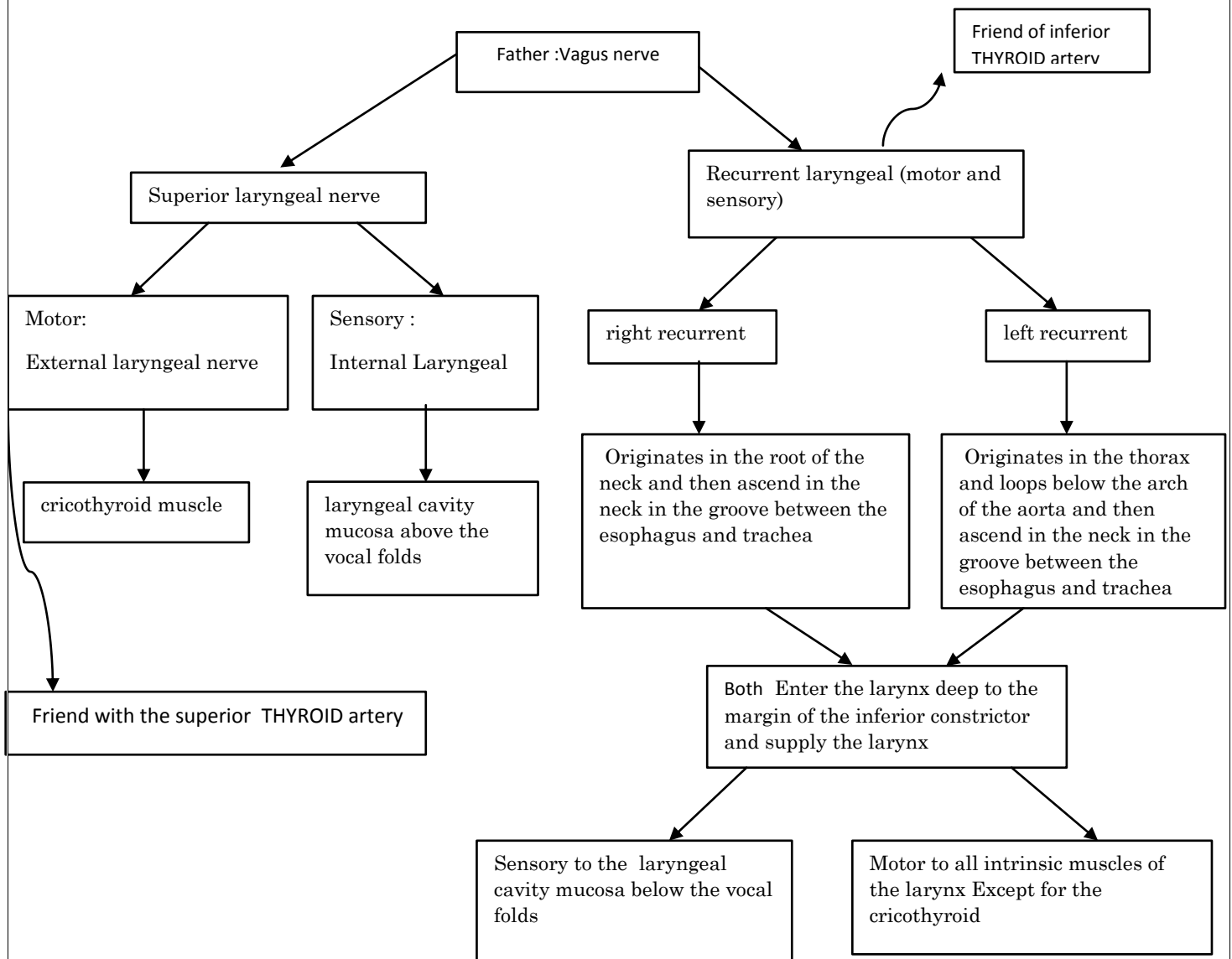
To the paratracheal lymph nodes .

**Nerve supply :**

We have the *Internal laryngeal nerve* , *External laryngeal nerve* and the *Recurrent laryngeal nerve* . Same story of the arteries , we have to trace their course ; here we have a father not a sister , which is the Vagus nerve ,and the friends are the arteries mentioned above .

Another point to understand , why do we need these nerves?

To supply the *intrinsic muscles of the larynx* (motor ) , as well as *sensory* to its mucous membranes . Put in mind that the laryngeal cavity is divided - according to the nerve supply- in to two halves : (Above the vocal cords & Below the vocal cords).



**Relation of the larynx :**

1) On each side : Carotid sheath (contents), and lateral lobe of the thyroid gland



2) Posterior: Pharynx and the right recurrent laryngeal nerve

3) Anterior: Skin, fascia and its contents, 4 infra-hyoid muscles

\*\*\*\*\*

### Clinical notes:

Injury to the nerves of the larynx :

Thyroidectomy : when there is a tumor and we want to remove it , first thing to do is the ligation of the blood supply on both sides and between them we have a cut.

So what are the nerve in danger ?

1- The external laryngeal nerve when we cut the superior thyroid artery. Here the tensor of the vocal cords is lost( cricothyroid muscle ) and there will be:

- \* Weakness of voice : if one nerve is cut
- \* Hoarseness of voice : if the two nerves are cut

2- Recurrent laryngeal nerve : related to the inferior thyroid artery .

We have 4 cases :

- Unilateral : we lose one nerve
- Bilateral : we lose both nerves
- Complete : we lose abductors and adductors
- Partial : we lose the abductors

When describing the consequences , we have to consider the speech changes & the respiration changes ( which are the most important.)

To understand the effect on respiration ; you have to know that the fibers of the recurrent laryngeal nerve that supply the *abductors are superficial* , while the fibers supplying the *adductors are deep*. So when the cut is partial , only the superficial branches are lost , so we lose the abductors of the vocal cords.

To understand the effect on speech , you have to know that one intact vocal cord can compensate the other.

| case                        | Description  | voice                       | respiration          |
|-----------------------------|--|-----------------------------|----------------------|
| Unilateral complete section | One vocal fold (on the affected side) in the position midway between abducted and adducted | Speech not greatly affected | Not greatly affected |
| Bilateral Complete section  | Both vocal folds in position midway between abducted and adducted                          | speech is lost              | difficult            |
| Unilateral partial section  | greater degree of paralysis of the abductor muscles than of the adductor .                 | hoarseness                  | Not greatly affected |



|                           |  |      |                  |
|---------------------------|--|------|------------------|
|                           |  |      |                  |
| Bilateral partial section | Adduction of the vocal cords and closure of the airway | lost | lost/suffocation |

:

Now : the most dangerous case is the Partial Bilateral cut , here we lose the abductors , so the vocal cords are adducted and the airway is closed completely ....Emergency , the brain can't withstand hypoxia , so what to do ?

### Tracheostomy

Tracheostomy : opening an aperture in the trachea to allow the air to pass and the lungs to inflate . we have two types :

- 1) Low / suprasternal : we open in the *suprasternal region* at the 5<sup>th</sup> or the 7<sup>th</sup> tracheal cartilage , or through the median cricothyroid ligament. This is done in emergency situations , when the person's airway is obstructed and we want to create a passage of air to save him , especially his brain that can't withstand without O<sub>2</sub> more than 5 minutes. By creating this passage, the lungs can easily inflate.
- 2) High : during operations , if you mistakenly partially cut the recurrent laryngeal nerve and there was adduction of the vocal cords , the air can't pass , but because it is an operation there is already an endotracheal tube between the vocal cords , but after the operation , how will the patient breathe ?

The surgeon will solve this problem by opening an aperture above or below the isthmus of thyroid gland ( the isthmus covers the 2<sup>th</sup> ,3<sup>th</sup> ,4<sup>th</sup> tracheal cartilages ) ,so the opening will be :

- 1- Above the isthmus: between the 1<sup>th</sup> and the 2<sup>th</sup> tracheal cartilages.
- 2- Below the isthmus: between the 4<sup>th</sup> and 5<sup>th</sup> tracheal cartilages.

النهاية والحمد لله ☺

ما تتسوني من صالح دعائكم و موفقين جميعا ، و أسفة جدا عالشييت المحشية ☹

إهداء إلى : الألماسة بشرى المعاقبة ، الأميرة رنا شحروري ، الوردتين هديل أبوصاح و يارا الكايد ، الياسمينية هدى أبو الشامات ، الجميلة إسراء أبو هنية ، والرفيقة هند المحتسب.  
إهداء خاص إلى شعبة واحد ☺

