

Radiology

Brain CT scan

- Whenever you read a CT scan, make sure to comment on the following:
 - Midline shift:
 - Here, we look at the falxcerebri (a thin hyperdense line that passes through the midline). The presence of any structures to the left or to the right of this line indicates a midline shift
 - A shift indicates a pathology on the contralateral side
 - The shift is reported in millimeters; if the shift exceeds 1 cm, the patient is usually unconscious
 - Make sure to differentiate between a tilt and a shift. A tilt is a normal finding and has to do with the position of the patient. A tilt is present if the falx looks as a straight line that is tilted to the right or the left. A shift is when the falx is indented.
 - Presence/absence of hydrocephalus:
 - It is important to differentiate between a truly dilated ventricle and an atrophied brain.
 - In cases of hydrocephalus, the ventricles are dilated while sparing the other structures of the brain.
 - In the case of an atrophied brain, the lesion is diffuse. You can notice an increase in the size of the basal cisternae.
 - Brain atrophy is a normal process that starts at the age of 25-35.
 - The presence of a focal brain lesion
 - Brain lesions can be classified into:
 - Intraventricular: the lesion is inside the ventricles
 - Axial: brain stem, cerebral, or cerebellar lesion
 - Extra axial: the lesion is present between the brain and the bone
 - Scalp lesion: the lesion is present on the outer surface of the bone
 - Interosseous lesion: a lesion present inside the skull bone
 - Infratentorial: below the tentorium
 - Supratentorial: above the tentorium
 - It is important to specify the location of the lesion as it points to the type of the pathology:
 - On the inner side of the ventricles we have the following structures: choroid plexus, epyndema, and subepydema. Therefore, a meningioma can present as an intraventricular lesion as it originates from cells found inside the ventricles
 - An intraparenchymal lesion can never be a meningioma because the parenchyma does not contain cells that can produce a

meningioma. The structures found in the parenchyma include glial cells, lymphatics, and astrocytes.

- Extra-axial structures include meninges and vessels. Therefore, an astrocytoma can never present as an extra-axial lesion.
- In 80% of the times, you can arrive to a proper diagnosis or differential diagnosis based on the location of the lesion.
- In 20% of the cases, you depend on other factors to identify the pathology:
 - Age:
 - Pediatrics: Neuroblastoma, lymphoma, Wilm's tumor
 - Adults: lung CA with brain metastasis
 - Geographical factors: certain diseases are more prevalent in certain areas of the world
 - Appearance of the lesion:
 - Hyperdense
 - Isodense
 - Hypodense
 - Heterodense lesions
 - Enhancement: if a lesion enhances after injection of a contrast, this indicates a breach in the blood brain barrier.
- Normal enhancing structures:
 - Pituitary gland
 - Small blood vessels
 - Choroid plexus
 - Pineal gland
 - Meninges
- On A CT scan, different structures of the brain assume different degrees of coloration along the grey scale. This indicates different densities. In order to differentiate between the different structures, we use what is called the Hausfield units. These units are density units. The values are measured in reference to the density of water, which is given a Hausfield unit of 0. Any value above 0 is referred to as hyperdense. Any value below 0 is referred to as hypodense.
- Some important structures with their densities:
 - CSF: 5-8
 - Fat: -100
 - Air: -500
 - Hemorrhage: 50-70
 - Soft tissue: 35-70
 - Calcification: 100
 - Bone: 100
 - Contrast: 100-120

- Metal: 1000's
- Normal calcified structures:
 - Choroid plexus
 - Pineal gland
 - Falxcerebri
 - Meninges
 - Carotid cyphon
 - Basal ganglia: >70 years of age
- Important hypodense structures:
 - Sinuses: Air
 - Ventricles: fluid (CSF); hypodense compared to the surrounding brain tissue
 - Eye globe: vitreous fluid
 - Subcutaneous fat
- Important hyperdense lesions/structures:
 - Acute hemorrhage: the hemoglobin in RBC's (oxyhemoglobin and deoxyhemoglobin) gives it its hyperdense appearance
 - Calcified structures
 - Bone
 - Soft tissue of the brain:
 - Here, the densities of the white and grey matter are different. Due to this difference, the CT scan shows a border between the white and the grey matter. This border is called the grey-white matter differentiation.
 - The grey matter is more hyperdense than the white matter. The grey matter is found peripherally, while the white matter is found towards the center.
- How do we obtain a CT scan?
 - The patient is placed on the table; a lateral poor quality skull X-ray is taken. On this X-ray, we mark the vertex and the base of the skull (or the hard palate, if we want to take a CT of the sinuses)
 - Set the thickness of the cut
 - Let the machine take the image with or without contrast
 - If the patient moves during one of the images, we can repeat that cut only. However, if the image is an MRI image, the whole sequence needs to be repeated.
- Hyperdense pathologies (with or without contrast):
 - Hemorrhage (without contrast):
 - Intra-axial hemorrhages: intraventricular or cerebral hemorrhage
 - Extra-axial hemorrhages: epidural, subdural, or subarachnoid hemorrhages.
 - Cephalhematoma: bleeding between the skull and the periosteum
 - Bone lesions (without contrast)
 - Calcifications (without contrast)

- Tumors (with contrast): can look hypodense without contrast
- Abscess (with contrast): can look hypodense without contrast
- Intra-axial hemorrhage:
 - An intra-axial hemorrhage can be either intraventricular or cerebral.
 - An intraventricular hemorrhage has a worse prognosis and leads to the formation of a communicating hydrocephalus. Sometimes, an intraventricular hemorrhage can be due to an extension of a cerebral hemorrhage. However, it is rare to find a cerebral hemorrhage that is an extension of an intraventricular hemorrhage.
 - It is important to localize the site of cerebral hemorrhage as it helps you in identifying the pathology; classical hypertensive hemorrhage sites:
 - Putamen (most common site of hypertensive hemorrhage)
 - Thalamus
 - Cerebellum
 - Pons
 - A unilateral temporal hemorrhage is suggestive of herpes encephalitis; however, a bilateral temporal hemorrhage is diagnostic for herpes encephalitis
- Extra-axial hemorrhages:
 - Epidural hemorrhage:
 - A hemorrhage between the periosteum and dura due to rupture of the middle meningeal artery (most common) or due to rupture of the superior sagittal sinus (rare)
 - The typical hemorrhage (90-95%) looks like a biconvex (lens-shaped) hyperdense lesion that is unilateral and supratentorial.
 - Atypical hemorrhages:
 - Bilateral, venous, infratentorial, not due to trauma.
 - Hypodense hemorrhages (compare its density to air in the sinuses or the mastoid air cells)
 - If the density of the hemorrhage is the same as the air sinuses; this indicated pneumocephalus (air in the brain). In this case, you need to look for a skull fracture
 - If the density of the hemorrhage is more than the density of the air sinuses, the hemorrhage has already clotted.
 - Linear hypodensity (Swirl sign):
 - The presence of a linear hypodensity indicates active bleeding inside the hemorrhage.
 - The hypodensity is formed due to the movement of new blood into the hemorrhage site.
 - Treatment: craniotomy
 - In the case of an epidural hemorrhage, the treatment is craniotomy. Burr holes are not used.

- Due to the absence of CSF, epidural hemorrhages clot. If burr holes are used, the clots cannot escape, and this might complicate the case. However, if a craniotomy is performed we allow the clot to escape.
 - Diagnostic challenges: Sometimes, an epidural hemorrhage might not be present at the time of presentation to the ER. They develop later. How long does it take for a hemorrhage to develop? It depends:
 - Arterial hemorrhages can take up to 36 hours
 - Venous hemorrhages can take up to 72 hours.
 - If you suspect an epidural hemorrhage, the patient should be observed for 72 hours in order to make sure no complications happen.
 - An epidural hemorrhage is an emergency. If it is not treated promptly, patients will die.
- Subdural hematoma:
 - Bleeding between the arachnoid layer and dura.
 - The bleeding usually is of a venous origin.
 - Unlike epidural hemorrhage, a subdural hemorrhage is not a surgical emergency.
 - The appearance is a semi-lunar lesion. The typical patient is an elderly who has suffered a minor trauma.
 - The density of the hemorrhage depends on its age:
 - Acute: hyperdense. The hyperdensity is due to the presence hemoglobin inside RBC's
 - Subacute: isodense. The isodensity is due to the transformation of hemoglobin to methemoglobin
 - Chronic: hypodense. Due to the presence of hemosiderin and ferritin
 - Acute on top of chronic: fluid-fluid level, which is indicated by the presence of a hyperdense and hypodense lesions in the area of hemorrhage. The acute blood is heavier than chronic blood; therefore, the acute blood collects towards the bottom of the hemorrhage.
 - Treatment: Burr hole
 - Here, we can use a burr hole instead of a craniotomy because blood does not clot
 - Although the subdural space does not communicate with the CSF, blood does not clot because the trabeculae rupture. This rupture leads to a CSF leak into this space.
 - In a young healthy patient, an acute subdural hematoma carries a worse prognosis than an epidural hematoma. The reason is still unknown.

- Subarachnoid hemorrhage (SAH):
 - A hemorrhage into the subarachnoid space (between the pia and arachnoid matter); in traumatic cases, the most common cause of bleeding is venous injury. The most common cause for this type of bleeding is trauma. However, the most common non-traumatic cause is the rupture of a berry aneurysm.
 - In a normal brain, the sulci appear as hypodense areas due to the presence of CSF. In the case of a subarachnoid hemorrhage, the sulci might look hyperdense due to accumulation of blood.
 - Treatment:
 - Post-traumatic: conservative
 - Aneurysm: repair of the aneurysm
 - As a rule, when you obtain a post-traumatic CT, do not use contrast. A contrast can give you signs of cortical enhancement, which can be confused with a SAH.
- Pediatric patients:
 - In a pediatric patient, the presence of HbF (during the first two months of life), will result in a hyperdense area along the sinuses. This means that, in pediatric patients, enhancing sinuses are normal. However, in adult patients, this can signify an infarct.
 - The presence of enhancing lesions inside the brain (parenchymal) enhancement is abnormal.
- Calcifying lesions:
 - A calcified lesion has the density of bone, and is defined as the presence of a calcification in area other than the normally calcifying areas in the brain.
 - Can be classified according to age and symmetry of calcification:
 - Pediatrics:
 - Bilateral symmetrical:
 - TORCH
 - Metabolic diseases
 - Bilateral asymmetrical:
 - TORCH
 - Tuberos sclerosi
 - Adults:
 - Bilateral symmetrical: metabolic diseases
 - Bilateral asymmetrical (usually multiple or with blood):
 - Metastasis from a primary tumor: mucinous cell tumor, bone tumor, cartilage tumor)
 - Any brain metastasis following chemotherapy or radiotherapy.

- Extra-axial calcifications: indicate a meningioma
 - Cortical calcifications: indicate Sturge-Weber disease
 - The best modality to view a calcified lesion is a CT scan
- Hypodense lesions:
 - There are normal hypodense structures in the brain; these include air filled sinuses, ventricles, the globe, and subcutaneous fat.
 - An abnormal hypodense lesion is usually the result of an edema.
 - Edema can be classified into:
 - Diffuse or focal
 - Diffuse edema can be subdivided into medical and post-traumatic
 - Focal edema is further subdivided into: Vasogenic or cytotoxic
 - Diffuse edema:
 - Diffuse hypodensity
 - Loss of grey-white differentiation
 - Effacement of sulci
 - Decreased size of ventricles
 - In medical causes of diffuse edema, the falx might falsely look hyperdense. This hyperdensity is an illusion due to the surrounding hypodensity caused by the edema. This is known as the pseudosubarachnoid hemorrhage sign.
 - In post-traumatic causes, the edema is usually asymmetrical and it is associated with other signs of injury
 - Focal edema:
 - Cytotoxic edema:
 - Usually due to an infarct
 - Depending on the site of the edema, we can determine the site of the infarct. The edematous region lies in the territory of the infarcted vessel:
 - Temporal edema: MCA infarct
 - Central edema (on both sides of the falx): ACA infarct
 - Posterior edema: PCA infarct
 - If the edema is limited to one arterial territory, the cause is usually a cardiac embolus
 - If there is edema in more than one territory there are two possibilities:
 - The infarct lies at a common origin of two arteries in the cause of a middle and anterior cerebral artery territory edema. In this case, the prognosis is worse because the infarction is caused by an atheroma. Atheromas do not respond to anticoagulants.

- Multiple emboli that caused infarction in multiple territories; ex. Edema in left and right MCA territories. In this case, the prognosis is better, because anticoagulants can help dissolve an embolus.
- An infarct is a clinical diagnosis; the CT scan might be falsely normal. We use the CT to differentiate between a hemorrhagic and non-hemorrhagic infarct. A CT scan can be normal up to 72 hours after an infarct.
- In cases of a hemorrhagic infarct, we do not give anti-coagulants. However, if there is no hemorrhage, a trial of anti-coagulants is worthwhile.
- Vasogenic edema:
 - Usually due to metastasis, primary tumor, or an abscess.
 - The edema is usually around the grey-white junction due to the hyper-vascular nature of that area.
 - The edema results from the loss of the blood brain barrier. On a CT scan, the edema appears as finger-like projections with swelling of the affected area.
 - To determine the cause of the edema, a contrast is injected:
 - Ring enhancement: indicates an abscess
 - Irregular or homogenous enhancement: indicates a tumor
- To summarize:
 - Cytotoxic edemas are considered as medical emergencies. No contrast is needed, steroids are not used, and we do not use antibiotics
 - Vasogenic edemas: they are not medical emergencies. A contrast is needed to differentiate between the causes, we do not use anticoagulants.

X-ray; general

- History:
 - o X-ray was discovered by a German scientist on 20/11/1895.
 - o In July 1896, X-ray started as a clinical practice in the USA and in Europe
 - o The first X-ray department was opened in 1904 at the Royal Glasgow infirmary by John MacIntyre .
 - o After WWII, the nature of the X-rays was discovered; they are now considered as part of the ionizing radiations.
- Structure of the X-ray tube:
 - o The tube is made of a cathode and an anode.
 - o The cathode is the positive terminal of the X-ray tube. It is made of thin filaments made out of Tungsten metal. These filaments light up while taking a radiograph.
 - o The anode is the negative end of the X-ray tube. Nowadays, it is made of a circular rotating part that captures the rays. In the old days, it used to be a square immobile mass. The use of a rotating anode prolongs the life of the tube
 - o An electrical circuit: 220 Volts
 - o The price of an X-ray tube depends on the amount of heat it can withstand. The higher the heat, the higher the price. Prices range from 30,000\$ for a plain radiographic machine to 200,000 dollars for the tubes used in a CT scan machine.
- Radiation modalities can be divided according to the use of ionizing radiation:
 - o Ionizing radiation modalities:
 - Plain films
 - Colored radiographs
 - DEXA scan
 - CT scan
 - o Non-ionizing radiation modalities:
 - MRI
 - Ultrasound
- In general we abide by the ALARA principle when using ionizing radiation: as low as reasonably achievable exposure.
- Ionizing radiations are superior in:
 - o Staging tumors (CT)
 - o Post-traumatic (CT)
 - o Fractures (CT or X-ray)
- MRI is superior when visualizing soft tissues
- Contraindications to X-ray: the most important contraindication is the first 6 weeks of pregnancy. This period is critical for organogenesis. Exposure to X-ray during this period results in severe congenital malformations
- Important radiological terms:

- Penetration: it is related to the ray used. It is defined as the ability of a ray to go through a certain tissue. The higher the tissue's density, the lower the penetration. Therefore we can order penetration in a descending fashion (most to least) as follows: air, bone, metal (lowest penetration)
- Attenuation: this is related to the tissue properties. It is defined as the ability of a tissue to resist the passage of rays through it. The less dense the tissue is, the lower the attenuation (the rays can pass easily) Therefore, we can order the tissues in a descending fashion as follows: metal, bone, air (lowest attenuation).
- Therefore, the tissues with the highest penetration and lowest penetration appear denser on a film (whiter)
- Structure of the X-ray film and image production:
 - The film is made of plastic. This plastic is covered with a layer of silver nitrates. This film is put inside a cassette. The cassette is coated with a group of metals known as rare earth metals (a thin layer of 1 mm).
 - Rare earth metals are a group of metals that produce a color when stimulated by light. When we use in a cassette, we decrease the amount of radiation needed to produce an image on the film.
 - The X-ray passes through our tissues, then hits the film. As it passes through the tissues, it goes through the processes of attenuation and penetration. If the ray does not penetrate the tissue, the rays never reach the film. However, if they penetrate the tissues, the rays reach the film and cause discoloration.
 - The different properties of tissues will result in varying degrees of black and white on the film which produces the image.
 - The film is originally white; when the rays hit them film, it becomes black. The more radiation that goes through a tissue, the darker the tissue appears. Therefore, bones appear white (low penetration), and air filled spaces appear black (high penetration)
- The aforementioned technique is the classical X-ray technique; however, to health and economical reasons scientists sought a better alternative for production of images. This leads us to the topic of development of X-ray technology throughout history.
- Development:
 - Instead of using a film inside the cassette, scientists replaced the film with a 1 cm layer of rare earth metals. Which means, that the cassette no longer contained a film and was made only of a 1 cm layer of rare earth metals. This decreased the amount of radiation needed and allowed for digital transfer of photos on a computer. This is known as computed radiology (CR). This technique, however, had its downfalls. Due to the mobile nature of the cassette, it was prone to falling down and breaking. Moreover, the computer, sometimes, cannot read the signal off a cassette correctly resulting in an aberrant image. Furthermore, sometimes, the signal from a cassette is not transferred completely to the computer; when a

second photo is taken, the resultant image will be an overlap between the previous image and the current one.

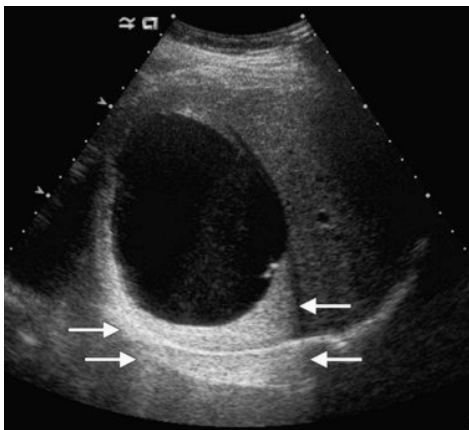
- Due to the aforementioned problems, a new technique was developed. The cassette became a part of the machine (the cassette is now immobile). This system is known as digital radiography. However, one problem remained. The images needed to be transferred to a CD or a floppy disk and needed to be seen on a different device.
- This led to the development of the PACS system. PACS stands for picture archiving and communicating system. This system contains all the patient's images and doesn't need a CD to be viewed. However, this system did not show the reports. The reports still needed to be written by hand.
- Due to this problem, a new system was developed. This system is called the RIS system. RIS stands for radiology information system. In this system, we can find the patient's images along with the reports on the images.
- **Ultrasound:**
 - It is the safest radiological modality.
 - It can be used for imaging, taking biopsies, and drainage of cysts.
 - As a device the ultrasound has its limitations:
 - Fluids: fluids can be clearly seen on an ultrasound. Therefore, any fluid containing structure or any structure that can be filled with a fluid is suitable for ultrasound imaging.
 - Air: air is problematic; you cannot visualize organs containing air. Therefore, if a patient needs an ultrasound and an ERCP, you perform the ultrasound before performing the ERCP in order to avoid errors in reading the image.
 - Ultrasound is operator dependant.
 - Ultrasound can be used safely during a pregnancy. During a normal pregnancy, the US should be used three times only; one time during each trimester.
 - Doppler ultrasound is more harmful than regular ultrasound
- **MRI:**
 - The technology behind MRI has been around since the 1940's. Then, it was known as NMR (nuclear magnetic resonance). The term NMR is the accurate physical description of the process of MRI.
 - The use of MRI in clinical practice started after the introduction of CT scan machines.
 - The power of an MRI machine is measured using Tesla units. Clinically used MRI's have a power between 1.5-3 Teslas. The higher the Tesla, the higher the resolution of the image. Higher Tesla MRI machines (7-20) are still experimental.
 - There are two types of MRI:
 - Contrast: gadolinium contrast

- Without contrast
- Contraindications to MRI:
 - MRI without contrast:
 - The presence of any ferro-magnetic metals:
 - the MRI machine is essentially a magnet. Therefore, it is contraindicated if the person has any ferro-magnetic devices inside the body. The smaller the metal piece, the higher the damage.
 - Some non-ferro-magnetic metals are also hazardous. These metals tend to heat up during the procedure. These metals are found in cosmetic products, mascaras, and many prostheses.
 - Any device that contains a battery:
 - The MRI machine results in a huge discharge which empties the batteries of any device.
 - If a patient has a cardiac pacemaker, the pacemaker will stop working. This might lead to a sudden cardiac arrest
 - If the patient has a vagal nerve stimulator, the device will stop functioning. Although this is not an emergency, the cost of installing a new device is very high.
 - Cochlear implants
 - You should not have any device that contains a magnetic strip around an MRI machine. Due to the strength of the device, all information found on such devices will be erased immediately. These include credit cards and some USB devices.
 - Pregnancy:
 - MRI is only contraindicated during the first trimester of pregnancy because there are no sufficient data on its safety.
 - During the second and third trimesters, MRI's can be safely done. However, the machine's power should not exceed 2 Teslas. Radiations higher than 2 Teslas were associated with adult onset hearing problems.
 - MRI with contrast:
 - Pregnancy: contraindicated throughout the whole pregnancy
 - Renal failure:
 - GFR <30
 - It is associated with nephrosclerosis
- There are devices that are labeled as MRI compatible devices. These include pacemakers and vagal nerve stimulators. However, they are only compatible with

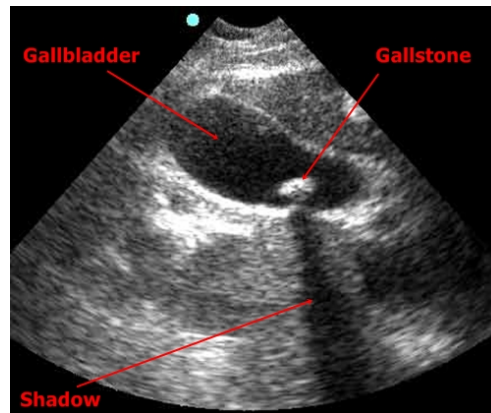
powers up to 1.5 Teslas. If the power of the MRI machine exceeds 1.5 Teslas, the device will be affected.

- Physics of ultrasound

- Ultrasound waves are a form of sound waves. The waves are produced by a crystal (piezoelectric crystal) found inside the ultrasonic probe. It is a type of real time imaging
 - The probe sends a wave through a medium (gel)
 - The waves travel through the medium and reach the body's internal organs. Then, they are reflected back to the probe that "listens" to the waves. The probe sends signals 99% of time and listens 1% of the time
 - An image is produced on the screen.
 - The reflections produce different colors along the grey-scale. The colors are referred to as echogenicity:
 - Hyperechoic: white
 - Isoechoic
 - Hypoechoic
 - Anechoic: black
 - The echogenicity of an object is determined according to the surrounding structures. For example, in the abdomen, the liver is isoechoic. The surrounding structures' echogenicity is measured in comparison to the liver. Any organ darker than the liver is hypoechoic, while any organ brighter than the liver is called hyperechoic.
 - Any fluid in the body is anechoic (urine, CSF, amniotic fluid, bile, blood). To differentiate between blood and other fluids we use flow ultrasound.
- The structures inside the body can be divided into weak and strong structures:
- Weak structures: the waves will be partially absorbed; the rest of the waves will pass through the organ and hit an organ underneath. The structure underneath the organ will look hyperechoic. This is known as enhancement.
 - Strong structures: strong structures reflect all the waves hitting them. Therefore, no waves pass beyond these structures. The structures beneath these structures appear very dark because no waves passed through. This is known as shadowing.
 - In general, weak structures are hypoechoic and strong structures are hyperechoic.

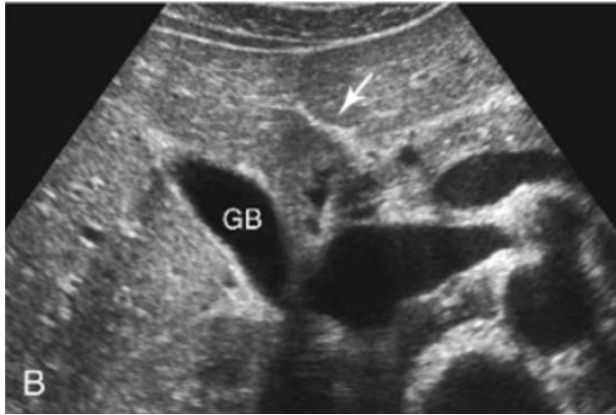

Enhancement



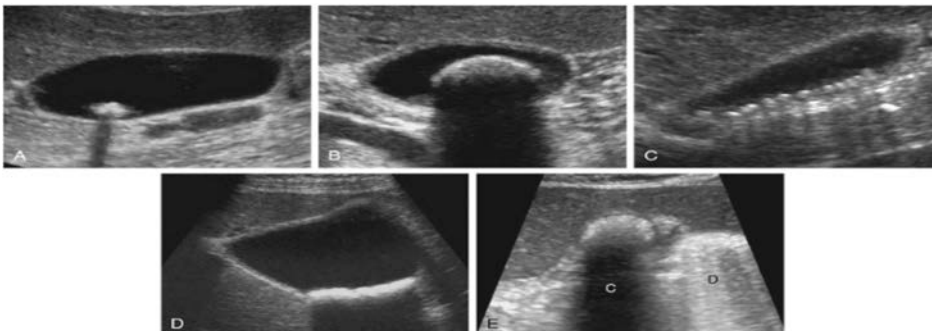
Shadowing

- Types of ultrasound probes:
 - o Linear: low wave depth, high resolution; used to image superficial organs
 - o Curvilinear: high wave depth, low resolution; used to image deep organs
 - o Trans-rectal and trans-vaginal probes
 - o Sector probes
- Modes of ultrasound:
 - o B-mode: brightness mode
 - The basic ultrasound mode
 - Used to visualize anatomy
 - Picture shows different shades of black and white
 - o Colored doppler:
 - Shows the flow and velocity of blood in the structure
 - Has two colors (red and blue):
 - Red indicates blood coming towards the probe
 - Blue indicates blood moving away from the probe
 - The direction of flow can help in determining the pathology. In a normal portal vein, blood flows towards the probe. However, in cases of portal hypertension, the blood flows away from the probe.
 - An increased flow velocity indicates stenosis
 - o Power doppler:
 - This mode shows the presence or absence of flow
 - Useful in testicular torsion; in cases of testicular torsion the flow is absent.
 - o Spectral doppler:
 - Used to differentiate between arterial and venous flow
 - The arterial flow is shown as triangular waves
 - The venous flow is shown as band waves.
- Views on ultrasound:
 - o Longitudinal view
 - o Axial view
- Important organs and their view on ultrasound:
 - o Gallbladder:
 - The gallbladder is found below the liver. In order to obtain a good view, the gallbladder needs to be filled with bile; therefore, the patient has to be fasting.
 - Normal appearance:
 - Anechoic interior: the gallbladder is filled with bile; bile looks black on an ultrasound
 - Size: 4 mm (short axis); 10 mm (long axis)
 - Wall thickness: up to 3 mm



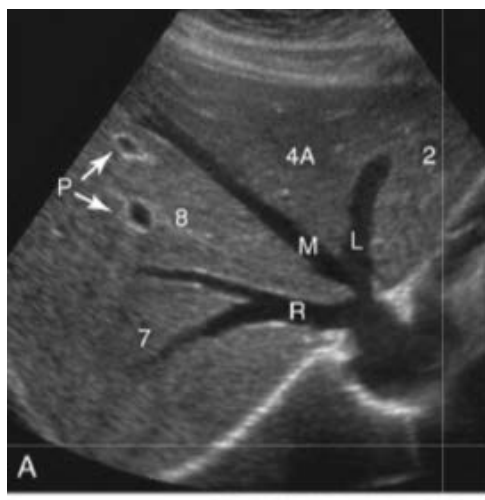
Normal gallbladder

- Gallbladder stones:
 - Ultrasound is the best modality to visualize stones. Only 15% of the stones will be visible using a plain radiograph. However, they are not good for visualizing renal stones. Renal stones measuring less than 7mm are rarely seen on an ultrasound.
 - Stones are strong structures that reflect all the waves. Therefore, if there is a stone, shadowing is obvious. However, stones less than 3mm in size might have no obvious shadow. The bigger the stone the bigger the shadow.
 - Sometimes, the stones might not look very hyperechoic. They might look as a precipitate on the interior of the gallbladder. This is known as sludge. To differentiate between sludge and a soft tissue abnormality, we switch to the power doppler mode. If there is no flow, the structure is sludge.
- Signs of acute cholecystitis:
 - Gallstones
 - Wall thickening >3mm
 - Gallbladder enlargement: the short axis is more sensitive than the long axis. If we have a gallbladder measuring 5 x 9mm; it is considered enlarged.
 - Pericholecystic fluid: not anechoic. Inflammatory fluid contains some inflammatory cells.
 - Sonographic Murphy's sign: one of the most important



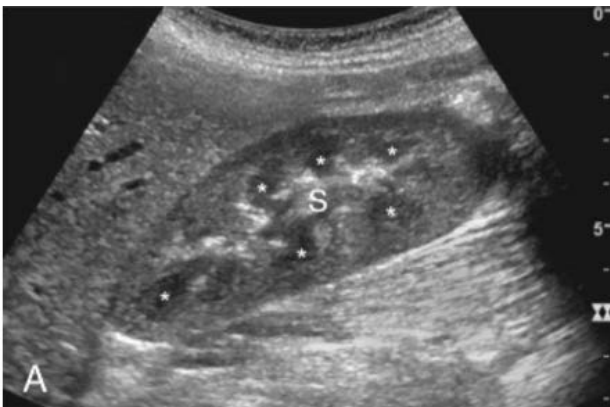
Gallbladder stones with shadowing

- How to differentiate between the liver and spleen on ultrasound:
 - o Anatomical position: the liver is on the right; the spleen is on the left
 - o The spleen has a smooth surface with one vessel at the hilum, while the liver has many vessels on its surface (including the IVC and its branches)
- Liver:
 - o The liver is located below the right costal margin.
 - o On ultrasound, it looks triangular. The ligaments look hyperechoic
 - o How to differentiate between portal veins and IVC and its branches:
 - The walls of portal veins are echogenic; the IVC and its branches do not have obvious walls
 - The IVC is obvious due to the presence of 3 branches coming out of it.
 - o How to differentiate between bile ducts and portal veins:
 - Both of these structures have hyperechoic wall, and they lie in close proximity to each other.
 - To differentiate between them, we use flow. The structures with flow are the portal veins.
 - o Normal measurements:
 - Liver span: <15 cm; the liver span is measured using an oblique line in a segment where you can visualize the kidney. So, you need to visualize the kidney lying beneath the liver, and measure the span obliquely.
 - The liver is a homogenous structure; it is hyperechoic compared to the kidney; however, it is hypoechoic when compared to the spleen and pancreas.
 - It has a smooth surface.
 - The common bile duct should never exceed 6mm in diameter. Exceptions to this rule are in older patients. In patients above 60, a mild dilation is accepted. Dilation of the common bile duct might indicate the presence of a stone.

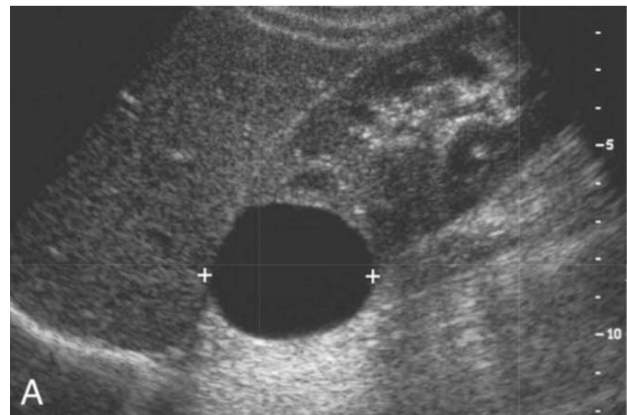

An ultrasound showing the IVC and its branches (R, M, L) along with the portal veins (P)

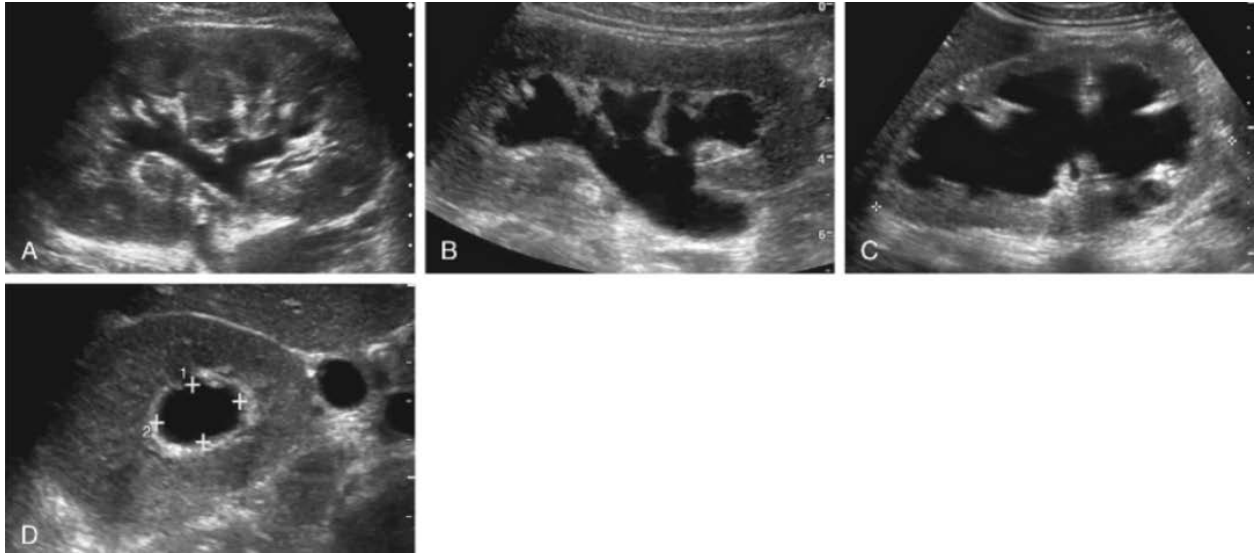
- Kidneys:
 - Bean shaped organ.
 - Has a cortex and a medulla.
 - The medulla has vessels, fat, and tubules, so it looks more echogenic.
 - The cortex is hypoechoic compared to the medulla.
 - Renal stones are hard to detect unless they exceed 7mm. The most accurate modality for detecting renal stones is a CT scan.
 - Normal kidney:
 - Size: Average 11 cm; range 9-13 cm
 - Echogenicity: the right kidney is hypoechoic compared to the liver. The left kidney is hypoechoic compared to the spleen.
 - Smooth surface
 - Homogenous except for a hypoechoic region at the pyramids and it is hyperechoic at the renal sinus.
 - Anything that causes kidney obstruction causes hydronephrosis:
 - Grade 1: dilation of the renal pelvis
 - Grade 2: dilation of renal pelvis and major calyces
 - Grade 3: dilation of the renal pelvis, major calyces, and minor calyces.
 - Grade 4: thinning of the cortex, and partial effacement of the medulla
 - Grade 5: ballooning of the kidney. The wall appears thin with no visible medulla. (rare)
 - Grade 1 and 2: mild hydronephrosis; grade 3: moderate hydronephrosis; grade 4 and 5: severe hydronephrosis
 - Renal cyst: renal cysts can be a normal fluids. They look as an anechoic sac with a very thin wall. Usually present with a mild enhancement behind the cyst.
 - Criteria for a simple cyst:
 - Non-measurable wall
 - Anechoic: only contain fluid
 - The presence of septations converts it into a complex cyst fluid Renal cortical cyst



Normal kidney

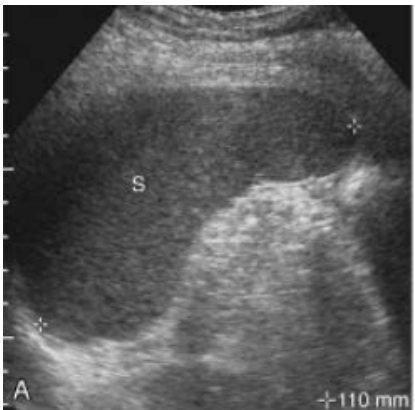


Simple cortical renal cyst



An ultrasound showing different grades of hydronephrosis: (A) grade 2 (B) grade 3 (C) grade 4 (D) grade 1

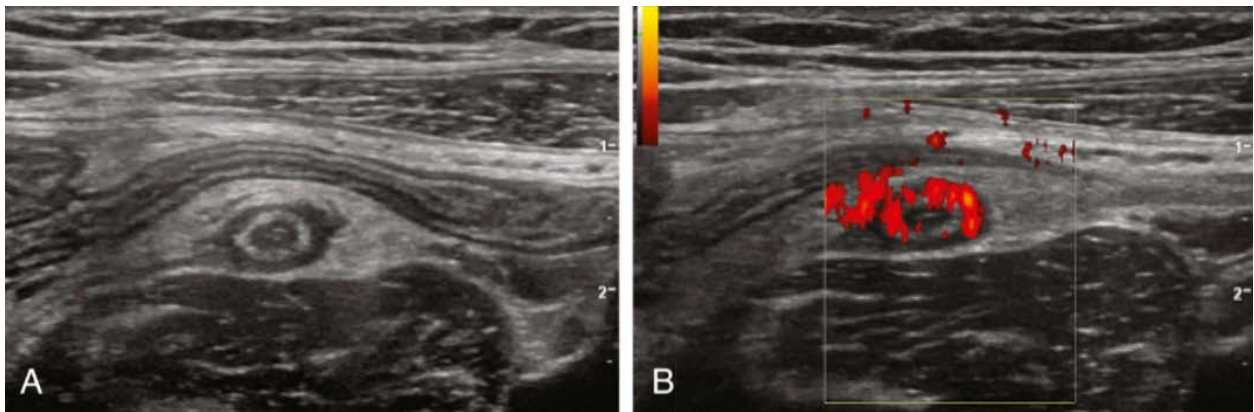
- Spleen:
 - A triangular shaped organ below the left costal margin. The edges are blunted. It has a smooth surface (homogenous)
 - Normal spleen:
 - Size: <13 cm long; <6cm thick
 - Hyperechoic compared to the cortex of the kidney; hypoechoic compared to the pancreas. Hyperechoic compared to the liver
 - Homogenous echogenicity



Normal spleen (S)

- Appendix:
 - The appendix is part of the bowel. A normal appendix is hard to visualize using an ultrasound. To get a clear view of the appendix, we ask the patient to fill his/her bladder.

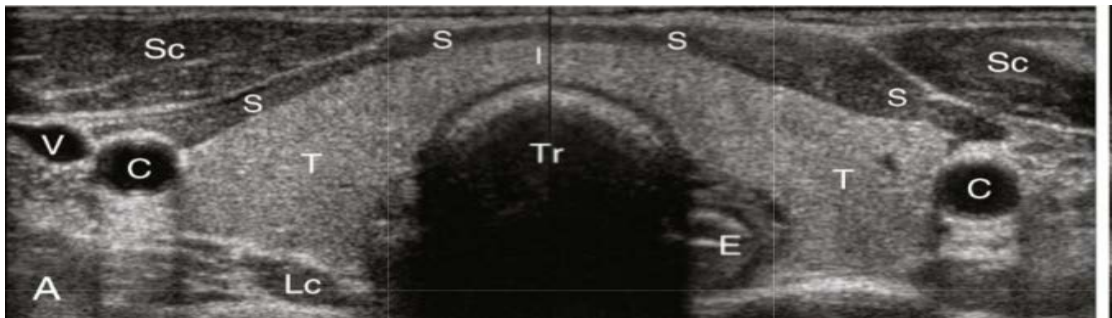
- To locate the appendix, we look for the cecum. At the cecum, we have two structures, the ileum and the appendix. To differentiate between them, we look for a peristaltic movement. The presence of a peristaltic movement identifies the ileum
- A normal appendix can rarely be seen and requires an experienced sonographer; therefore, we only image the appendix in cases of appendicitis.
- Signs of appendicitis:
 - Diameter > 6mm
 - Lack of compressibility
 - Inflamed echogenic fat planes (surrounding the appendix)
 - Hyperemia: increased blood flow
 - Appendicolith: fecolith material inside the appendix
 - Adjacent fluid collections
 - Regional lymph node enlargement
- Bull's eye sign (target sign): this sign is pathognomonic of appendicitis. This sign results due to the presence of a thickened wall, fecolith material, and inflammation of the appendicial fat planes.



- (A) Bull's eye appearance of the kidney. From the inside out: fecolith surrounded by an anechoic lumen, thickened wall, hypoechoic fluid collection, inflamed hyperechoic fatty planes.
- (B) Increased flow to the appendix.

- Thyroid:
 - The thyroid gland is located in the neck. It is made up of two lobes and an isthmus separating these two lobes. We need to measure both lobes and the isthmus to obtain full measurements of the thyroid. Moreover, we need to look for nodules or any enlargements. Behind the isthmus, there is an anechoic region. This is the trachea.
 - The thyroid is a homogenous structure. Long axis not more than 2 cm.

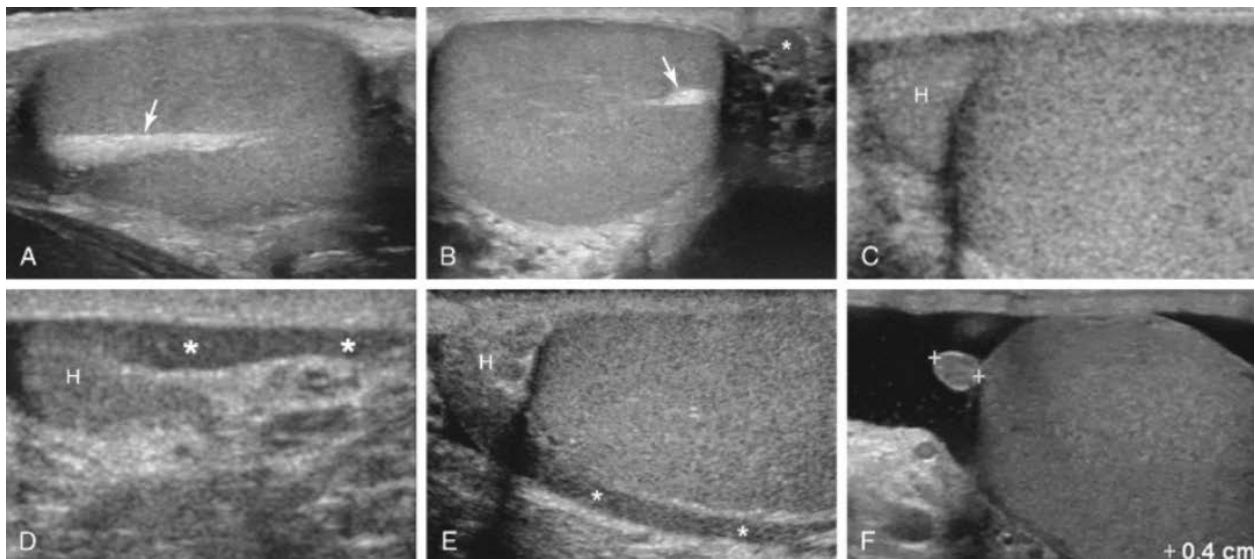
- Important structures surrounding thyroid:
 - Laterally: carotid artery and jugular vein. The structure directly lateral to the thyroid is the carotid artery; lateral to the carotid artery, we find the jugular vein. The jugular vein is compressible; the carotid artery is not.
 - Anterolaterally: sternocleidomastoid muscle
 - Anterior to the isthmus: strap muscles
 - Posteriorly: trachea
 - Posterior to the left: esophagus
- Normal thyroid:
 - Hyperechoic compared to adjacent muscles
 - Homogenous
 - Scattered readily detectable internal vessels
 - Diameter less than 2 cm in the AP and transverse views
 - Isthmus is less than 4 mm



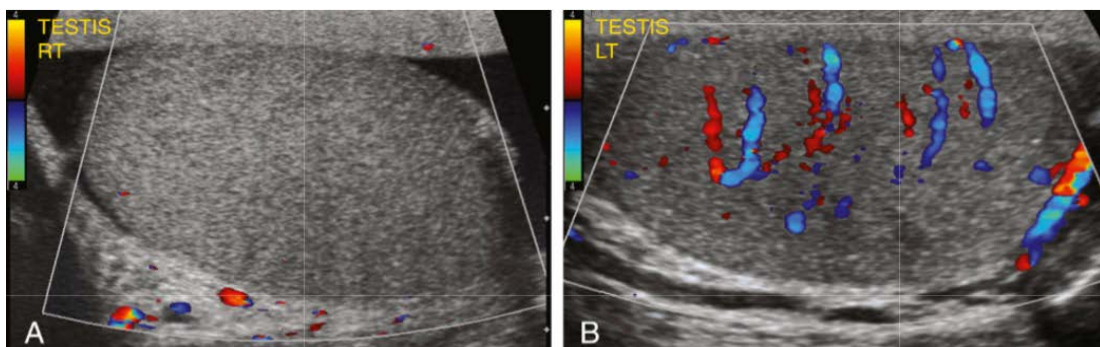
Normal thyroid gland with the following structures (T) lobes (S) strap muscles (Sc) SCM (C) carotid artery (V) jugular vein (E) esophagus

- Scrotal ultrasound:
 - When performing a scrotal ultrasound, you need to comment on 4 things:
 - Testes
 - Epidydemes
 - Presence or absence of a hydrocele
 - Presence or absence of a varicocele
 - Testes normally looks homogenous, and have a hyperechoic line called mediastinal testes (all the blood flow to testes comes through here)
 - When we look at the testes, there is a cap like triangular structure on the posterior aspect. This is the head of the epididymis. The head of the epididymis is isoechoic compared to the testes; however, the tail and the body are hypoechoic.
 - Testicular appendages; normal variant

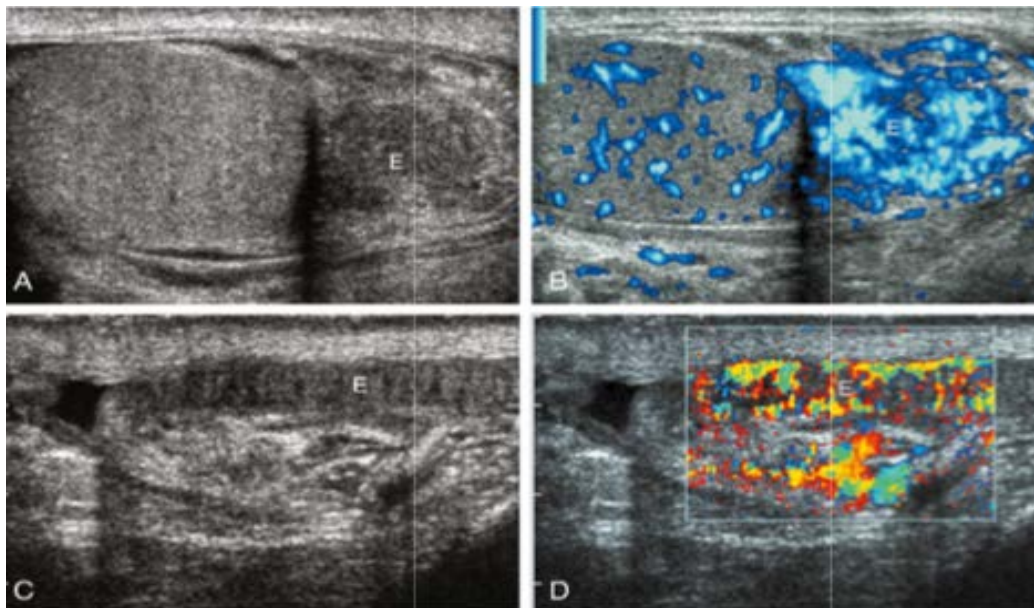
- Testicular torsion:
 - It is one of the urological emergencies that need to be handled within 6 hours. If testicular torsion was repaired 6-24 hours after the injury, we can only save 20% of the patients.
 - On ultrasound, the most important sign is absence of flow to the testes.
- Inflammatory scrotal processes:
 - Epididymitis: inflammation of the epididymis; looks enlarged on ultrasound. If the inflammation extends to the tail and the body, they might look enlarged.
 - Orchitis: Inflammation of the testicles; the testicles look asymmetrical and heterogenous. Moreover, the inflamed side will have an increased blood flow.



An ultrasound showing a normal testicle. (A) testicle; the arrow points to mediastinal testes. (B) mediastinal testes at the arrow (C) the structure labeled (H) is the head of epididymis (D) head of epididymis (H) and body of epididymis (stars) (E) tail of epididymis (stars) (F) testicular appendage (stars)

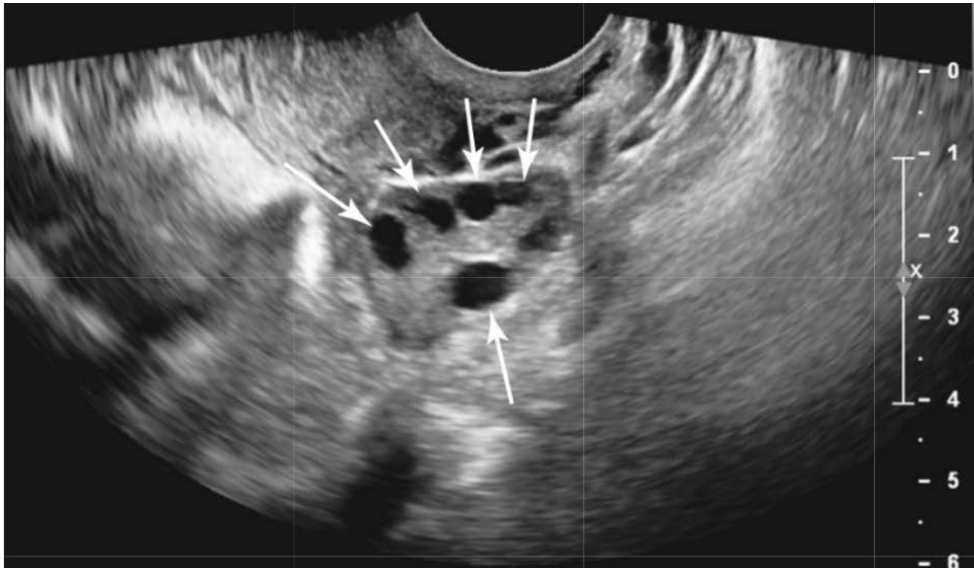


Ultrasound of right and left testes showing decreased blood flow to the right testis (A) indicating testicular torsion

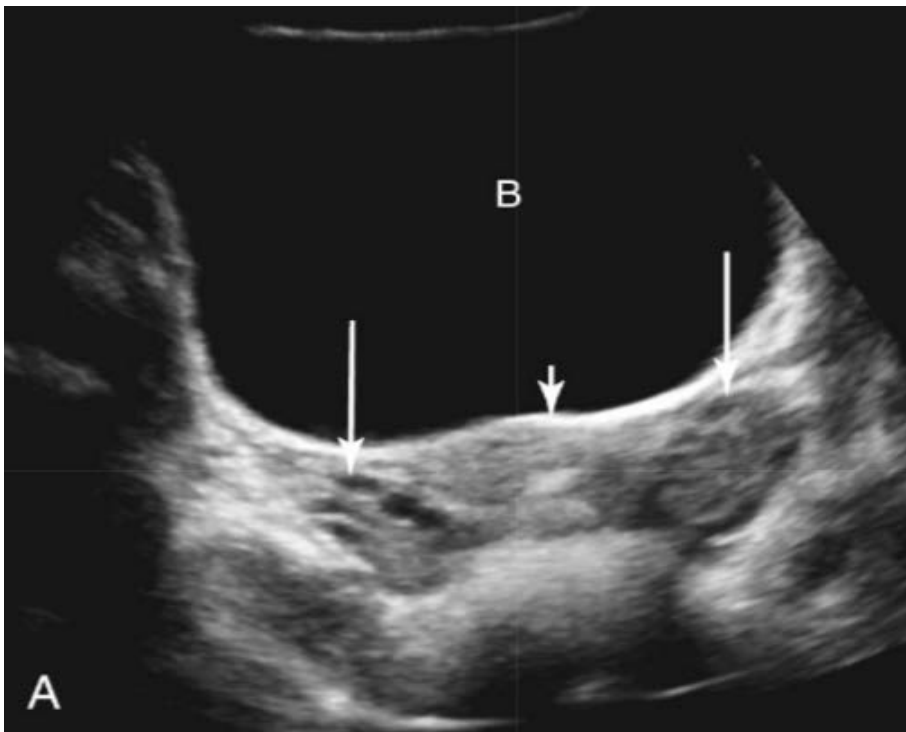


An ultrasound showing an enlarged epididymis (A) with an increase in blood flow (B) and the body is enlarged (C); this indicates epididymitis

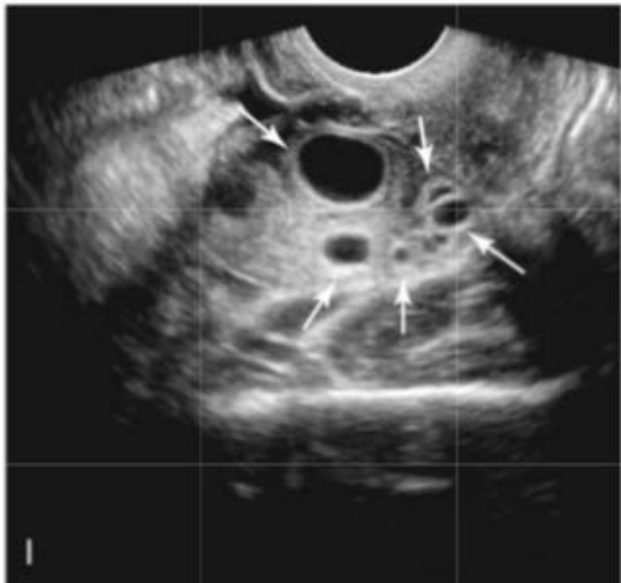- Female pelvis (ovaries)
 - To obtain an ultrasound of the female pelvis, we either use a transabdominal or a transvaginal transducer. The presence of fluid in a female pelvis can be a normal finding depending on the phase of the menstrual cycle. However, the presence of fluid in a male pelvis is abnormal.
 - Ovaries:
 - Ovaries are ovoid structures present lateral to the uterus
 - They are usually filled with follicles, which appear as anechoic sacs of varying sizes. The presence of follicles distinguishes the ovaries from adjacent structures.
 - They are hyperechoic compared to the uterus.
 - Blood flow to the ovaries is not diagnostic of ovarian torsion. Due to their deep pelvic position, ovarian blood flow might not be visible on the ultrasound. Therefore, we depend on other signs to determine whether ovarian torsion is present.
 - Ovarian torsion (signs)
 - Midline ovaries (behind the uterus or in front of it)
 - Follicles are pushed away (abnormal position of follicles)
 - Enlargement of the ovaries



Normal ovary with follicles (arrows)

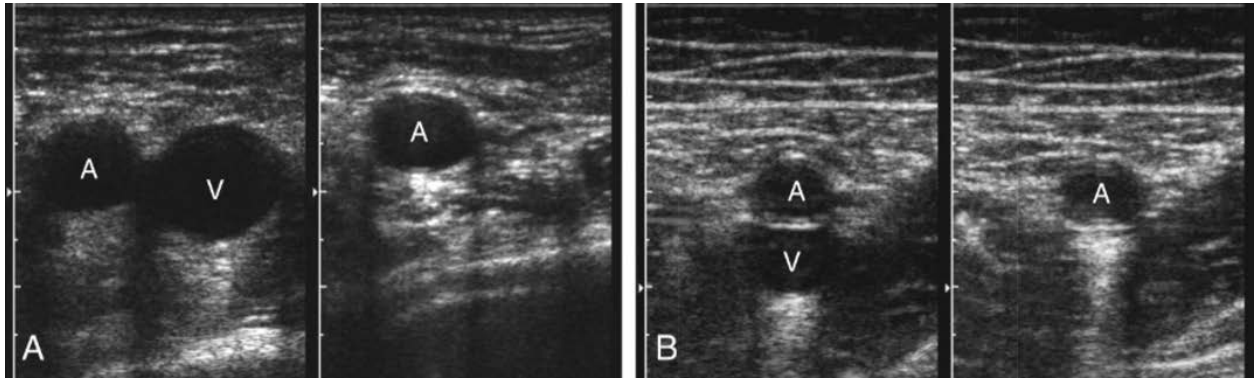


Normal ovaries (long arrows) normal uterus (short arrow)

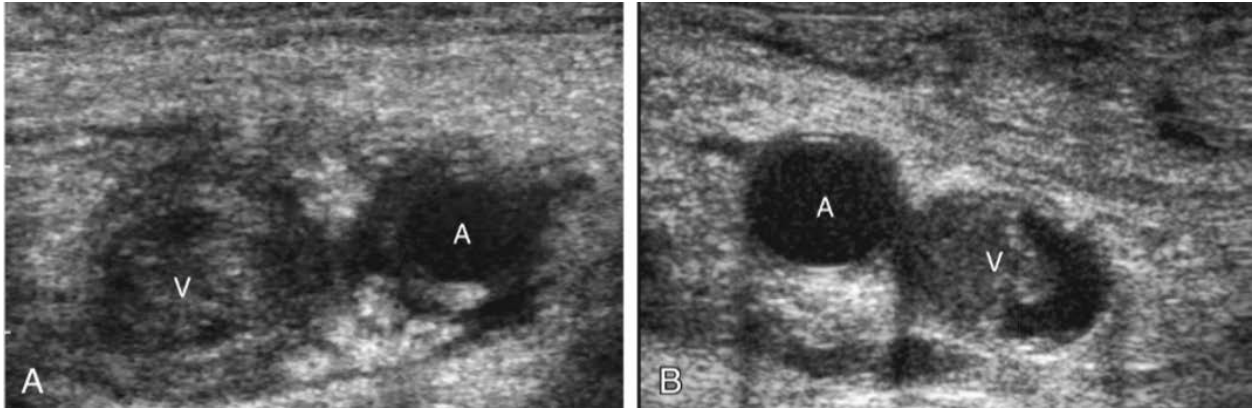


Ovarian torsion with a midline ovary and pushed away follicles (arrows)

- DVT:
 - To diagnose DVT, we need to obtain a doppler study of the common femoral vein, femoral vein (superficial femoral vein), origin of profundafemoris vein, and popliteal vein.
 - In the inguinal region, the vein lies on the same level of the artery. In the popliteal area, the vein is deep to the artery.
 - Veins are compressible, and collapse completely when pressed. In the case of DVT, the veins become incompressible.
 - Diagnosis of DVT:
 - Incompressible veins
 - Presence of a thrombus; not important for diagnosis. However, if present indicates DVT.
 - Decreased blood flow through the vein

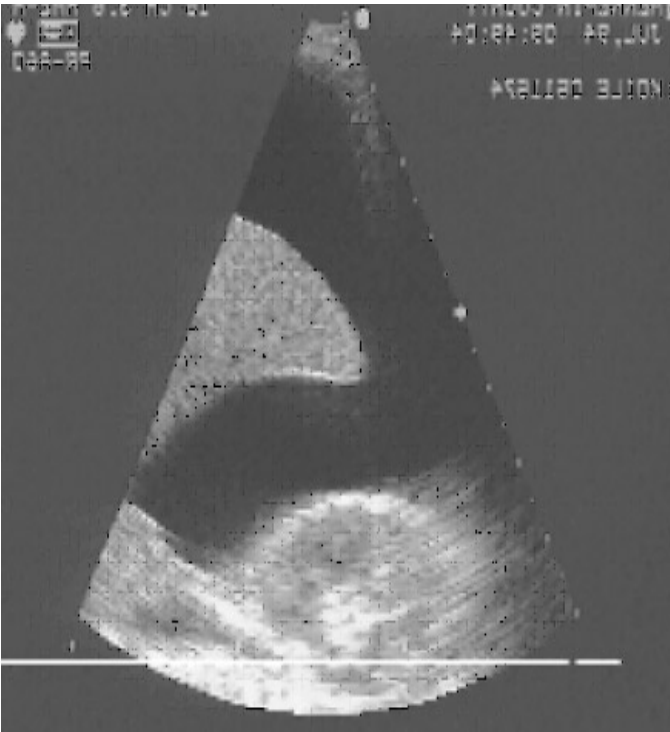


(A) Normal vein in the inguinal region; notice that it gets compressed easily
 (B) Normal vein in the popliteal region; notice that it gets compressed easily

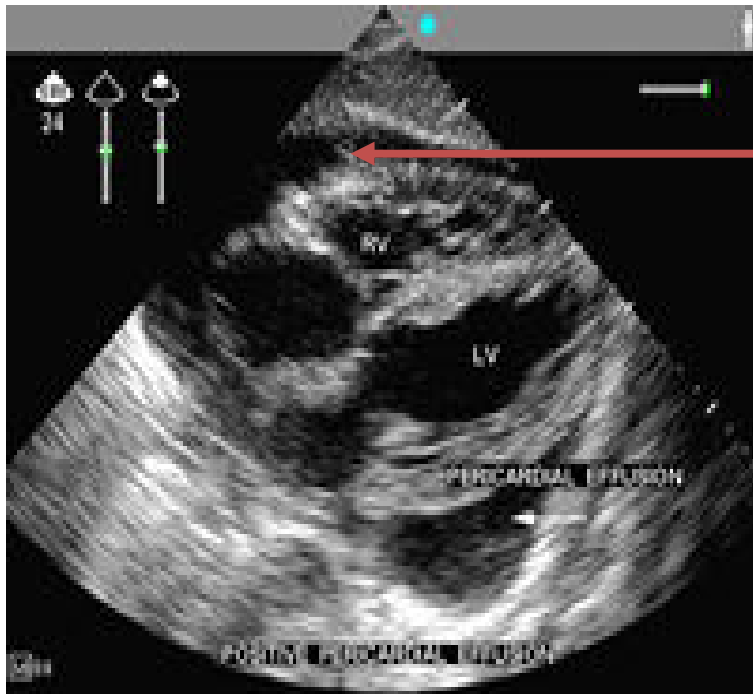
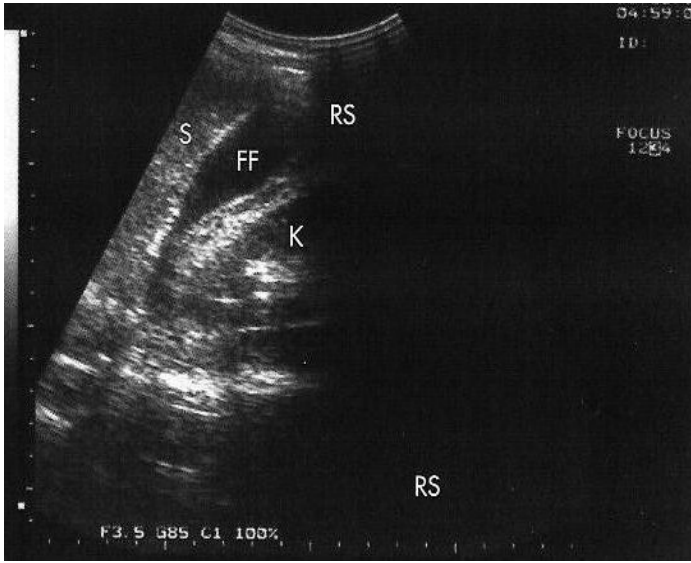


A case of DVT in the inguinal area; notice the thrombus in the vein and lack of compressibility

- FAST study:
 - FAST stands for fast assessment with sonography in trauma
 - A FAST study is part of the ATLS protocol, and it is used to assess the presence of abdominal fluid in case of a trauma.
 - We obtain an ultrasound from:
 - Right upper quadrant: fluid in Morrison’s pouch
 - Left upper quadrant: fluid in the spleno-renal recess
 - Subxiphoid area: cardiac fluid
 - Suprapubic area: pelvic fluid; normal in females
 - A positive FAST: presence of an anechoic strip in one of the 4 areas tested. This anechoic stripe represents free fluid in an area where it should not be found.



Free fluid in Morrison’s pouch

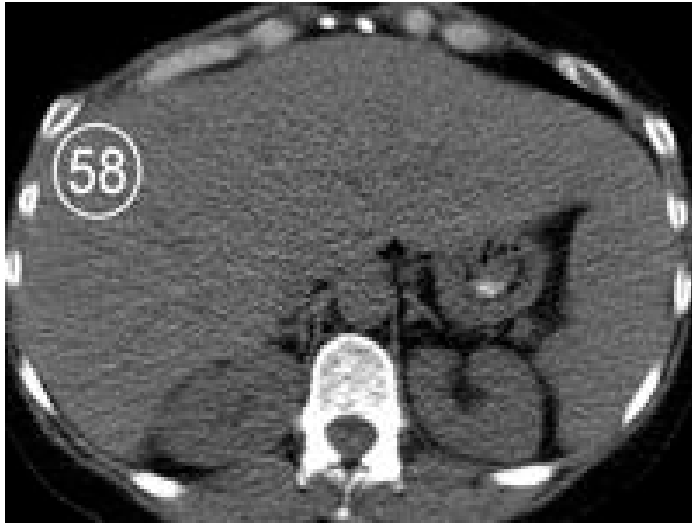

Pericardial effusion (red arrow)

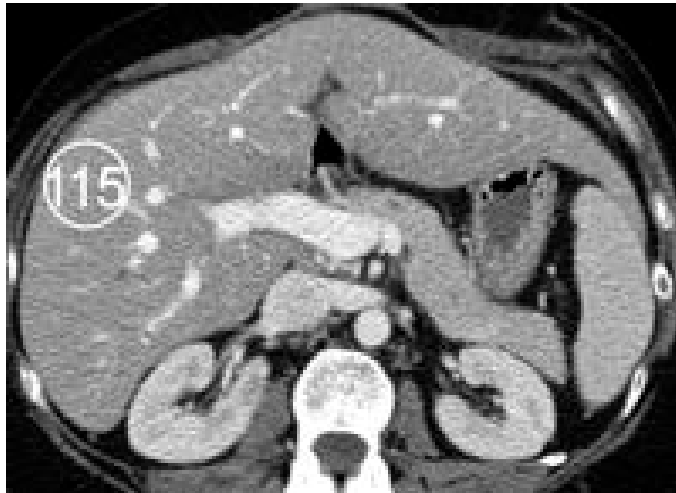
GIS radiology

- For exam purposes, the GIS is the most important system to study. There are two questions:
 - o What type of study?
 - o What are the pointed structures
- Objective of this lecture: to be able to differentiate different anatomical structures in the GI tract and identify the common pathology
- What is a CT scan? A CT scan is a type of ionizing radiation. It utilizes X-rays to obtain thin slices of a structure. A computer, then, reconstructs the images to produce a 3D representation of the area under study.
- A CT image shows the structures along the grey scale. The white the structure, the denser it is. Therefore, white structures are called hyperdense. The darker the structure, the less dense it is. Therefore, darker structures are called isodense. The density in a CT scan is measured using the Hausfield units.
- How to describe a study?
 - o Anatomical region ex. Chest or abdominal CT
 - o Type of cut: Axial, sagittal, or coronal
 - o Type of contrast:
 - Non-contrasted
 - Contrasted:
 - IV contrast
 - Oral contrast
 - o When you are asked to point to an organ, make sure to state where it lies (left or right)
 - o Ex: This image shows an abdominal axial CT scan with/without IV contrast; with/without Oral contrast.
- How to differentiate between a contrasted and a non-contrasted CT:
 - o A non-contrasted CT is a CT of low resolution. The borders separating the organs (or structures) are not clear. A non-contrasted CT is ordered in the following cases:
 - Renal failure
 - Suspicion of renal or gallbladder stones (remember CT scans are the most sensitive study to detect renal stones; however, an ultrasound is the ideal modality for detecting a gall bladder stone)
 - Post-traumatic CT's: Here, we are looking for a hemorrhage. On a contrasted CT scan, hemorrhages can be masked by the presence of the contrast (they have similar densities)
 - Renal failure or previous allergy to contrast material.
 - o How to tell if contrast material is present:
 - IV contrast (the presence of at least 1 of the following criteria):
 - Liver vessels appear hyperdense in comparison to liver parenchyma.
 - The vessels appear hyperdense compared to paraspinal muscles (especially the aorta and IVC)

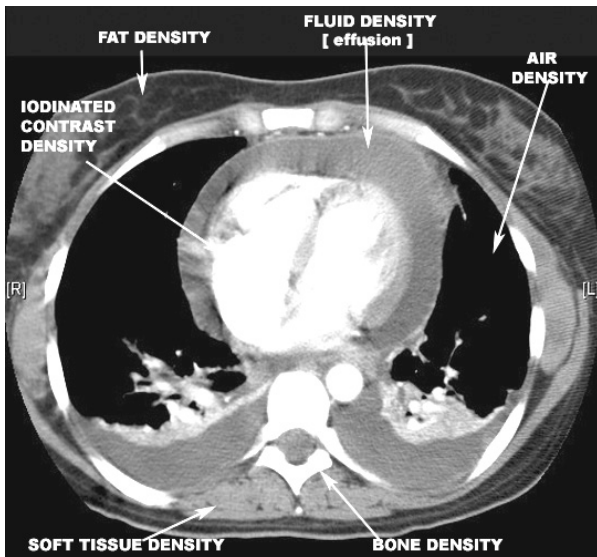
- Cortico-medullary differentiation of the kidney: the presence of two different densities on the kidney..
- Oral contrast: the presence of contrast density (hyperdensity) in a hollow organ like the stomach or bowel.



A non-contrasted axial abdominal CT scan. Notice that the borders between organs are not clear and notice the lack of corticomedullary differentiation in the kidneys.

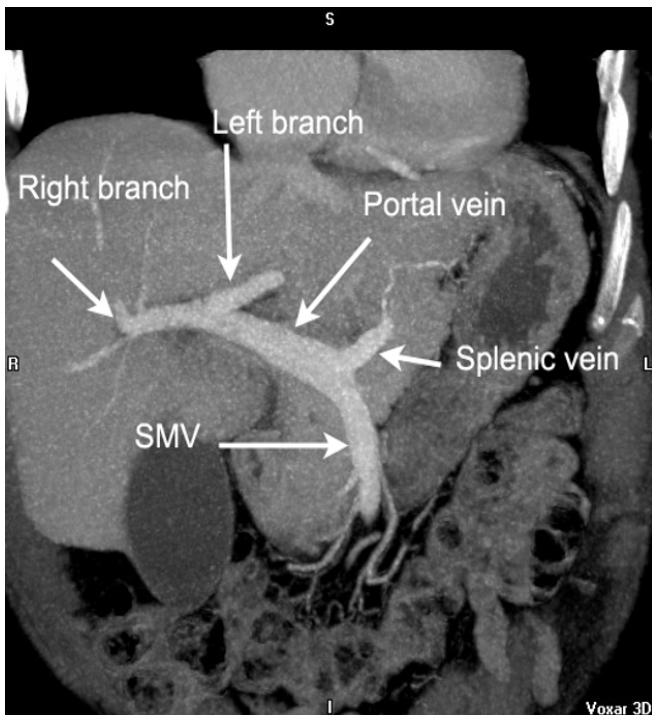


An IV contrasted axial abdominal CT scan. Notice the hyperdensity of liver vessels. And hyperdensity of the aorta.



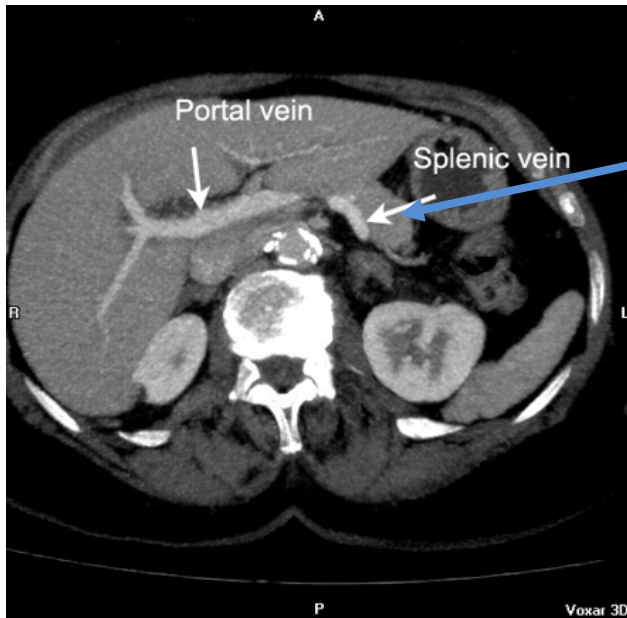
An axial abdominal CT scan with IV and oral contrast. Notice the hyperdensity inside the stomach. Notice the hyperdensity of the aorta.

- Important densities: in an abnormally hyperdense or hypodense region, the density can indicate the type of pathology
 - o Bone (highest density): 1000
 - o Contrast density
 - o Soft tissues: 40-60
 - o Fluid: 0
 - o Fat: -20 -- -30
 - o Gas (lowest density): -1000
 - Abdominal CT (important organs):
 - o Portal vein:
 - the portal vein is formed by the confluence (joining) of the superior mesenteric vein and splenic vein at the level of L1.
 - The portal vein is formed behind the neck of the pancreas
 - Lateral to the portal vein, we find the head of the pancreas.
 - Lateral to the head of the pancreas, we find the second part of the duodenum.
 - To differentiate between the portal vein and hepatic veins, we look for the following features:
 - The portal vein has a short extrahepatic course; however, the hepatic veins are completely intrahepatic
 - The hepatic veins drain into the IVC where it is nearest to the liver.
- Therefore, on a CT scan, we see the three branches converging on the inferior vena cava. However, the portal vein is formed by two veins that lie outside the liver; they converge to form the portal vein. The portal vein, then, divides into two branches intrahepatically (right and left branches)



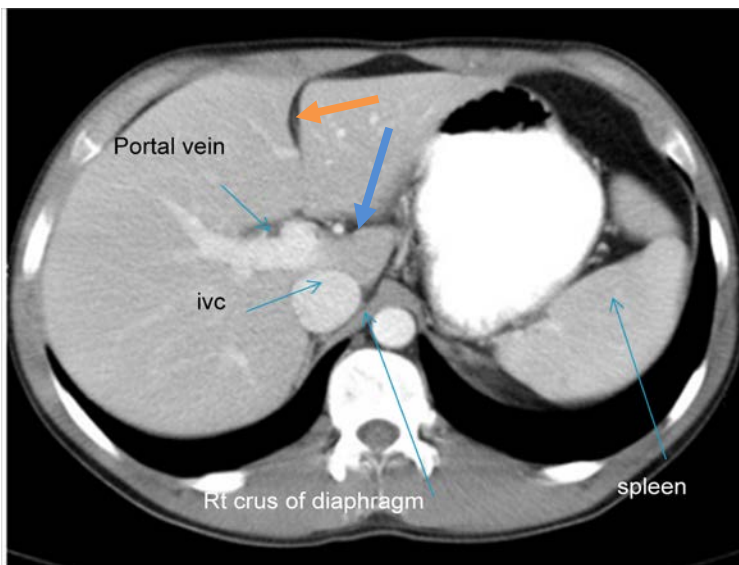
A coronal IV contrasted abdominal CT scan showing the confluence of the portal vein

- The pancreas:
 - The pancreas crosses the midline.
 - To identify the spleen, we look for the splenic vein. The splenic vein is posterior to the body of the pancreas.
 - The tail of the pancreas lies between the spleen and the left kidney.



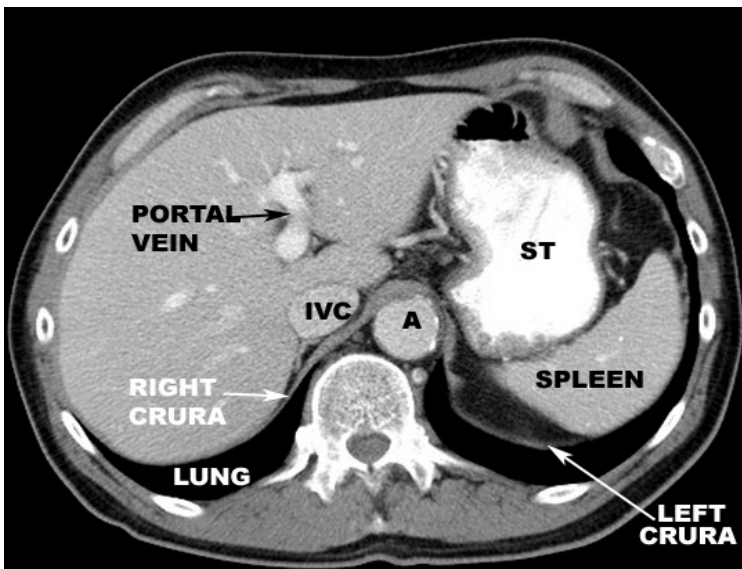
An axial IV contrasted abdominal CT scan showing the splenic vein, and portal vein, and the spleen (blue arrow)

- The liver:
 - The liver lies below the costal margin, and can extend beyond the midline.
 - In the liver, we need to identify the caudate lobe.
 - The caudate lobe lies anterior to the IVC and posterior to the fissure of ligamentumvenosum (a hypodense strip on the liver, through which ligamentumvenosum passes).
 - Fissure of ligamentumteres: a vertical fissure that lies right below the costal margin.



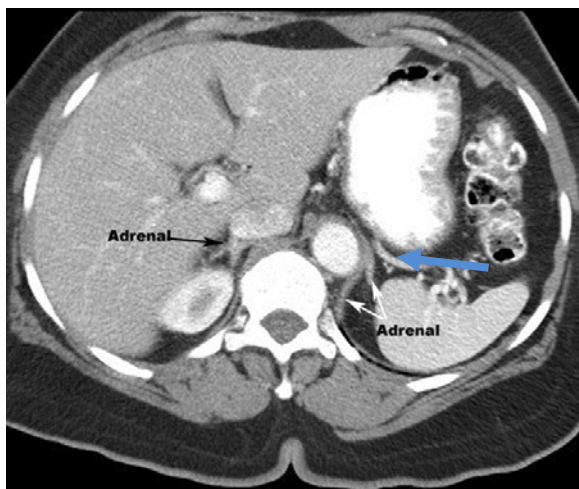
Abdominal Axial IV and oral contrasted CT scan of the abdomen. The blue arrow points to the fissure of ligamentumvenosum. The orange arrow points to the fissure of ligamentumteres.

- The aorta and IVC:
 - The structure that lies directly anterior to the vertebra is the aorta.
 - The structure that lies anterolateral to the aorta is the IVC.
- Diaphragmatic crura (singular crus)
 - There are two crura, one on the right and one of the left.
 - These crura surround the aorta and attach to the diaphragm on its inferior surface.
 - These structures have soft tissue density and surround the aorta in front of the vertebra. They can only be visualized on a high abdominal cut (a cut right below the diaphragm)



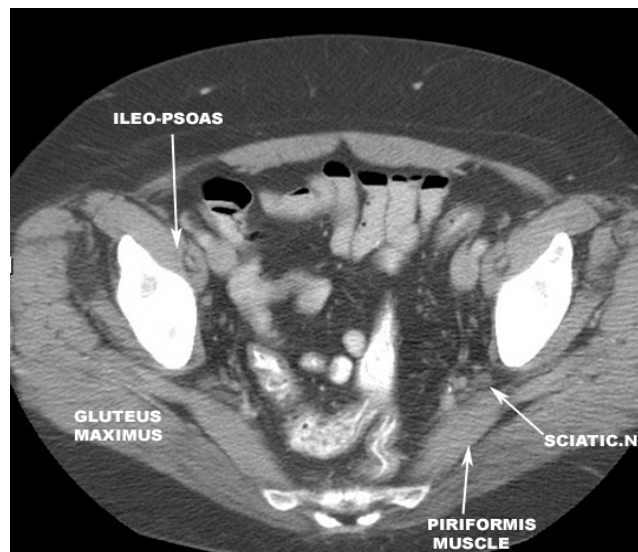
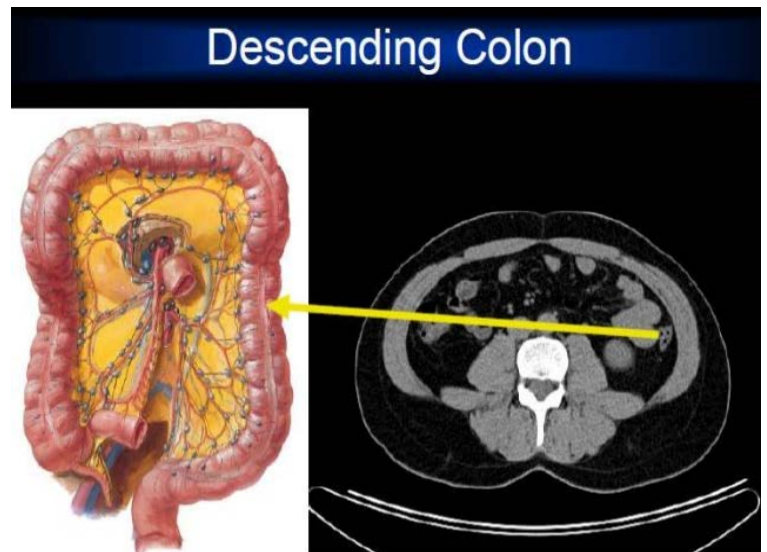
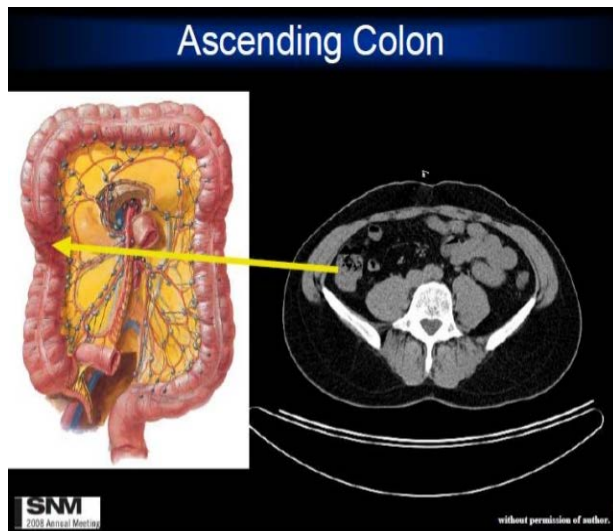
Axial abdominal oral and IV contrasted CT scan. Showing the right and left crura surrounding the aorta.

- Adrenal glands:
 - Each gland is made of a lateral and a medial limb. These limbs converge on a body.
 - They look like inverted letter "Y"
 - The right adrenal gland is superior to the right kidney
 - The left adrenal gland lies anterosuperior to the upper pole of the left kidney.



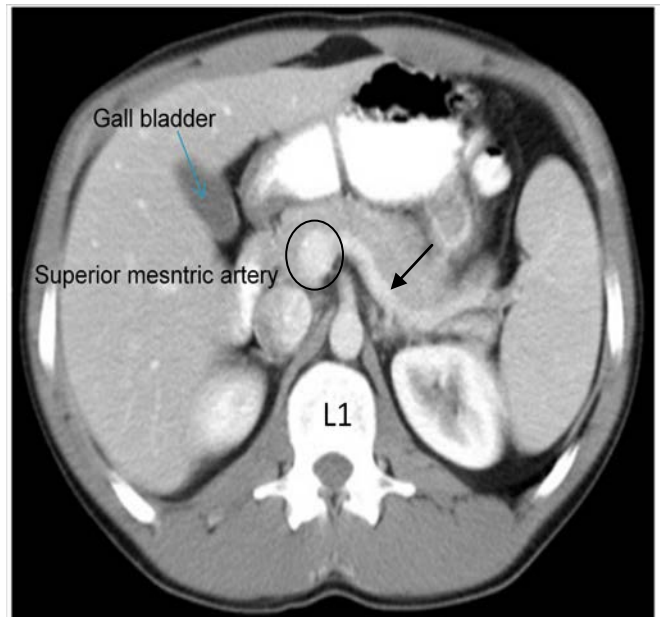
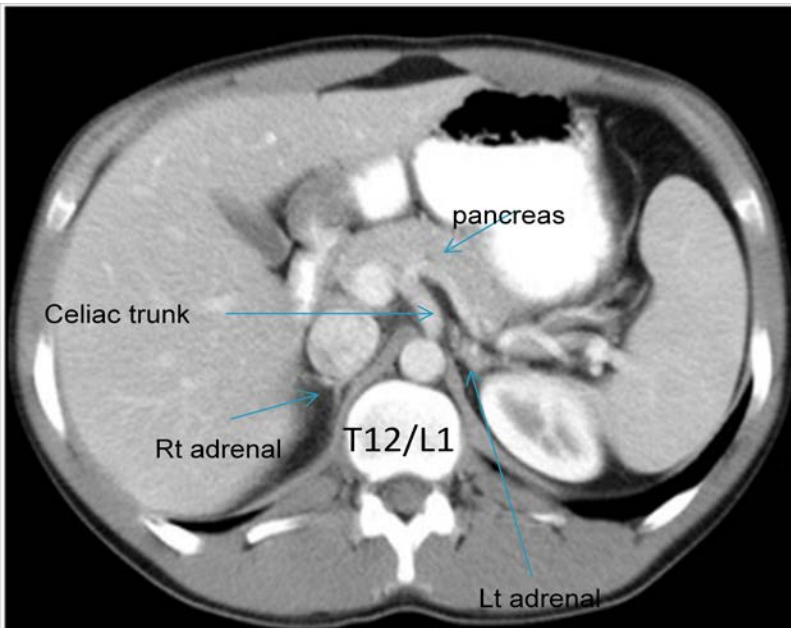
Abdominal axial CT with oral and IV contrast showing both adrenal glands. The tortuous structure emerging from the spleen is the splenic artery (blue arrow)

- The colon:
 - The colon is the most peripheral structure inside the abdomen.
 - It is divided into three parts:
 - The ascending colon: to the right
 - Descending colon: to the left
 - Transverse colon: anteriorly
 - The sigmoid appears as an S-shaped structure in the lower pelvic cuts.
 - To differentiate large bowel from small bowel, we look at the content. Small bowel has fluid like density and might have air-fluid level. Large bowel have fecal material with air trapped inside (black dots inside the fluid)



○ Important vessels:

- It is important to differentiate between the superior mesenteric artery and the celiac artery.
- The celiac artery and superior mesenteric arteries are branches of the aorta.
- The celiac artery branches at the level of T12/L1. It arises as the celiac trunk; then, it branches into the splenic artery (left), common hepatic artery (right), and left gastric artery (small and cannot be seen on a CT scan. The arteries appear as a seagull (seagull sign).
- The superior mesenteric artery is a branch of the aorta at the level of L1. It is on the same level as the splenic vein and superior mesenteric vein
- How to differentiate between them:
 - Level of the cut; if you have to adjacent cuts, the higher level is the level of the celiac artery
 - The presence of the seagull sign; however, its absence does not mean that this artery is the superior mesenteric artery. However, its presence confirms that the artery is the celiac artery
 - If you can see the confluence of the portal vein, the splenic vein, or superior mesenteric vein, you are at the level of the superior mesenteric artery.

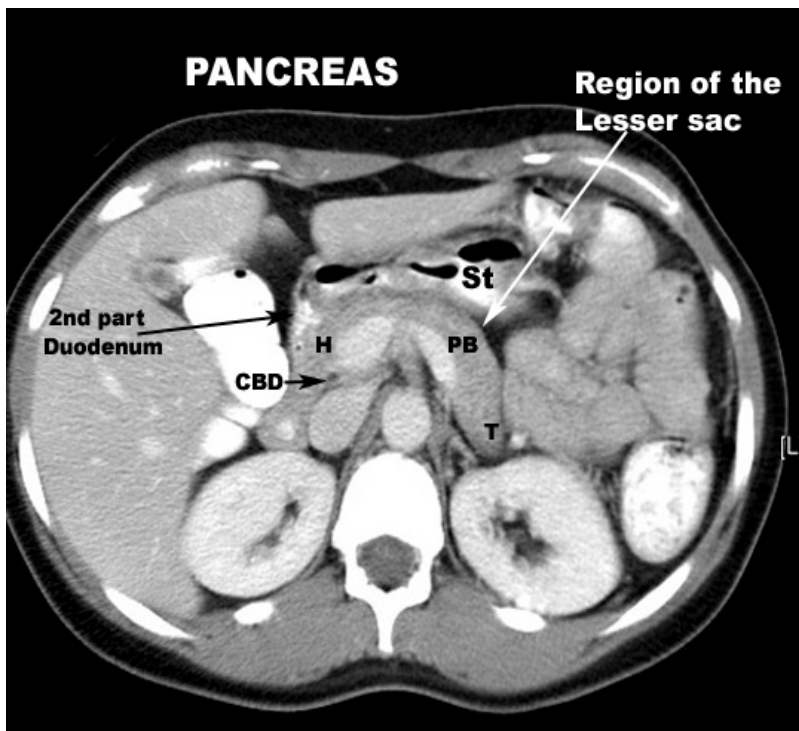


Black arrow: gallbladder
Black circle: seagull sign

Black arrow: splenic vein (posterior to the spleen)
Black circle: confluence of SMV and splenic vein

- The gallbladder:
 - The gallbladder is present on the inferior surface of the liver
 - It first appears as a structure with fluid density (due to the presence of bile inside)
 - The bile never takes up contrast.

- The pancreas:
 - The pancreas is divided into four parts:
 - Uncinate process (related to the third part of duodenum)
 - Head (related to the second part of duodenum)
 - Body (we find the splenic vein posterior to the body)
 - Tail (lies between the spleen and the kidney)
 - The pancreas crosses the midline. From an anatomical point of view, the tail is at a level superior to the head. This means that the pancreas has an oblique direction inside the abdominal cavity.



H: head of pancreas

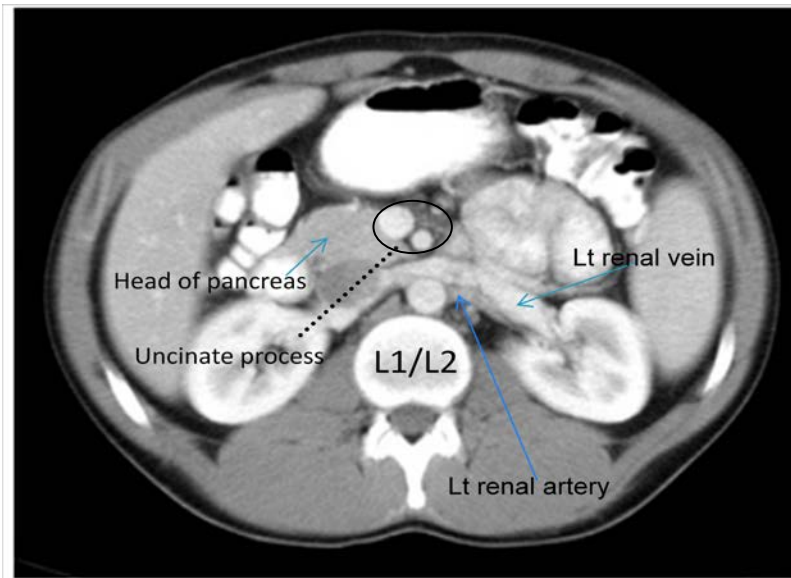
PB: pancreatic body

T: tail of pancreas

CBD: common bile duct

St: stomach

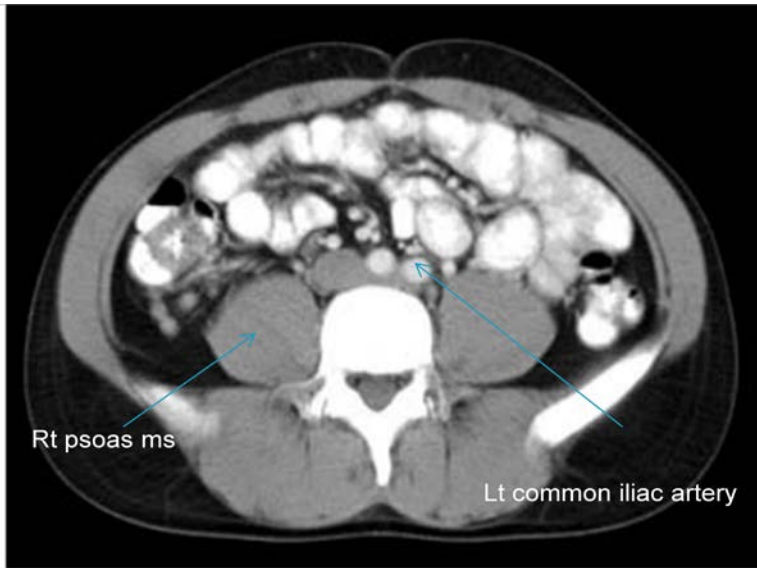- Importance of superior mesenteric vessels:
 - The mesenteric artery and vein have a signet ring appearance on abdominal CT (two rings adjacent to each other)
 - Behind the superior mesenteric vessels, we can find the following structures (anterior to posterior)
 - Uncinate process of the pancreas
 - 3rd part of the duodenum
 - Left renal vein
 - In obese patients, these structures are separated by planes of fat. In case of rapid weight loss, the loss of fat will lead to crowding in this area. This is known as the superior mesenteric syndrome. The superior mesenteric syndrome can present as intestinal obstruction (at the level of the 3rd part of duodenum) or superior mesenteric ischemia (due to pressure on the superior mesenteric artery).



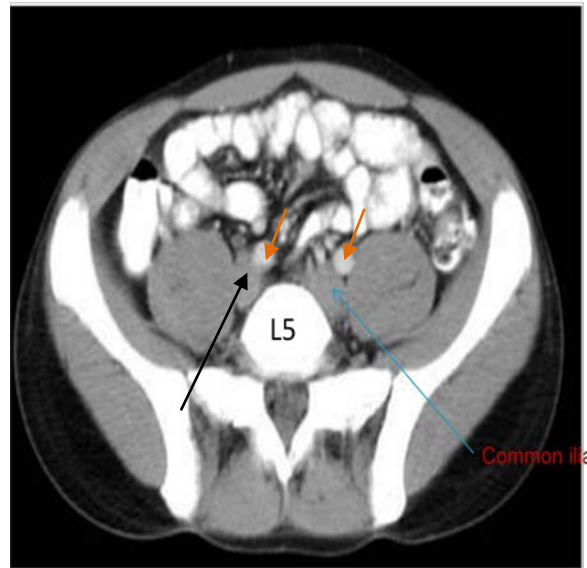
Black circle: superior mesenteric vessels.

- CT at level of L4 and L5:
 - L4:
 - At the level of L4, the abdominal aorta divides into right and left common iliac arteries.
 - This is the only abdominal CT section where we can find three vessels (2 common iliac vessels, and IVC)
 - L5:
 - At this level, the inferior vena cava is still not formed.
 - At this level we can see the two common iliac veins and two common iliac arteries

- This is the only level where we can see 4 vessels.

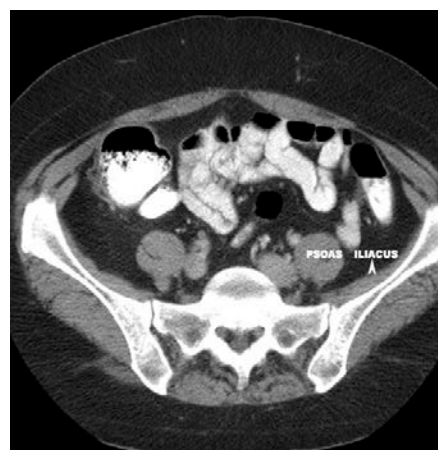
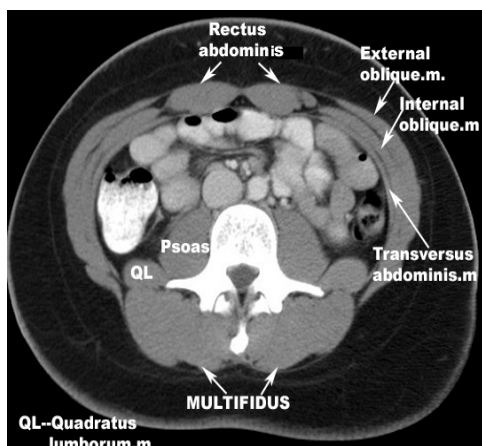


Abdominal CT scan at level of L4; showing the two common iliac arteries and IVC (black circle)

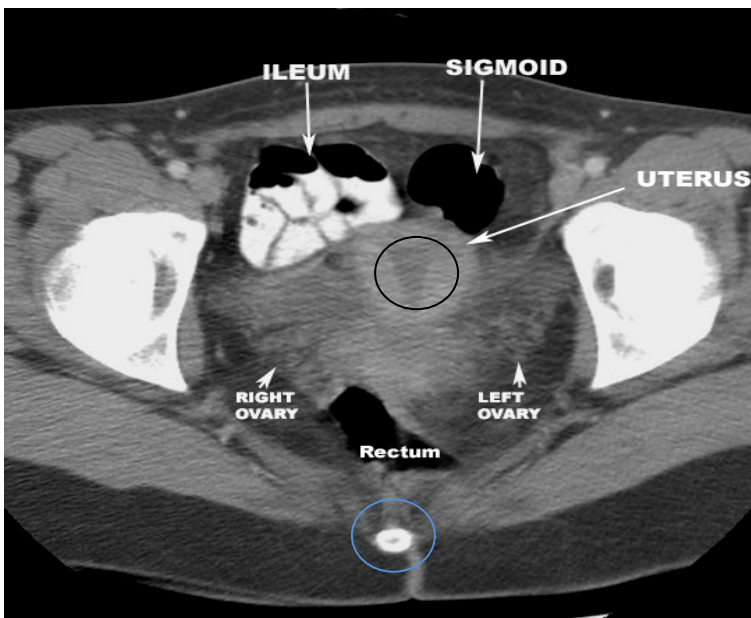


Abdominal CT at level of L5 showing left and right common iliac veins (black and blue arrows); and left and right common iliac arteries (orange arrows)

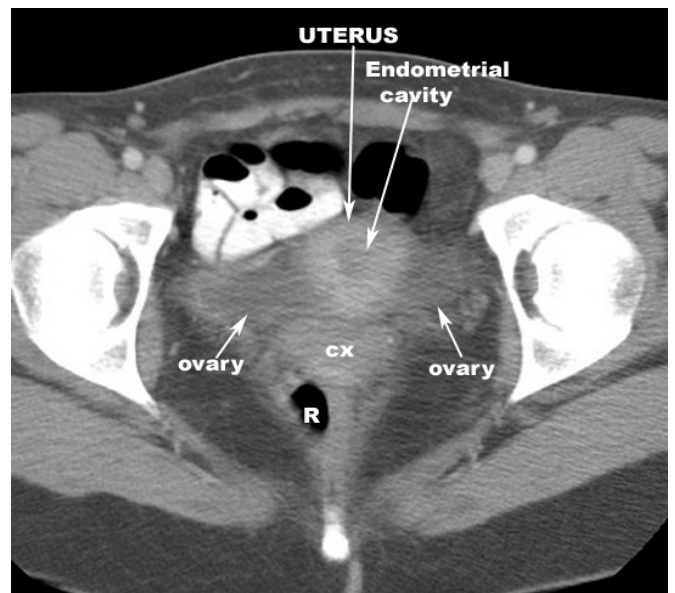
- Important muscles in the abdominal area: (The obliques are separated by a thin line of fat; the line of fat looks hypodense)
 - Rectus abdominus: anterior wall of the abdomen separated by linea alba
 - Psoas muscle: on both sides of the spine
 - External oblique muscle
 - Internal oblique muscle
 - Transversus abdominus Important muscles: psoas, rectus abdominus, external oblique, internal oblique, transversus abdominus.
 - At the level of iliac bone: iliacus muscle on the internal aspect of the iliac bone.



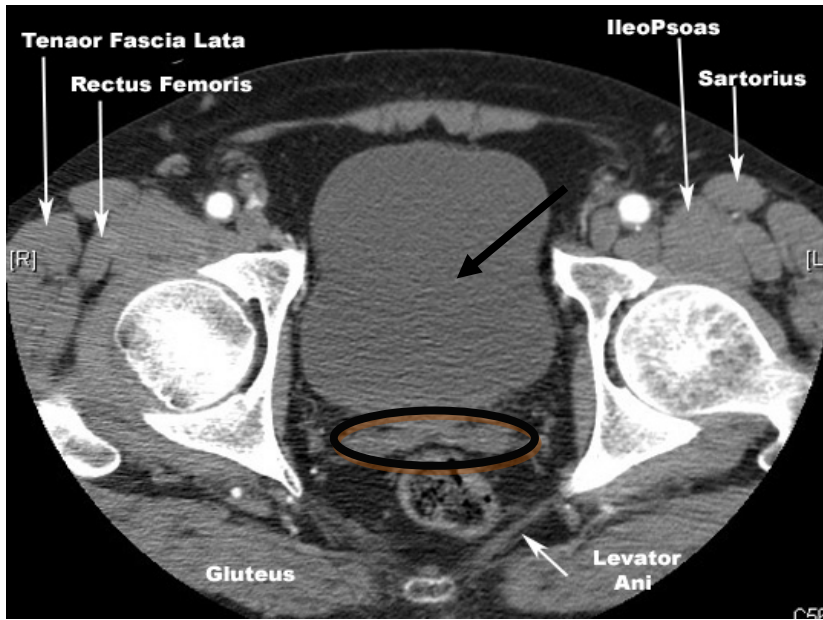
- Pelvis:
 - Female pelvis:
 - The most anterior structure is the urinary bladder; the structure has a fluid like density with a thin wall
 - The uterus:
 - It is located superior to the bladder
 - The cervix lies posterior to the bladder.
 - The uterus appears as a hyperdense structure with a small triangular hypodensity marking the endometrial cavity)
 - The ovaries are located on both sides of the uterus in a nulliparous woman. However, in a multiparous woman, the location of the ovaries might differ.
 - If a section shows the urinary bladder, the uterus, and the cervix; the cut is a very low cut.
 - The most posterior structure is the rectum, which lies anterior to the coccyx.
 - Male pelvis:
 - Urinary bladder most anterior structure
 - Rectum lies behind the urinary bladder
 - The prostate lies inferior to the urinary bladder
 - In a male, we can visualize the seminal vesicles; The seminal vesicles appear as cystic like structures (In the upper cuts, they have soft tissue density); they look like a moustache on CT scan.



Female pelvis CT scan showing the uterus, ovaries, and rectum. The endometrial cavity (black circle)
Coccyx (blue circle)

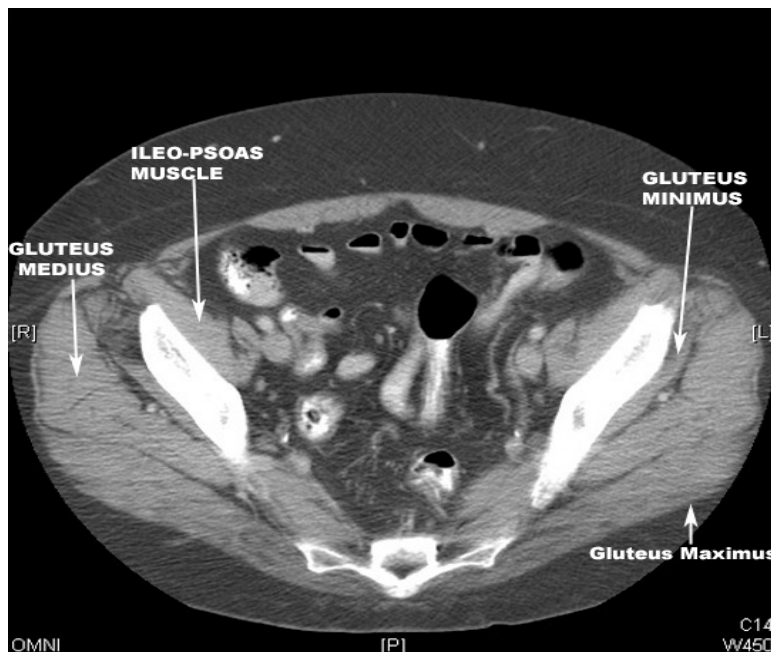


Female pelvis CT scan lower cut showing uterus, and cervix (Cx) and rectum (R)



Male pelvis CT scan showing the inferior surface of urinary bladder (black arrow) and prostate upper cut (black circle; moustache sign)

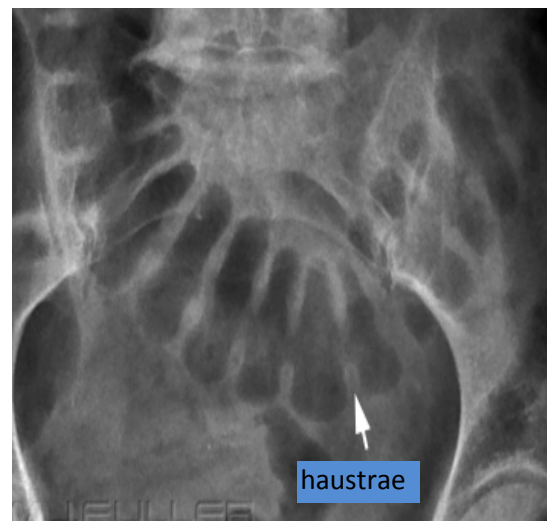
- Important pelvic muscles:
 - At the level of the femoral head, the iliacus and psoas become one muscle known as the iliopsoas muscle.
 - The gluteal muscles: (separated by fatty planes)
 - Gluteus maximus (outermost)
 - Gluteus medius
 - Gluteus minimus (innermost)
 - At the level of the obturator foramen, we find the obturatorinternus muscle
- Femoral artery and vein are located anterior to the head of femur (they appear as two adjacent rings)



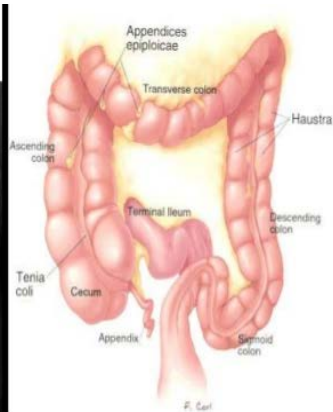
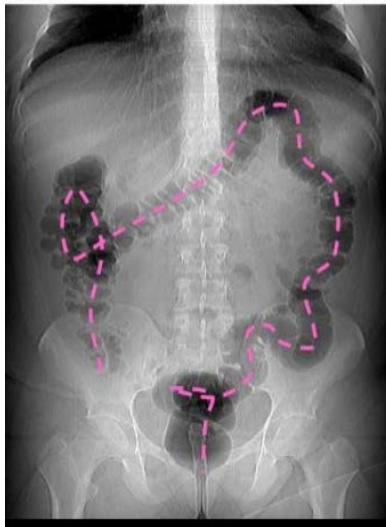
- Pathologies:
 - Plain films:
 - When we look at a plain film, we need to comment on the age, gender, name, and date of the image.
 - Unless otherwise indicated, abdominal X-rays are AP films. In some cases, we might require a supine, decubitus, or erect PA view.
 - On an X-ray, there are 5 main densities; however, we only care about 2 of them. Bone looks white, and gas looks black. Other structures and tissues have varying opacities.
 - Systematic interpretation of an X-ray:
 - Look at the gas distribution. The presence of a gas bubble below the diaphragm at the fundus on the stomach is normal. Gas can be present in the large bowel, especially along the transverse colon and rectum.
 - Then, look at the position of the intestinal loops (large and small intestines)
 - Then, look at the diameter of the loops to detect obstruction; the intestines will be dilated proximal to the obstruction and collapsed distal to the obstruction.
 - Differentiating between small and large bowel on an abdominal X-ray:
 - The large bowels are located peripherally while the small bowels are located centrally
 - The size of the bowel: we accept up to 3cm diameter of small intestines, 6cm for large intestines, and 9cm for the cecum
 - Content: the large bowel contains fecal material and air; the small bowel contain fluid (succusentericus)
 - Shape of wall: the large bowels have haustrations (the haustrations are separated by plicae semi-lunaris). Plicasemilunaris are circular smooth muscles that do not encircle the whole intestinal wall. The small intestines have a full ring of smooth muscles surrounding them. This ring is called valvulaeconneventis.

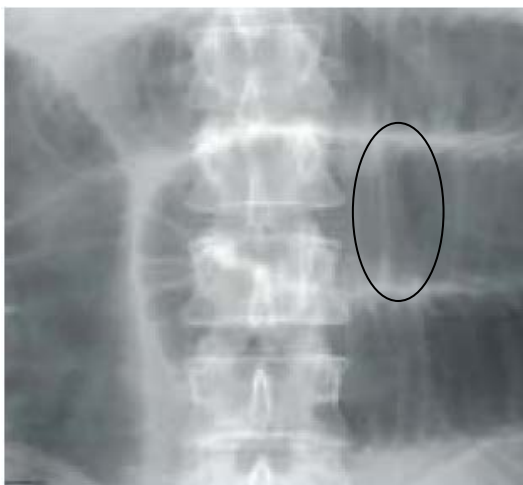

Figure 3. Valvulae conniventes



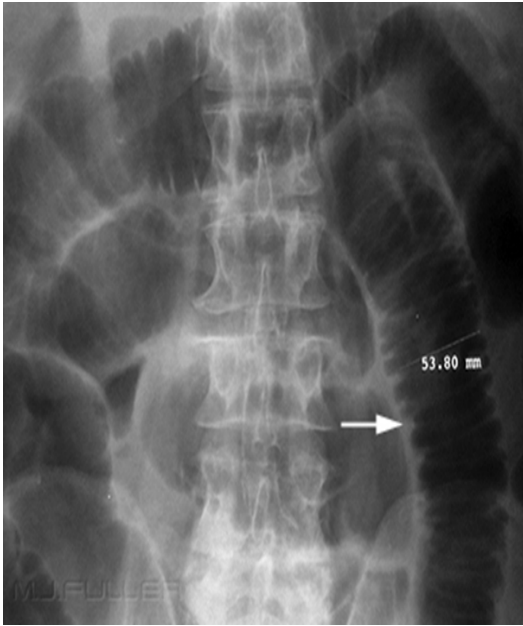
Small vs. Large Intestine



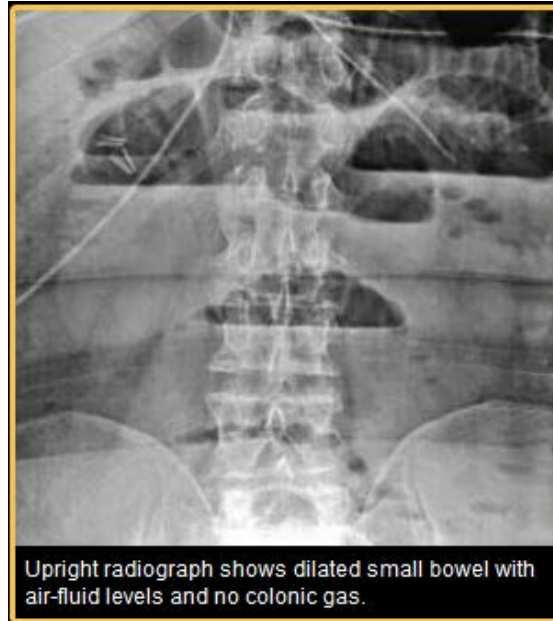- *Colon has sacculations called hastra as teniae coli are shorter than the colonic wall*
- *Colon is relatively peripheral but can be very mobile*

- On plain films, we can detect two broad types of pathologies:
 - Gas pathologies
 - Calcification pathologies
- Gas pathologies:
 - Intraluminal (can be pathological or normal); features of pathology:
 - Dilated bowels
 - Multiple air fluid levels
 - Transition zone (proximal dilation; distal collapse)
 - Extraluminal (always pathological)
 - Intraperitoneal (pneumoperitoneum)
 - Intra-biliary
 - Gas in the portal veins
- Calcification pathologies:
 - Appendicolith
 - Phlebolith
 - Vascular calcification
 - Gallbladder stones
 - Renal stones
 - Calcified adrenals
- Bowel obstruction:
 - Bowel obstruction is a type of intraluminal gas pathology
 - The features of the pathology are as follows:

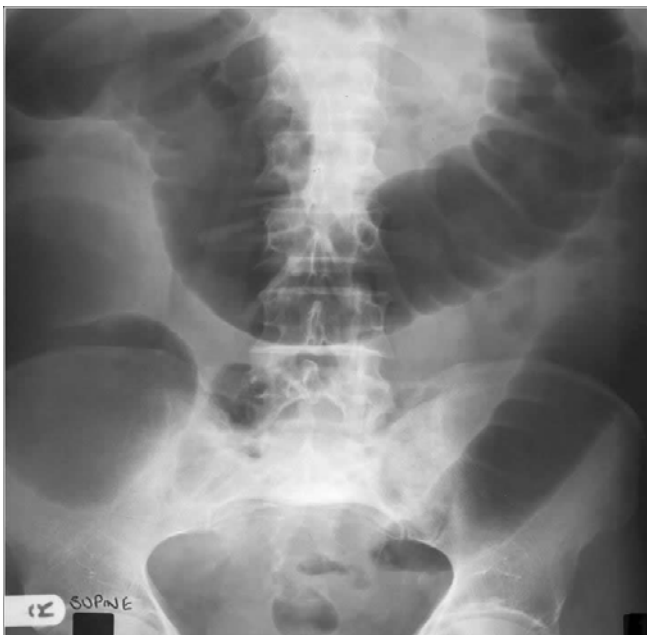- Dilation of the intestinal loops (>3cm in small intestines, >6cm in large intestines, >9cm cecum)
- Multiple air fluid levels:
 - 2 air fluid levels measuring more than 5 cm (2-5 rule)
 - 5 air-fluid levels measuring more than 2 cm each (5-2 rule)
- Presence of a transitional zone: dilation proximal to the obstruction and collapse distal to obstruction.



Small bowel dilation



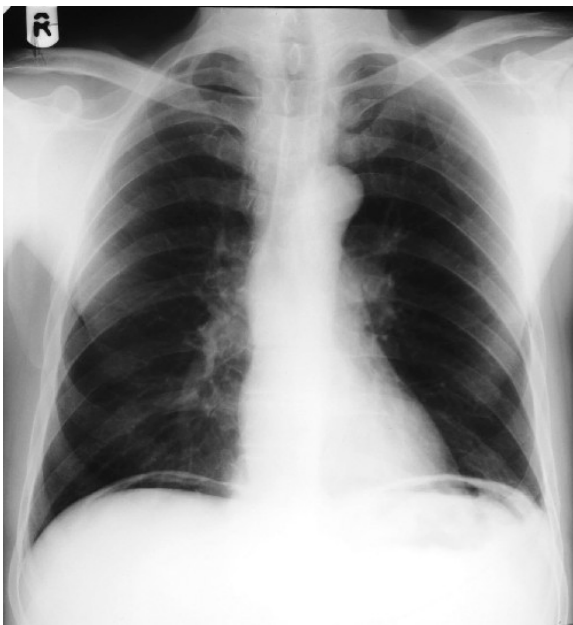
Upright radiograph shows dilated small bowel with air-fluid levels and no colonic gas.



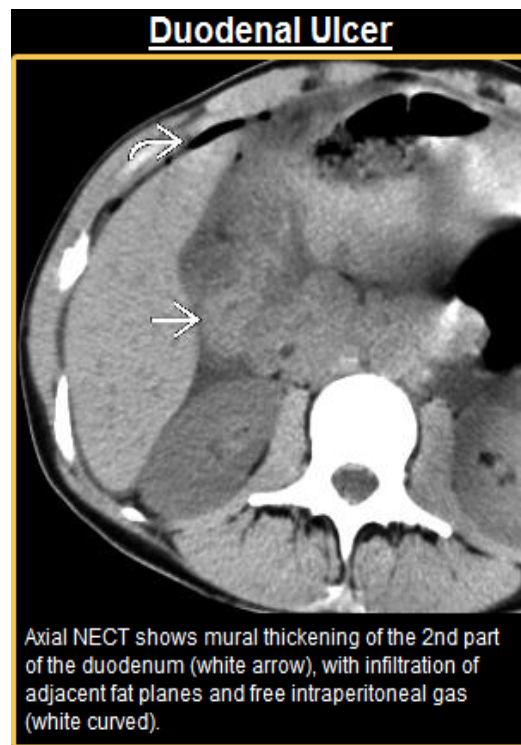
Large bowel obstruction with dilation

- Pneumoperitoneum :

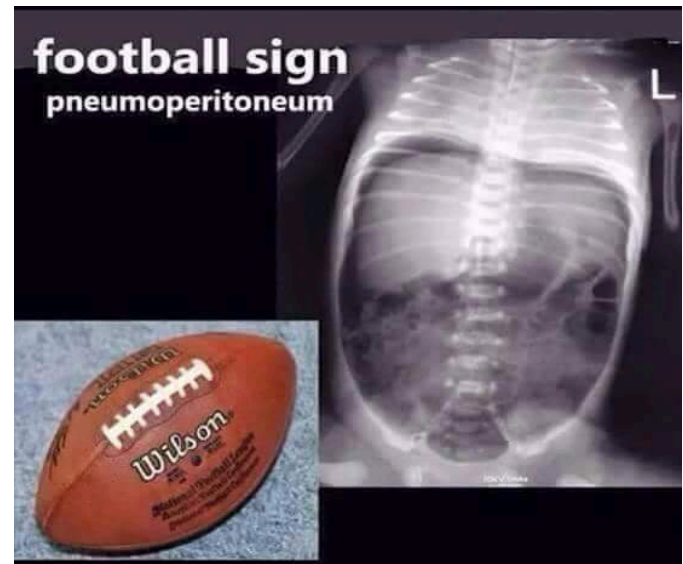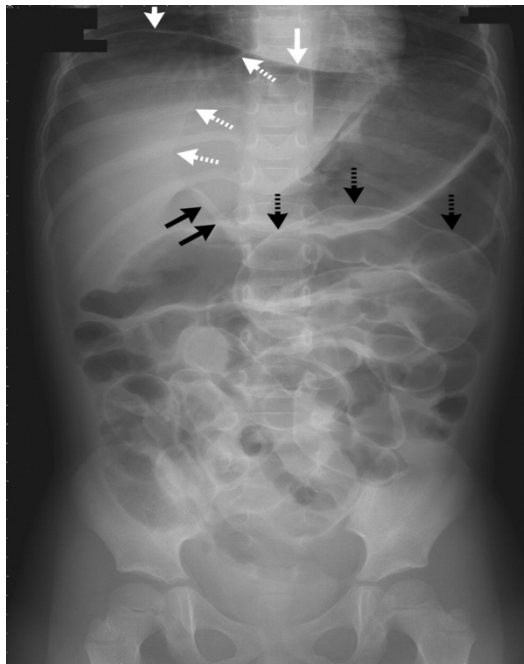
- One of the subtypes of extraluminal gas pathologies. The presence of gas in the peritoneum due to rupture of a viscus ex. In a case of a ruptured peptic ulcer.
- Gas in the peritoneum usually gathers under the right diaphragm. It will be apparent as a black discoloration below the diaphragmatic muscle on the right side of the X-ray
- The presence of peritoneal gas is normal up to 7 days post laportomy
- On a CT scan, a duodenal ulcer will appear as "dirty fat planes" with surrounding edema.
- If we cannot get a proper AP X-ray, a supine X-ray can be used. On the supine X-ray we have 3 signs:
 - Falsiform ligament sign: due to the presence of free air under the diaphragm, the ligaments will appear whiter
 - Ligamentumteres sign: same principle
 - Riglers sign: due to the presence of intra-peritoneal gas, we will be able to see the intestinal walls clearly. The presence of gas inside and outside the intestines will demarcate the borders of the intestinal walls clearly.
- Pediatrics supine X-ray sign of intraperitoneal gas:
 - Football sign: the abdomen looks distended and black. The spine looks whiter (more radio-opaque) than usual due to the presence of gas.



Gas under the diaphragm on the right side



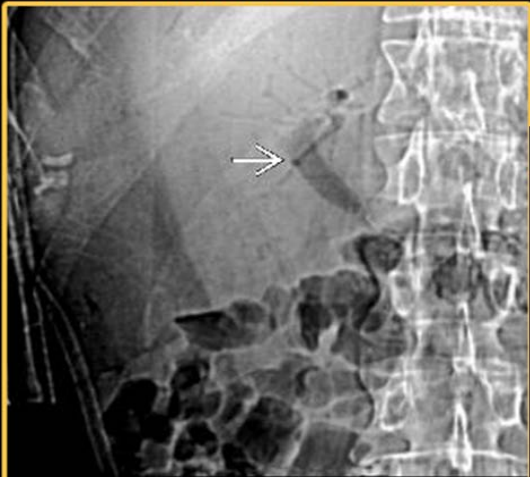
Axial NECT shows mural thickening of the 2nd part of the duodenum (white arrow), with infiltration of adjacent fat planes and free intraperitoneal gas (white curved).



Abdominal X-ray showing gas in the subphrenic area (white solid arrow), falsiform ligament sign (dashed white arrows), ligamentum teres sign (solid black arrow), visible intestinal wall (dashed black arrow)

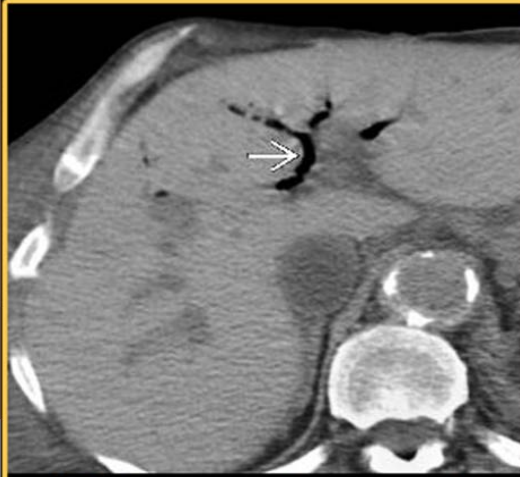- Gas in the biliary tree (pneumobilia) and gas in the portal veins:
 - o Presence of gas in portal veins is always pathological and indicates an ischemic condition like toxic megacolon or ischemic colitis. It is usually accompanied by the presence of intra-mural gas.
 - o The presence of gas in the biliary tree can be normal or pathological:
 - Recent surgery
 - Post-ERCP
 - Gallbladder stones with gallstone ileus
 - Indicates the presence of a fistula between the gallbladder and gut
 - o How to differentiate between gas in the biliary tree and gas in the portal veins?
 - On a CT scan, look for gas on the periphery of the liver. The presence of gas on the periphery of the liver indicates gas in the portal veins.

Biliary-Enteric Anastomosis



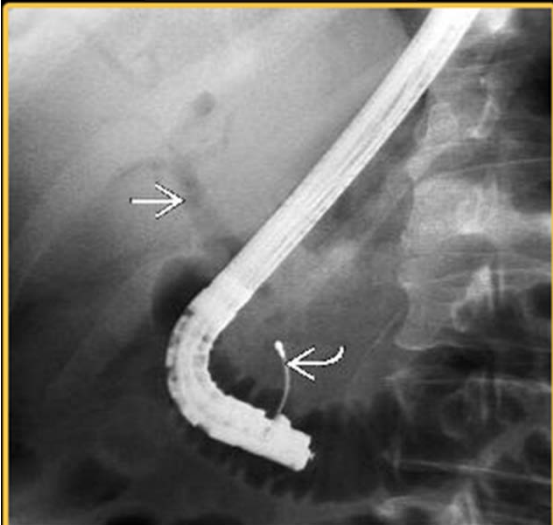
Frontal radiograph shows classic radiographic appearance of pneumobilia with a branching gas pattern (white arrow) limited to the porta hepatis. Small bowel and liver transplantation.

Biliary-Enteric Anastomosis

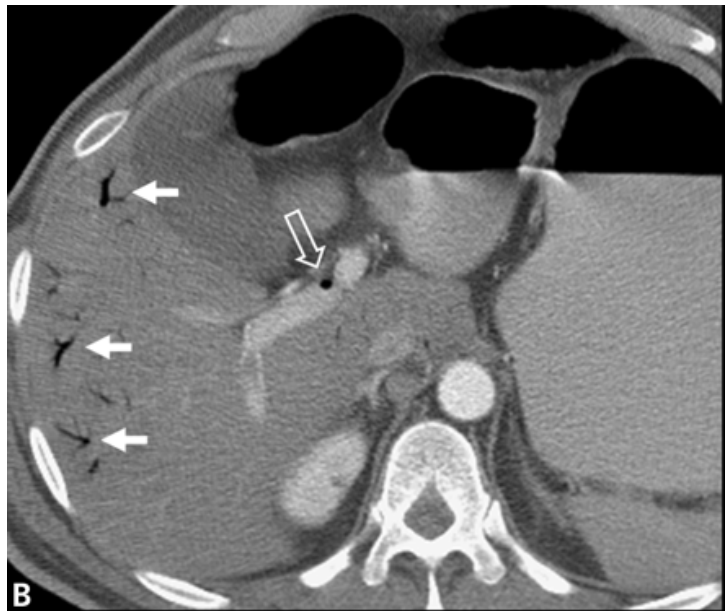


Axial NECT shows pneumobilia (white arrow) in a patient who had biliary-enteric anastomosis as part of a liver & small bowel transplantation.

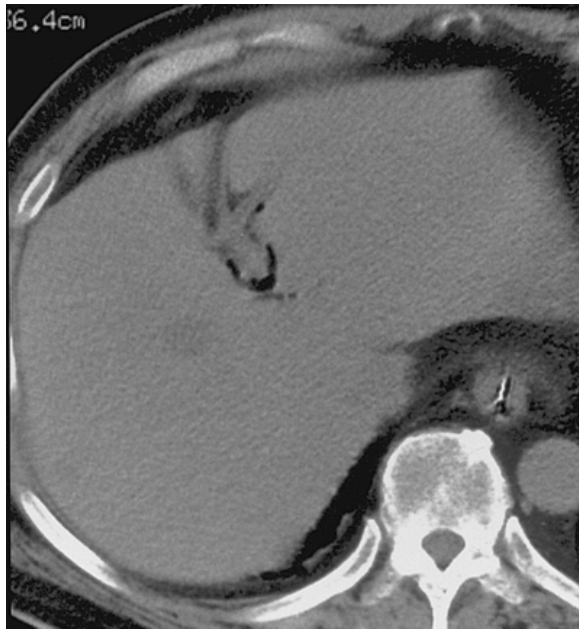Sphincterotomy



Oblique ERCP shows gas in the bile ducts (white arrow) and the endoscope with a sphincterotomy device (white curved) in place.



Abdominal CT scan showing gas in the portal vein; notice the gas at the periphery of the liver (white solid arrows)

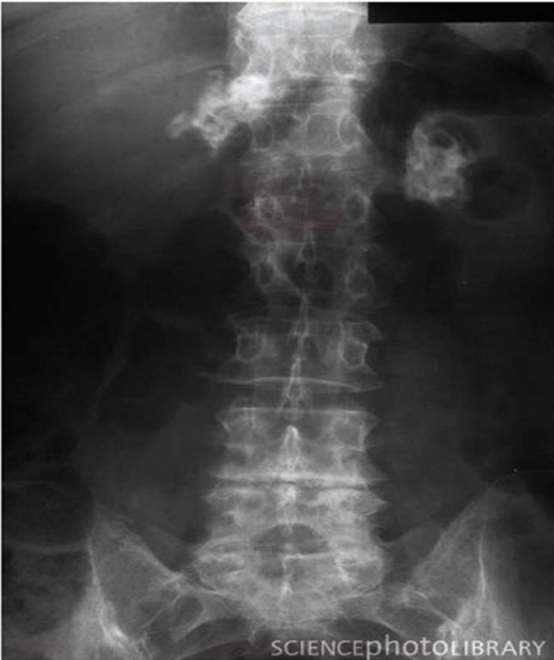

Abdominal CT showing gas in the biliary tree (the crescent shaped hypodense area). Notice that there is no gas at the periphery of the liver.

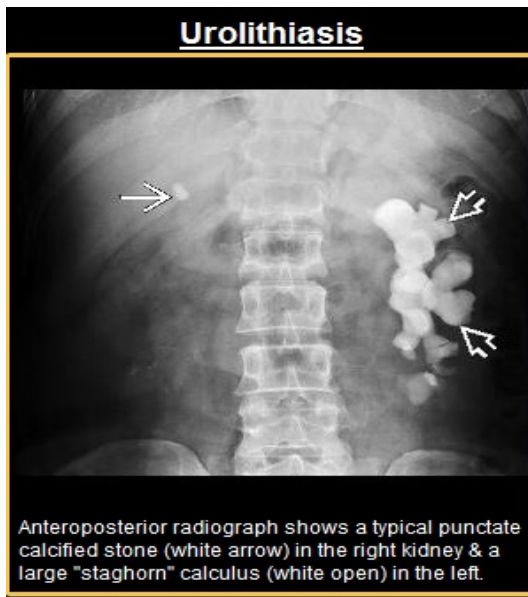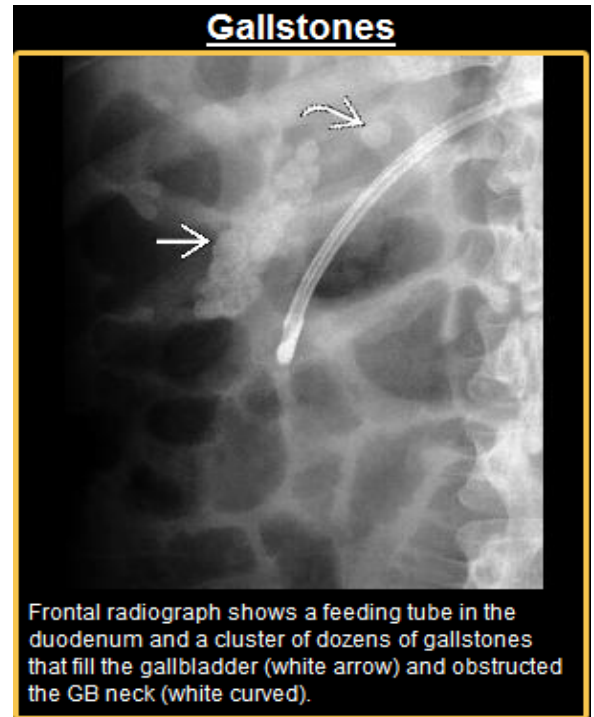
- Abdominal Calcifications:

- Appear as radio-opaque substances on the abdominal film.
- To define the type of pathology, we locate its anatomical site.
- Types of pathologies:
 - pelvic vein phleboliths (calcified thrombi): mostly 5mm or less with a central radio-lucent area present in the pelvic area. Usually multiple and small and found above symphysis pubis
 - vascular calcification:
 - Calcification present in walls of aortic aneurysm
 - Ring calcification may involve splenic & renal arteries
 - Calcified lymph nodes:
 - Mostly from granulomatous disease
 - Mesenteric lymph nodes are the most commonly calcified
 - Gallstone & gall bladder.
 - gallstone 15 % radio-opaque
 - calcification in the gall-bladder wall (porcelain GB)
 - Urinary tract calcifications (stones)
 - 85% radio-opaque
 - Renal calculi are differentiated from gallstones by oblique projections that confirm their posterior position (more ant. For G.B.S)
 - Urinary bladder calculi usually lie near the midline of the pelvis.
 - liver & spleen granulomas: healed foci of T.B , histoplasmosis
 - Appendicoliths & enteroliths: most are round or oval & have concentric laminations

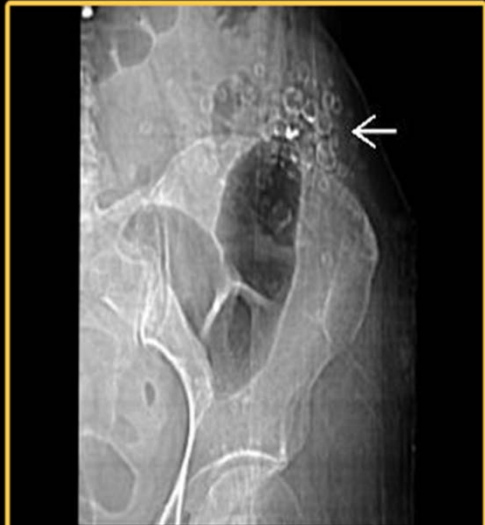- Calcified adrenal glands: associated with adrenal hemorrhage , T.B., and Addison's disease.
- Pancreatic calcifications
 - Chronic pancreatitis
 - Hereditary pancreatitis
- calcified cysts: echinococcus (hydatiform cysts)
- Tumor calcification
 - Uterine leiomyomas (coarse or popcorns)
 - Benign cystic teratomas (teeth)
- Soft tissue calcifications:
 - Old hematomas
 - Calcification in buttocks may be seen following injection certain medications



Addison's disease, X-ray

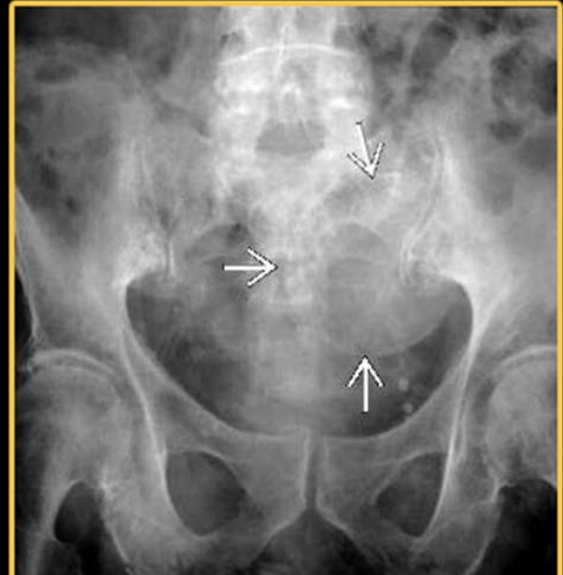

Abdominal Incision & Injection Sites

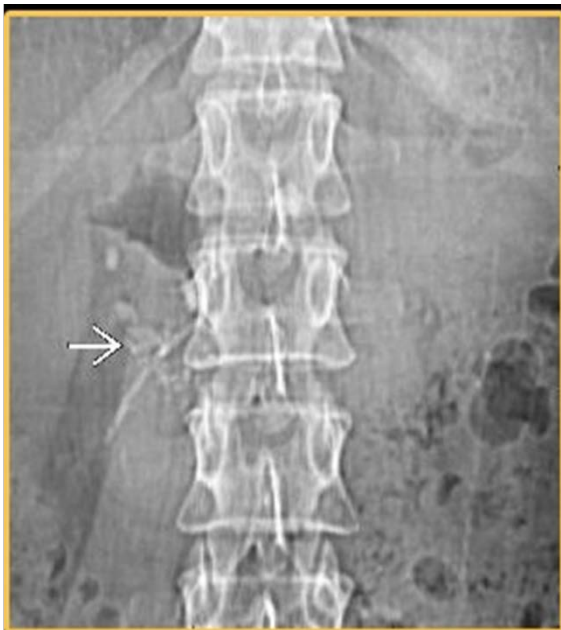

Frontal radiograph shows a cluster of calcified injection granulomas (white arrow) overlying the lower abdomen, but located within the subcutaneous fat of the buttocks.

Arterial Calcification and Aneurysm

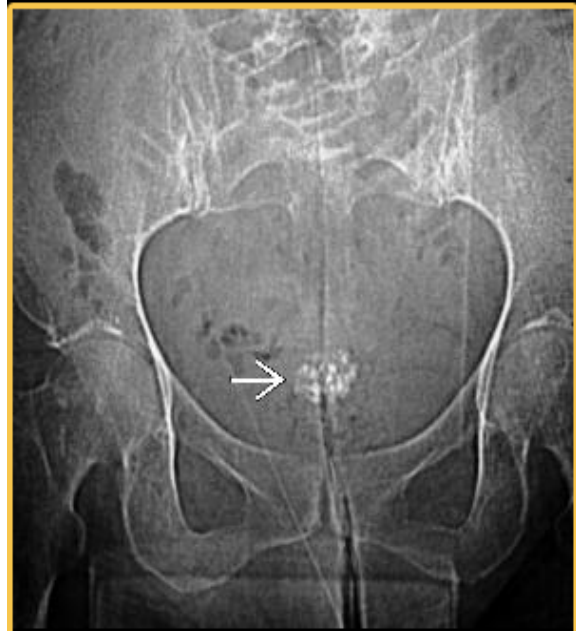

Frontal radiograph shows a spherical eggshell calcification (white arrow) in the pelvis; large common iliac artery aneurysm.



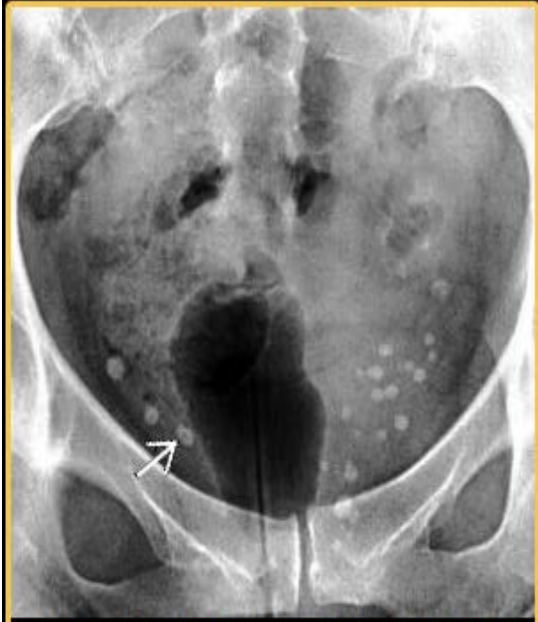Plain radiography (#1) shows a cluster of calcifications (arrow) in the head of the pancreas.

Uterine Leiomyoma (Fibroid)



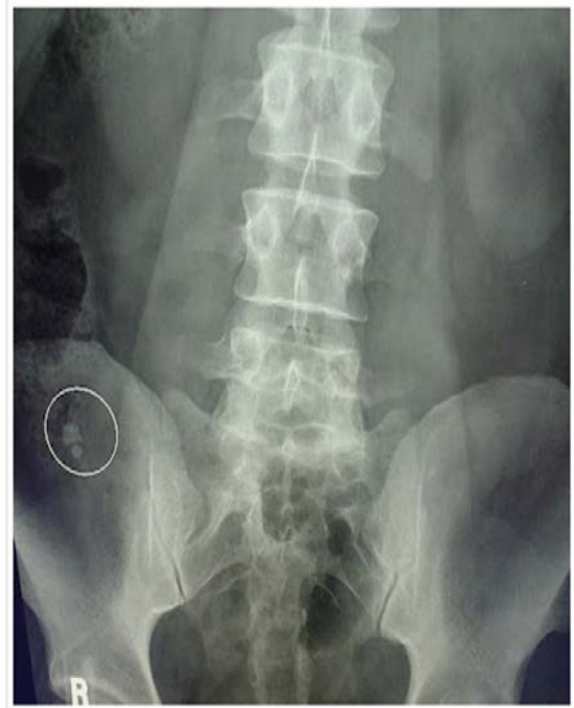Frontal radiograph shows a small pelvic "popcorn" type calcification (white arrow), one of the common forms of calcification in a degenerated uterine fibroid (leiomyoma).

Phleboliths



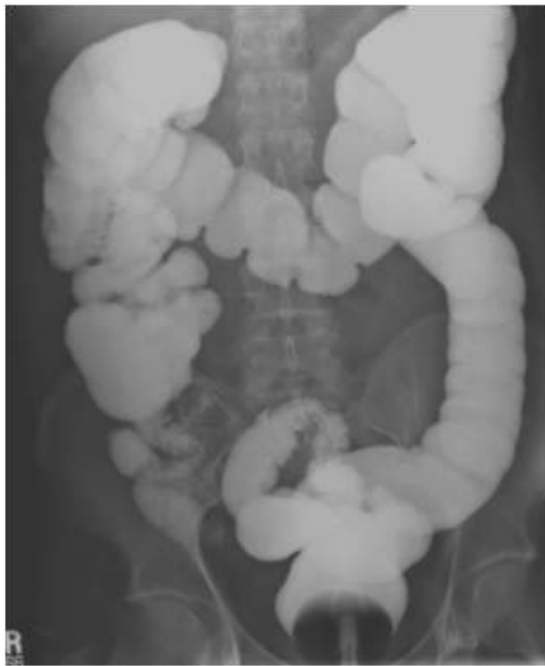Frontal radiograph shows multiple phleboliths in the pelvis, having their typical distribution, mainly below the iliac spines, some with central lucency (white arrow).

Appendicolith

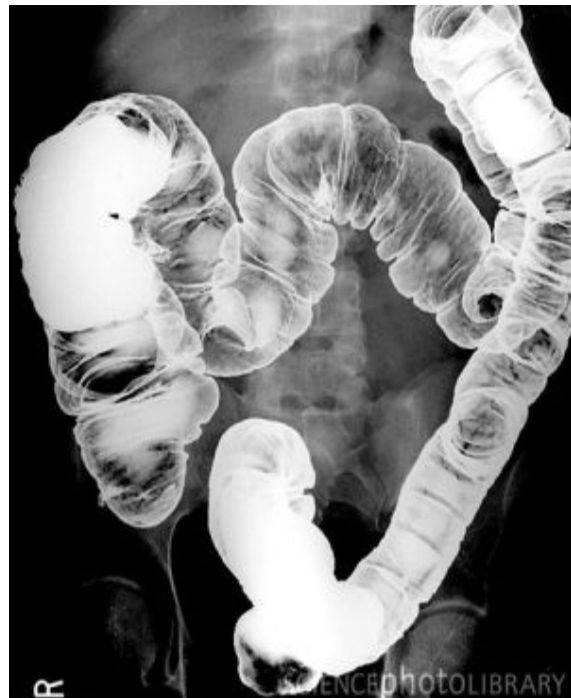

- Filling defect/ulceration/stricture:
 - To detect these pathologies, we mostly use fluoroscopy . Fluoroscopy is a type of X-ray imaging that takes multiple images and records the movement of the contrast material in a video-like fashion.
 - Types of contrast material: A contrast material is a material used to accentuate certain anatomical features that cannot be visualized without the use of such materials.
 - Iodinated contrast materials:
 - Low osmolar weight materials
 - There are ionic and non-ionic types; nowadays, we use non-ionized forms of iodine materials
 - They can be used in cases of suspected perforation.
 - Disadvantages:
 - Expensive
 - Can cause contrast induced nephropathy, so they are contraindicated in cases of renal failure
 - High risk for anaphylactic reactions.
 - Barium sulfate:
 - The most commonly used contrast material in the GIT
 - It has a high osmolar weight
 - It is contraindicated in cases of suspected perforation

- Advantages:
 - Excellent opacification
 - Good coating for the mucosa
 - Completely inert (rarely causes anaphylactic reactions)
 - Inexpensive
- Types of contrast studies:
 - Single contrast technique: here, we inject the contrast material and then take the image.
 - Double contrast technique: here, we inject the contrast material, then we inject air. After that, we take the image. Injecting air will distend the lumen and this will help us visualize the mucosa better. Usually used in adults; pediatric patients rarely have mucosal abnormalities.



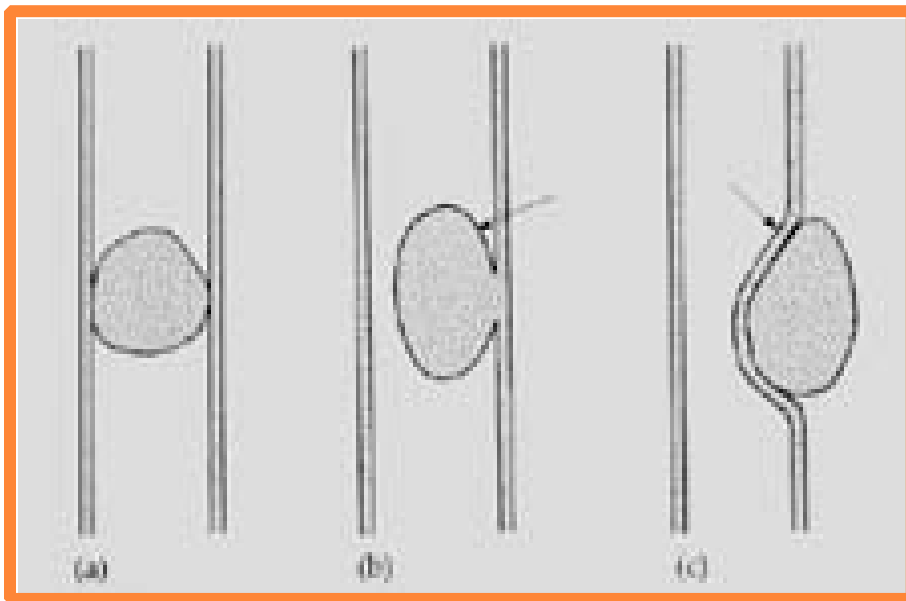
Abdominal X-ray with single contrast



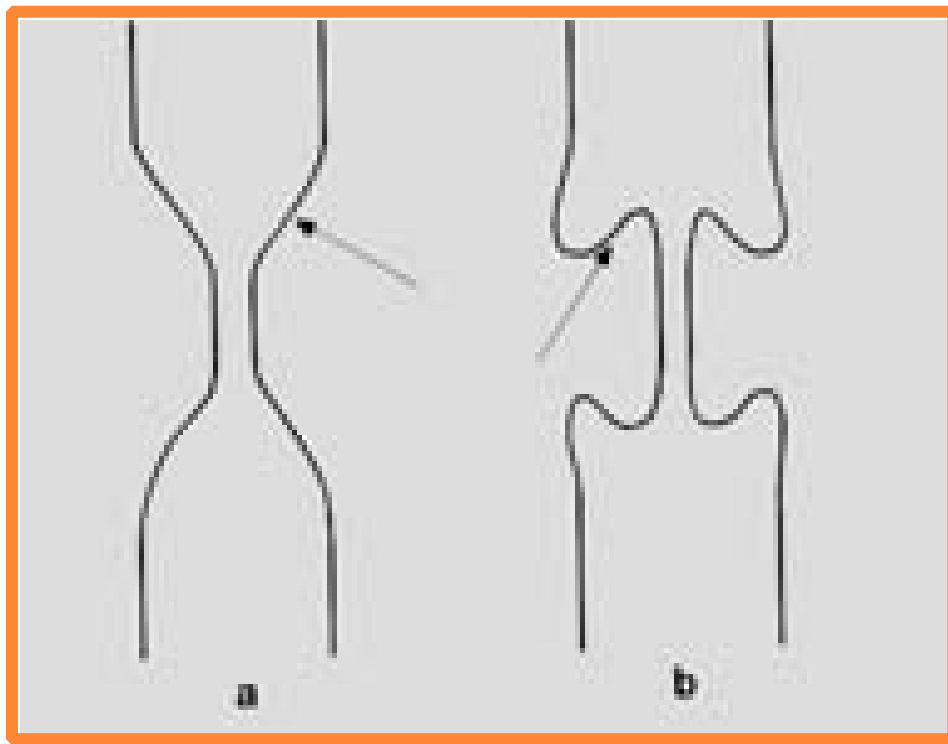
Abdominal X-ray with double contrast

- Filling defects:
 - A filling defect can be defined as an area that does not take contrast as it should normally do.
 - Classified into:
 - Intraluminal defect (gallstone ileus, or foreign body)

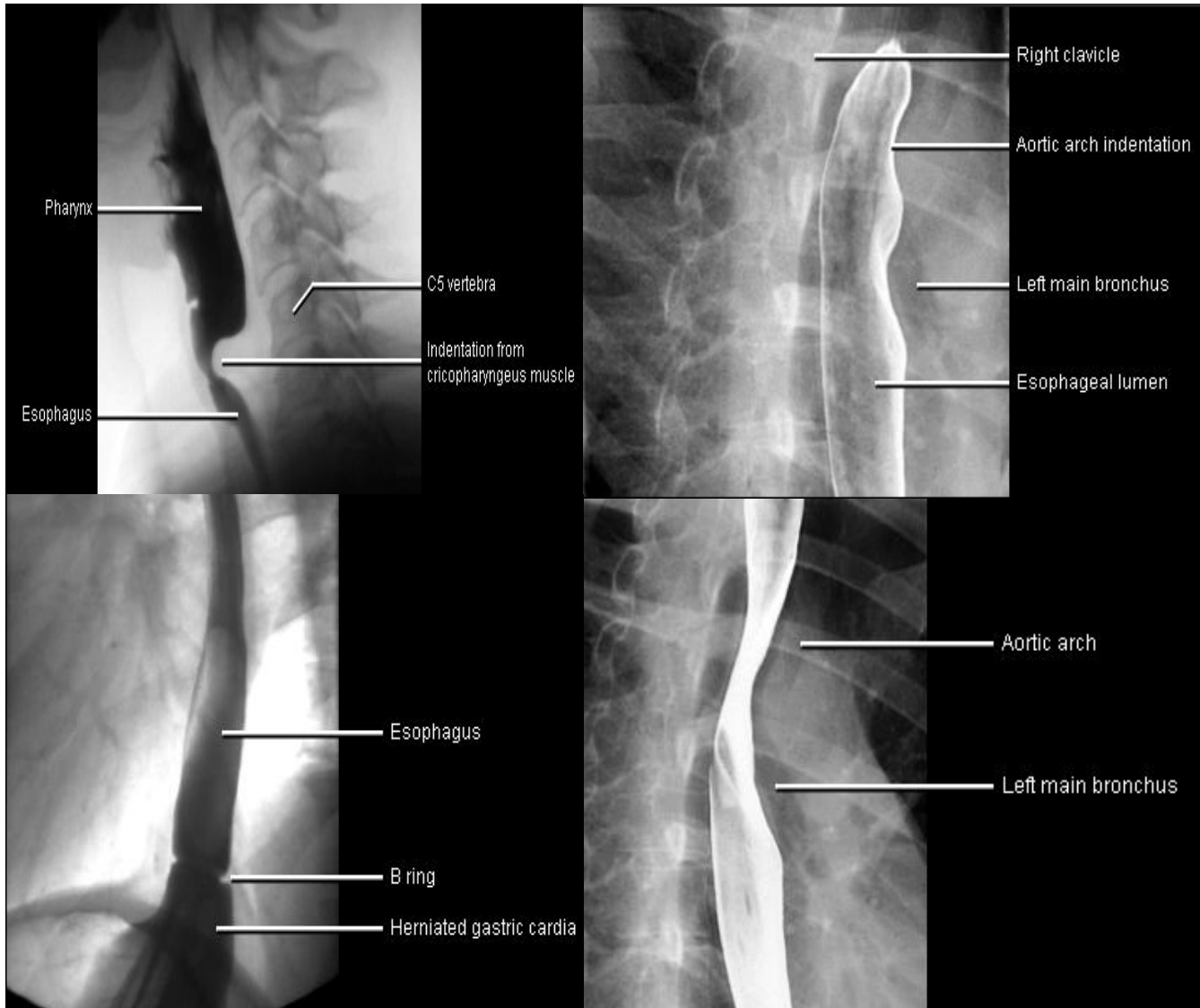
- Intramural defect: a pathology inside the wall extending into the lumen
 - Extramural: an external pathology decreasing the lumen's size.
- How to differentiate among types of filling defects?
- Intraluminal defects (a): the contrast forms an acute angle on both sides of the lesion ex. Food particles or stones
 - Intramural defects (b): the contrast forms an acute angle on one side of the lesion: ex carcinoma, leiomyoma, diverticulum, or polyp
 - Extramural defects (c): the contrast forms one obtuse angle at the site of the lesion: ex enlarged lymph nodes



- Strictures:
- A stricture is defined as narrowing of the lumen at a site other than a normal site of narrowing (an example of a normal stricture is the denture of the cricopharyngeal muscle in the esophagus)
 - Strictures can be divided into benign and malignant strictures:
 - Benign stricture (a): gradual tapering, regular, absence of malignant features (apple-core appearance). Ex achalasia
 - Malignant strictures (b): abrupt transition from normal lumen size to narrowed lumen size. This is referred to as shouldering. Bilateral shouldering is a sign of malignancy; however, unilateral shouldering can be seen with a benign stricture. Ex carcinoma



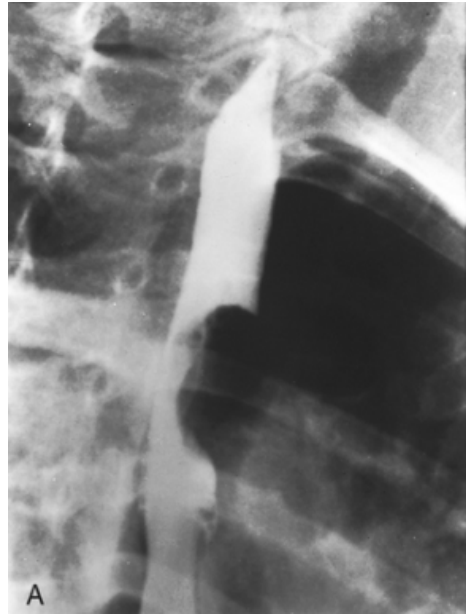
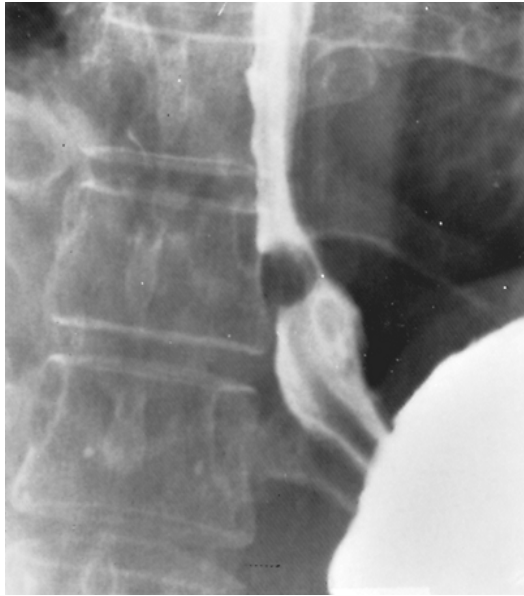- Ulcerations:
 - An ulceration is defined as a breach in the mucosal surface. Think of it as a depression on the mucosal surface. The presence of this depression will cause more barium to accumulate at the site of ulceration.
 - Classified into:
 - Benign
 - Malignant
- Esophagus:
 - The esophagus is a long muscular tube. On a plain X-ray, we can rarely see the esophagus. It can be seen only in cases of severe dilation (achalasia) represented as widening of the mediastinum.
 - The study of choice for an esophageal pathology is a barium swallow. The barium swallow delineates the anatomy of the esophagus and shows the exact site of pathology. Depending on the location of the stricture and features of the stricture, we can determine the pathology
 - Physiological esophageal constrictions:
 - Cricopharyngeus muscle (upper esophageal sphincter) on the posterior aspect of cervical esophagus.
 - By arch of aorta (left anterolateral surface of esophagus)
 - By left main bronchus
 - By diaphragm



4 contrasted esophageal X-rays showing the physiological impressions (constrictions) of the esophagus

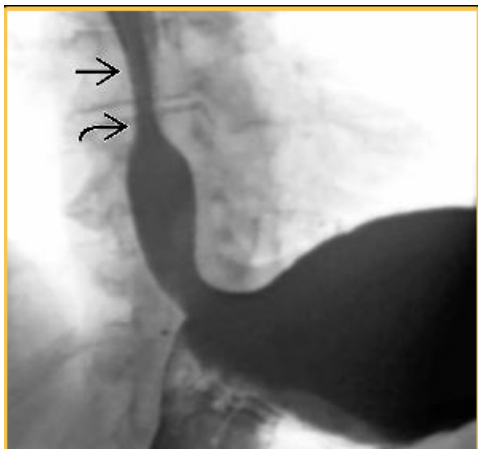- Pathologies:
 - Filling defects:
 - Intramural:
 - Leiomyoma - smooth, rounded indentation into the lumen of oesophagus
 - Carcinoma cause an irregular filling defect, but usually present as stricture
 - Extramural:
 - Carcinoma of the bronchus
 - Enlarged mediastinal lymph node

- Aneurysm of aorta

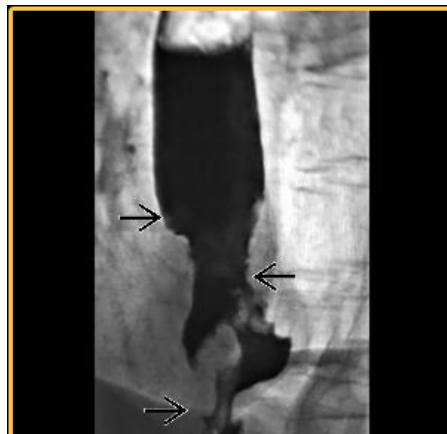

Two esophageal X-rays showing an intramural filling defect (the radiolucent lesion)

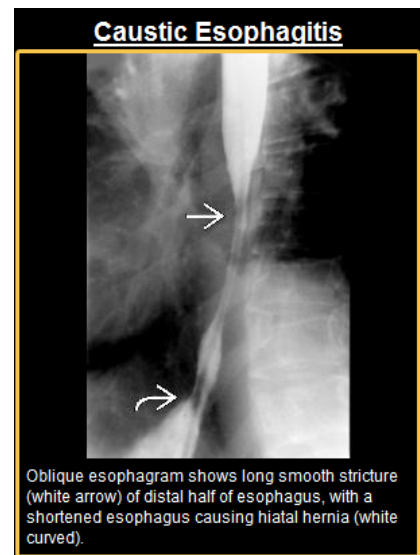
- Strictures:
 - Benign:
 - Gradual tapering, no shouldering
 - Causes:
 - Achalasia
 - GERD/esophagitis.
 - Corrosive ulcers (caustic ingestion)
 - Malignant:
 - Abrupt transition, shouldering, apple-core appearance
 - Causes: malignancies



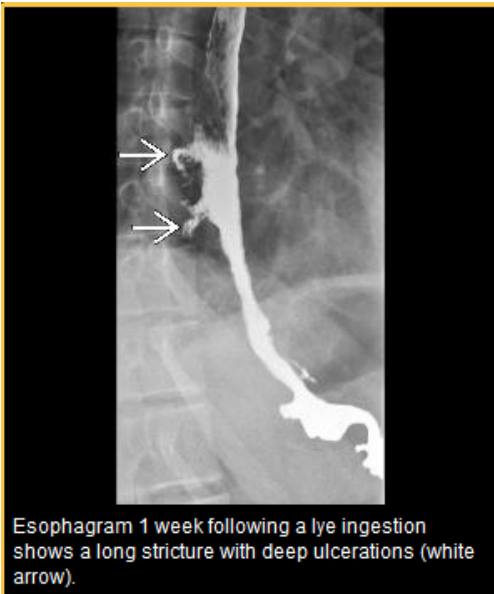A supine spot film from a barium esophagram demonstrates free and repeated reflux (black arrow) and a stricture at the gastroesophageal junction (black curved). Tertiary contractions and diminished primary peristalsis were also noted during fluoroscopy.



Esophagram shows an "apple core" constricting lesion (black arrow) of the distal esophagus. There is an abrupt transition, or shoulder, at the proximal end of the tumor as it abuts normal esophagus. The mucosa through the tumor is destroyed with nodular contours.

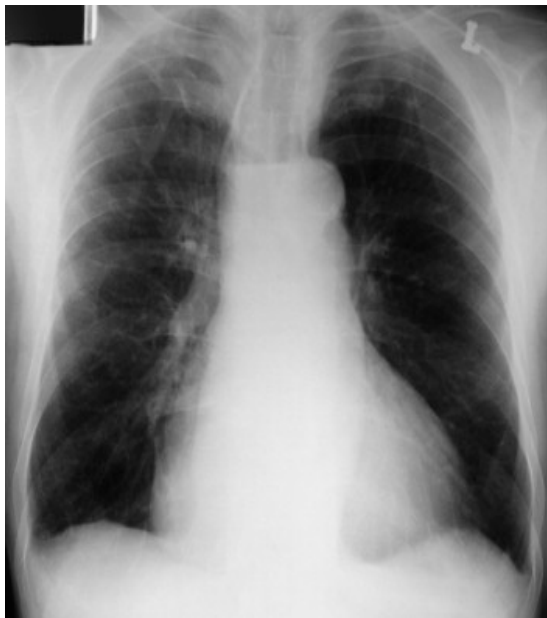

Caustic Esophagitis
Oblique esophagram shows long smooth stricture (white arrow) of distal half of esophagus, with a shortened esophagus causing hiatal hernia (white curved).

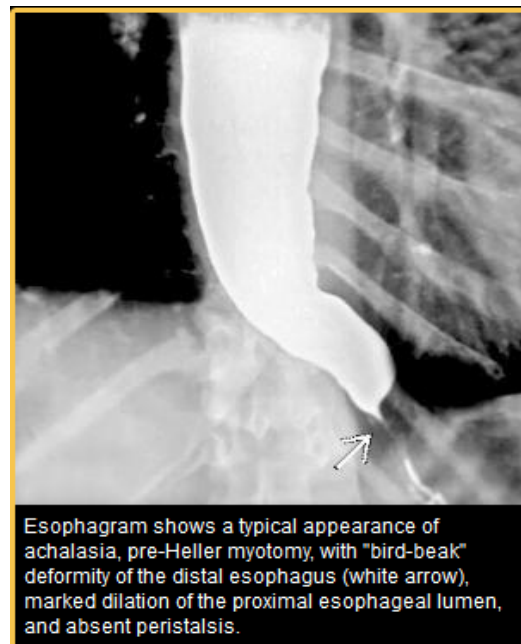


Here, you can see unilateral shouldering. This shouldering is not malignant. Here, the caustic agent eroded into the wall which caused an ulcer-like lesion (extra filling)

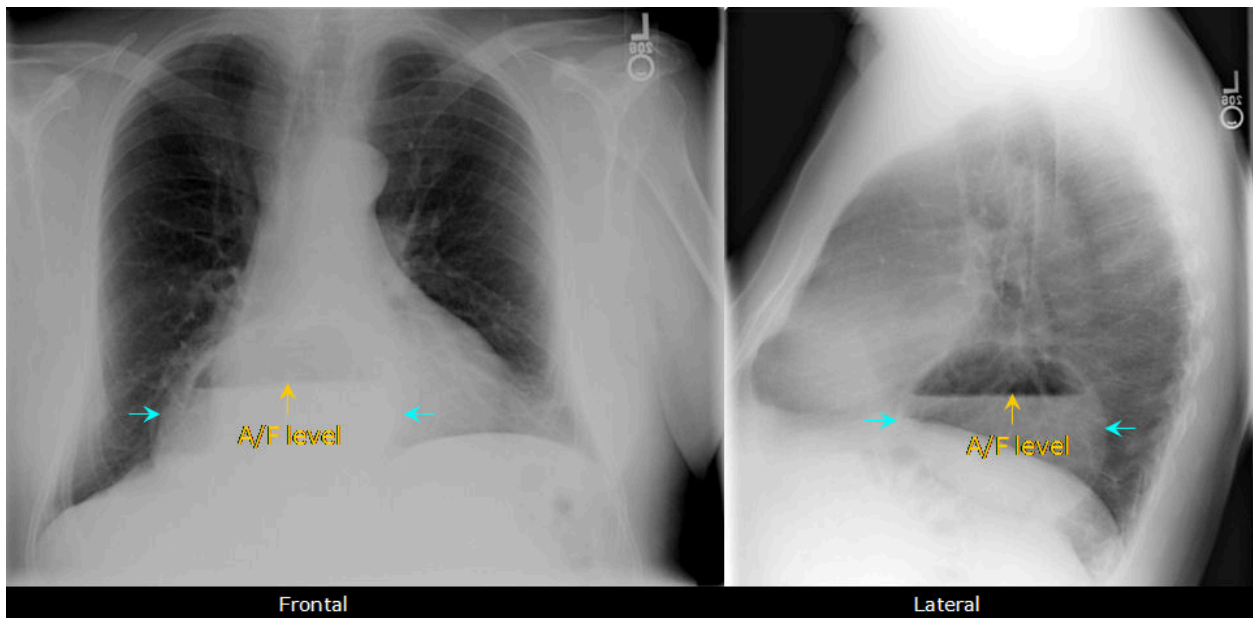
- Achalasia:
 - One of the esophageal pathologies. It is characterized by loss of relaxation of the LES due to loss of action of inhibitory neurons. This leads to proximal dilation in the esophagus. The esophagus loses its peristaltic ability.
 - On a plain film, we might see an air fluid level with widening of the mediastinum
 - A barium swallow shows the typical Rat-tail or bird-beak sign (funneling of the esophagus)



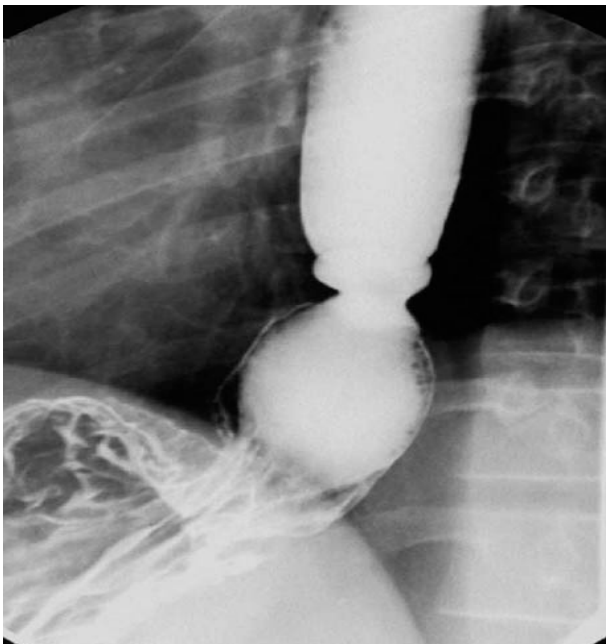PA chest X-ray showing widened mediastinum, dilated esophagus, and air fluid level.



- Hernia:
 - Herniation of the stomach into the mediastinum through the oesophageal hiatus in the diaphragm
 - 2 general types
 - Sliding (axial) hiatal hernia, most common: Gastroesophageal (GE) junction and gastric cardia pass through esophageal hiatus of diaphragm into thorax
 - Paraesophageal (rolling) hernia rare: gastric fundus ± other parts of stomach herniate into chest while **GEJ in normal position**.
 - To diagnose a hernia, we need a barium meal. A barium meal reaches the stomach and the first part of the duodenum.

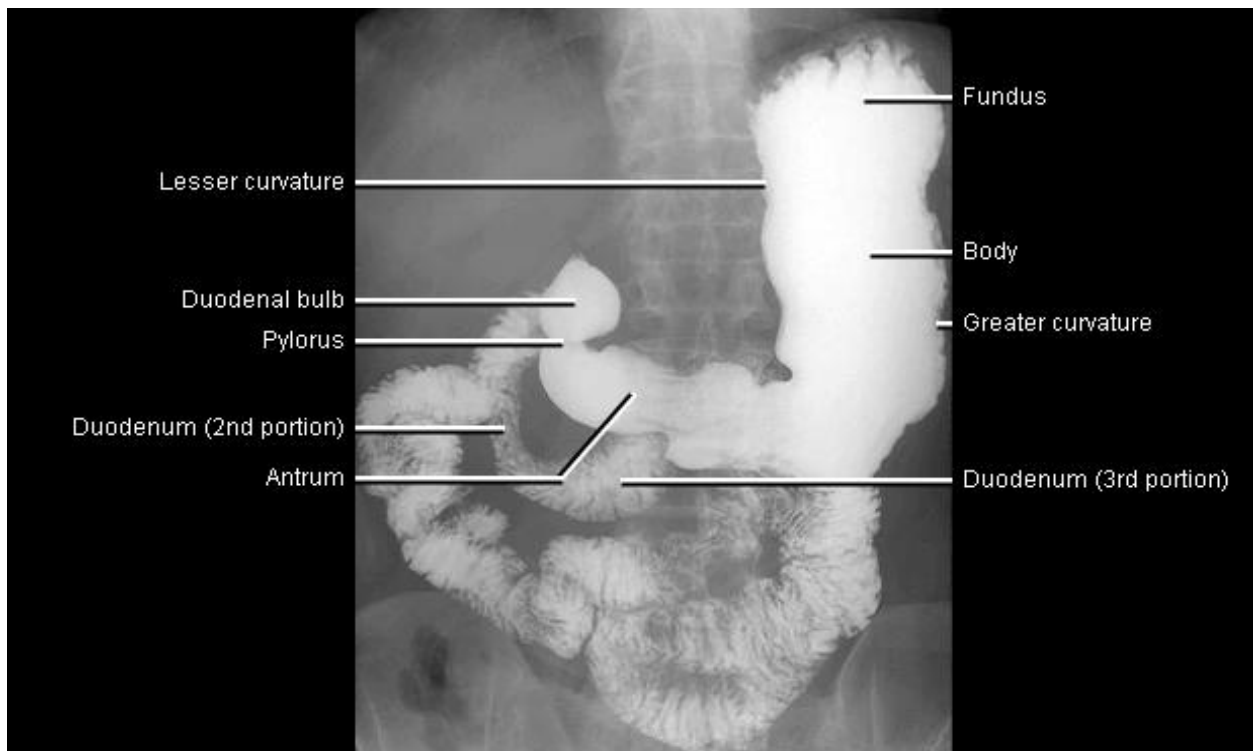


Conventional X-ray showing sliding diaphragmatic hernia.

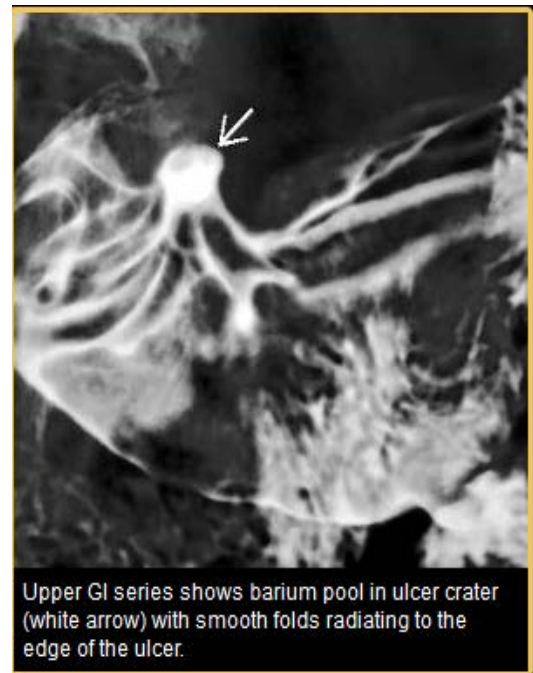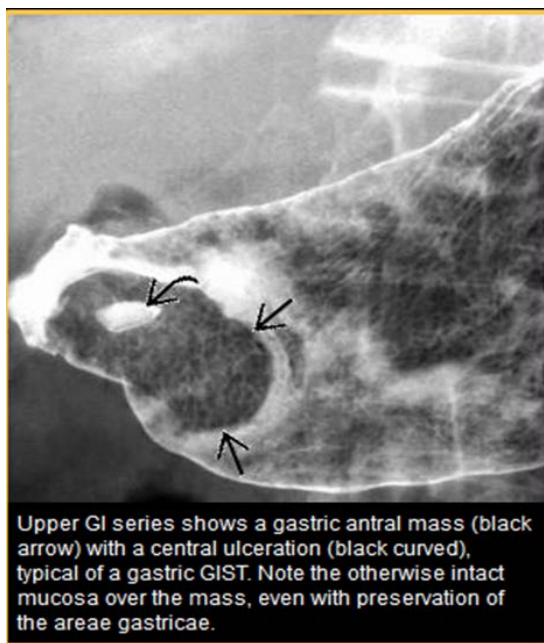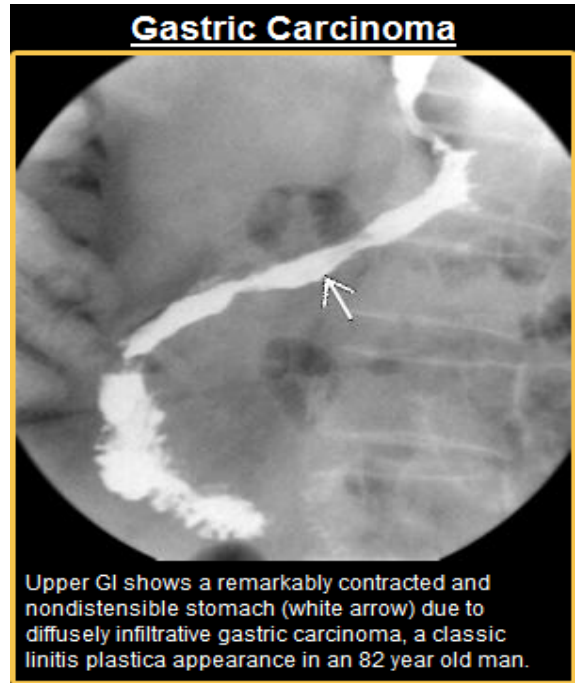


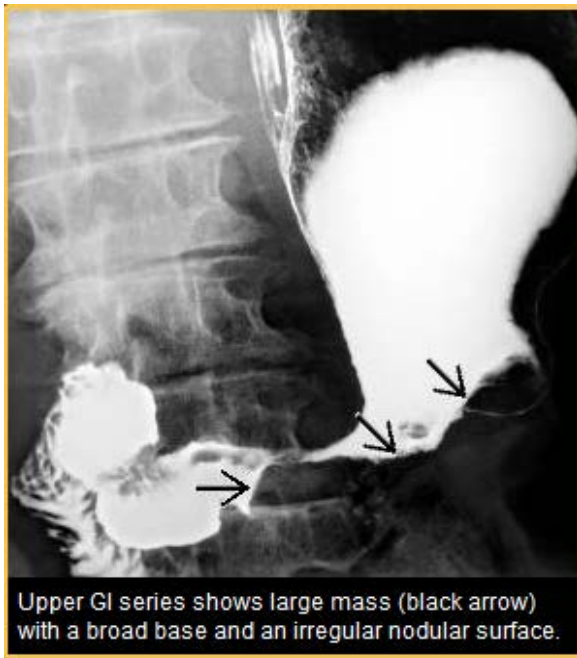Barium meal contrasted X-ray showing a sliding hernia

- Stomach and duodenum:
 - o To study the stomach and the first part of the duodenum, we use a barium meal.
 - o The stomach looks regular. The lesser curvature has a smooth surface. The greater curvature is usually irregular due to the presence of large amounts of rugae.
 - o There is a physiological constriction at the level of the pyloric sphincter.
 - o The duodenum forms a C-shaped loop around the head of pancreas
 - o The duodenum has a triangular shaped structure called the duodenal cap.
 - o Pathologies:
 - Filling defects:
 - Benign filling defects are usually regular in shape
 - Malignant filling defects are irregular. Sometimes, if the malignancy is diffuse, the stomach appears narrow and rigid. This is known as lentsplastica
 - Gastric polyps cause small intramural filling defects
 - Ulcers: (for a detailed discussion look at slide 107)
 - Benign: the ulcers can extend beyond the wall of the lumen and have speculations. The speculations indicate that the mucosal architecture of the stomach is intact
 - Malignant: usually found inside a region of a filling defect. They do not have speculations and they have irregular edges.
 - So, a filling defect with an ulcer inside the lesion indicates gastric carcinoma.



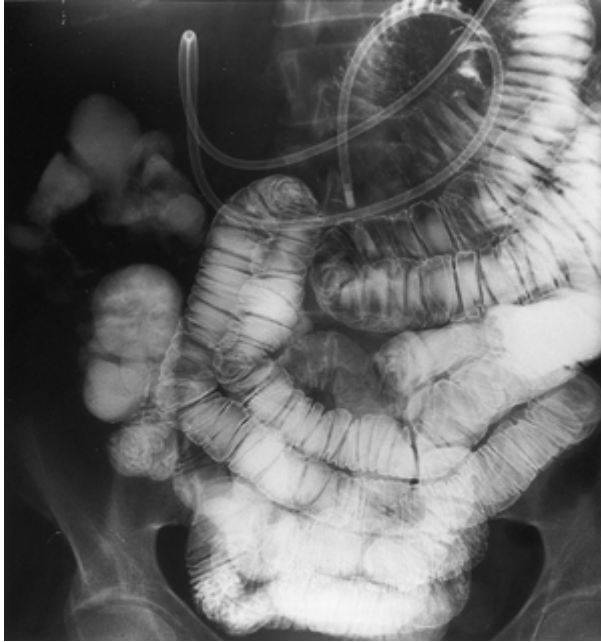Normal barium meal



- Small intestines:
 - The study is called a barium follow through.
 - The patient ingests 200-300mL of barium and lies prone; a series of images are taken until the contrast reaches the colon
 - The small intestines are usually framed by the large intestines. They end at the cecum (at the ileo-cecal valve). Transverse folds of mucous membrane

project in lumen of the bowel and barium lies between these folds, which appear as lucent filling defects of about 2-3 mm in width (volvulae conniventes).

- An alternative way to study the small bowels is using a barium enema. A barium enema gives excellent mucosal detail; however, it is not used in cases of malabsorptive syndromes. A barium enema is important for evaluating IBD (Crohn's disease and ulcerative colitis)



Normal barium enema/barium follow through

- In cases of intestinal obstruction, we look for the aforementioned signs, mainly dilation.

The following parts were not explained properly due to time constraints. The resident basically skipped through the slides without giving much attention to any details. However, the material is required. Therefore, I advise you to study the rest of the lecture from the slides (116-170)

- Inflammatory bowel disease:
 - o Crohn's disease:
 - More severe, transmural inflammation
 - Associated with fistulas and peri-anal disease
 - A barium follow through shows a cobblestone appearance.

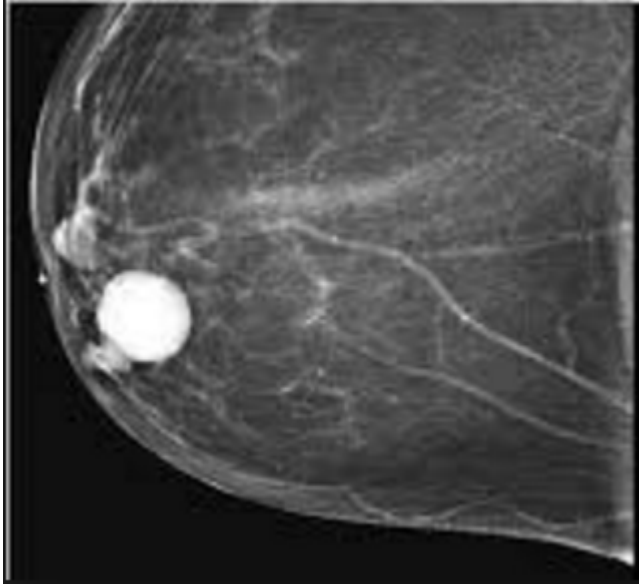
- On a CT scan, we can see the halo-fat sign. It is a fibrofatty proliferation that surrounds the intestines due to inflammation of the mucosa.
 - Crohn's disease is characterized by the presence of skip lesions.
 - Ulcerative colitis:
 - It mostly involves the colon
 - Can cause backwash ileitis
 - Toxic megacolon is a major complication
 - Higher risk of malignancy
 - Thumb-printing sign, button-shaped ulcers, lead pipe sign (dilation of colon with loss of haustrations)
- Diverticular disease:
 - An outpouching of the mucosa. It causes increased filling
 - Can be seen in any part of the GI tract.
- Volvulus:
 - Twisting of the colon along with the mesentery
 - Sigmoid volvulus: coffee bean sign on X-ray
 - Midgut volvulus: whirlpool sign on CT
- Intussusception:
 - Telescoping of bowel.
 - On barium swallow, claw sign
 - On X-ray bowel within bowel sign.
 - The most important modality for diagnosing intussusception is ultrasound. On the axial view, we have the target/donut sign. On the longitudinal view, we have the pseudo-kidney sign.
- Pancreatitis:
 - Acute pancreatitis: no specific X-ray signs: we can see sentinel bowel loops (dilated bowel loops in the area of pancreas). On a CT scan, we can see an edematous hypertrophied pancreas with dirty fat planes
 - Chronic pancreatitis: calcification and atrophy on CT scan. Calcification of the pancreas on X-ray.

Mammography

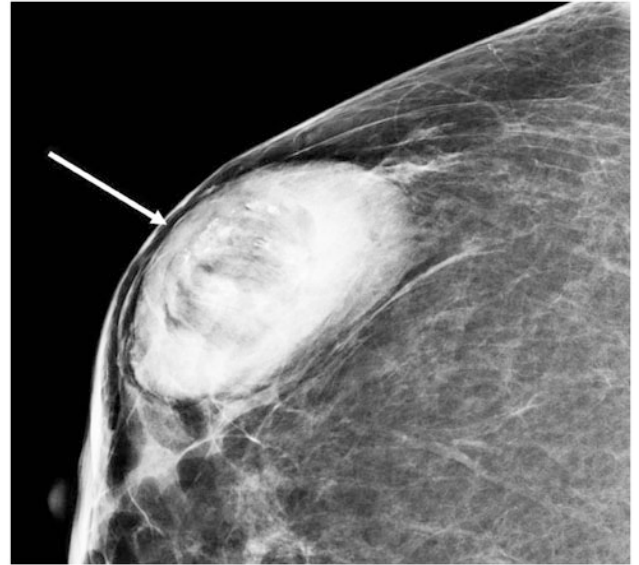- A mammogram is a breast X-ray used for screening and diagnosis of breast cancer. It is used as a screening tool in women who do not complain of any symptoms, and perform it as part of their regular follow up. It is used as a diagnostic tool for patients who complain of symptoms and need a radiographic confirmation of the diagnosis.
- Risk factors of breast CA:
 - o Family history
 - o Personal history of breast cancer
 - o Presence of breast changes on biopsy
 - o Genetic mutations (BRCA1 and BRCA2 mutations)
 - o Reproductive and menstrual history
- When to screen?
 - o 20-34 without risk factors: no need for screening
 - o 20-34 with risk factors: based on the clinician's decision
 - o >40: a mammogram is advised every 2 years.
- Before the age of 40, we use ultrasound as a screening tool. Before the age of 40, the breast is more dense (more fibroglandular tissue; therefore, mammograms will not show the pathology clearly).
- How to prepare for a mammogram?
 - o It is usually done during the first after last menses. During this period, the breast is the least tender
 - o We advise the patients not to put any perfume or deodorant, as the aerosole particles might look like calcifications on a mammogram.
- Views of a mammogram:
 - o Craniocaudal (CC): the breast appears as a semi circle; the pectoralis muscle cannot be seen; extend line perpendicular to the nipple (divides breast into inner and outer quadrants)
 - o Medio-lateral oblique (MLO): the breast appears as a teardrop; the pectoralis muscle can be seen; extend a line perpendicular to the nipple (divided the breast into upper and lower quadrants)
- How to read a mammogram?
 - o State the study: mammogram
 - o State the view: CC or MLO
 - o Mention the side: right or left breast
 - o Look for primary signs of malignancy
 - o Look for secondary signs of malignancy
- A mammogram can increase the risk of cancer development; however, its benefits outweigh its risks. Since we started using mammography, deaths due to breast cancer have decreased significantly.
- Sensitivity of a mammogram:

- The sensitivity of an image is measured based on the amount of fibroglandular tissue present in the breast. The more the fibroglandular tissue, the less sensitive the image. This is called the ACR system.
- ACR system:
 - ACR 1: fatty breast; usually in older females; <25% glandular tissue. Highly sensitive
 - ACR2: low amounts of fibroglandular tissue; 25-50% fibroglandular tissue
 - ACR3: heterogeneous breast; 50-75% fibroglandular tissue
 - ACR4: dense breast; >75% glandular tissue; sensitivity decreases to 60%.
- Primary signs of malignancy:
 - Masses
 - Calcifications
- Masses: We need to comment on the shape, margin and density:
 - Shape:
 - Round: coin shaped lesion
 - Oval: egg shaped
 - Lobulated: up to 3 lobes; if more than 3 lobes are present, it is considered irregular
 - Irregular: the presence of more than 3 lobes, an irregularly shaped mass, or a mass that looks different when viewed on CC and MLO views (ex looks round on CC and oval on MLO)
 - Architectural distortion: architectural distortion can be considered a primary or a secondary sign of malignancy. If another mass is present, architectural distortion is considered a secondary sign of malignancy. Architectural distortion indicates tethering of the parenchyma.
 - Margins:
 - Well circumscribed (well defined)
 - Obscured: part of the margin is covered due to an overlap between the mass and the breast parenchyma.
 - Microlobulated
 - Ill-defined: the edges of the mass cannot be defined
 - Speculated: sun-ray appearance; it is one of the most important signs of malignancy. The presence of a single speculation is highly suggestive of a malignant mass.
 - Density: the density of a mass is described in reference to the most hyperdense area in the breast.
 - Hypodense
 - Isodense
 - Hyperdense

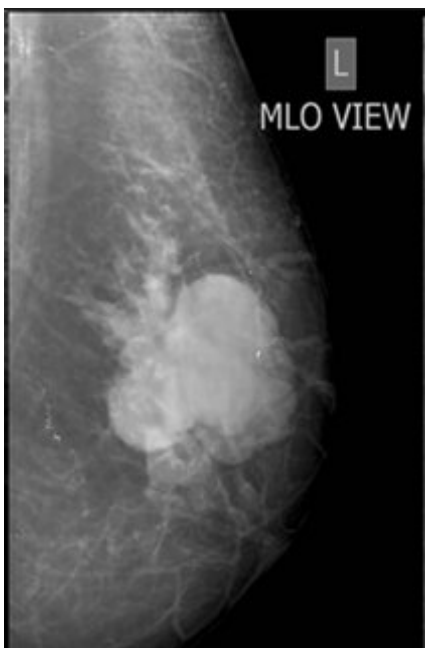
- Fat containing: heterogenous with a rim of calcification called eggshell calcification. Image: round, hyperdense, well circumscribed mass. Another type of fat containing mass is a lymph node a lymph nodes appears kidney shaped with a hyperdense cortex and hypodense medulla (Fat).



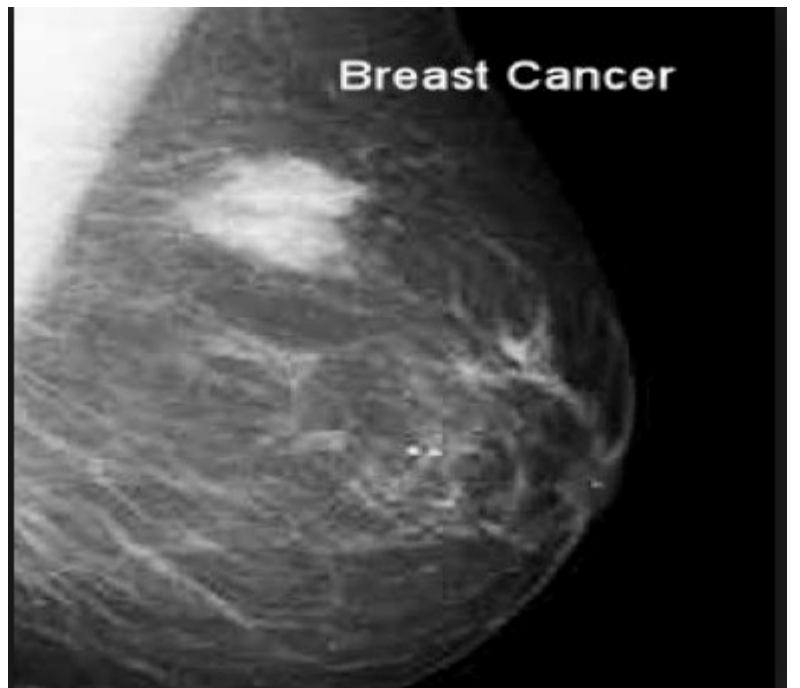
Mammogram showing a round breast mass; well circumscribed margin



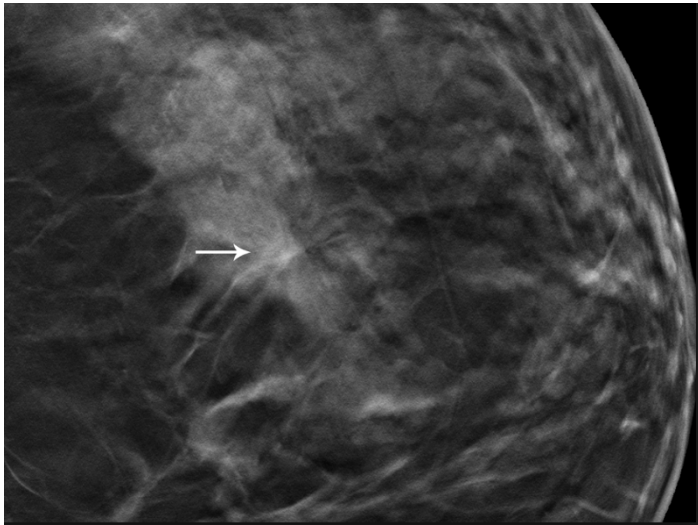
Mammogram showing an oval breast mass



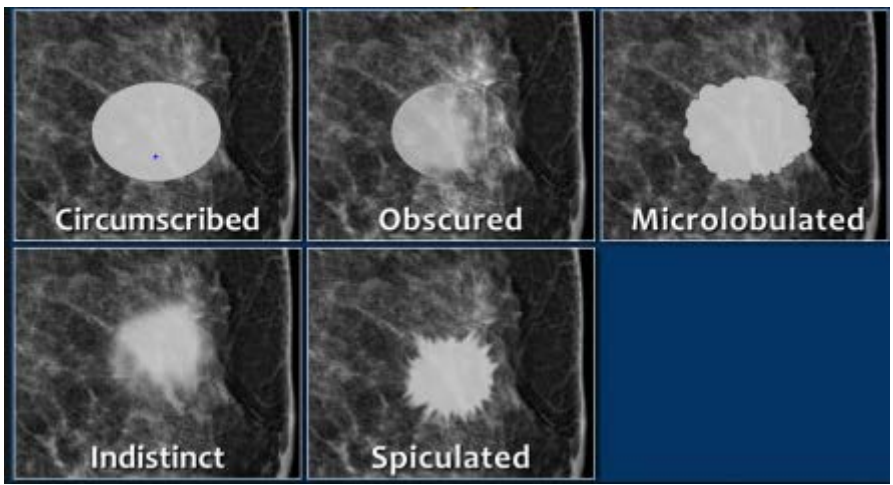
Mammogram showing a trilobed breast mass



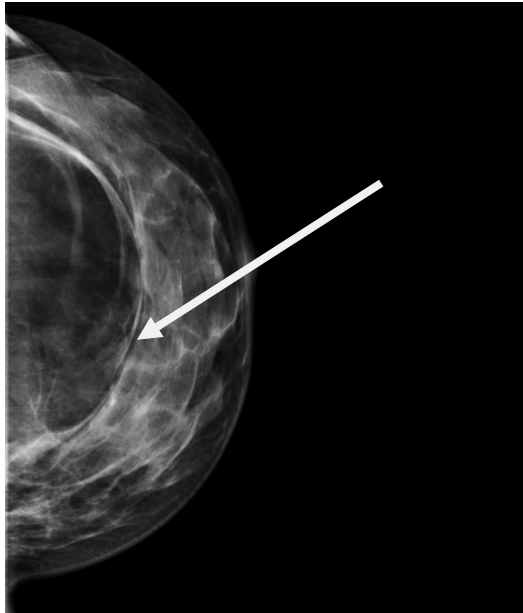
Mammogram showing an irregular breast mass



Mammogram showing architectural distortion

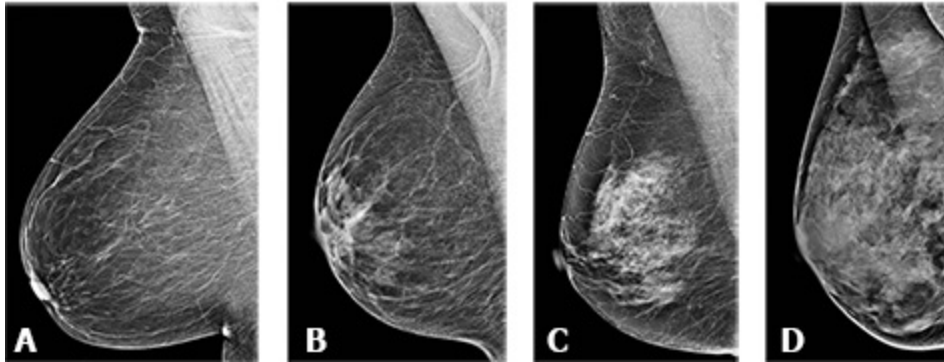


A diagram showing types of margins



Mammogram showing a well circumscribed fatty lesion with eggshell calcification; suggestive of lipoma

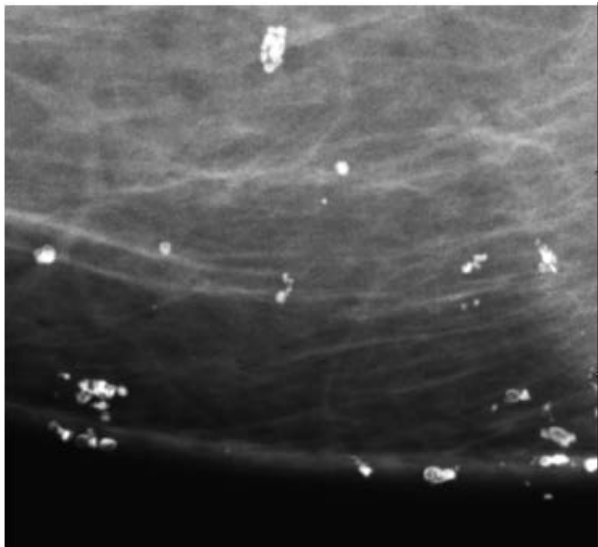
According to BI-RADS®, breast density ranges among (A) an almost entirely fatty breast, (B) a breast with scattered areas of fibroglandular density, (C) a heterogeneously dense breast, and (D) an extremely dense breast.



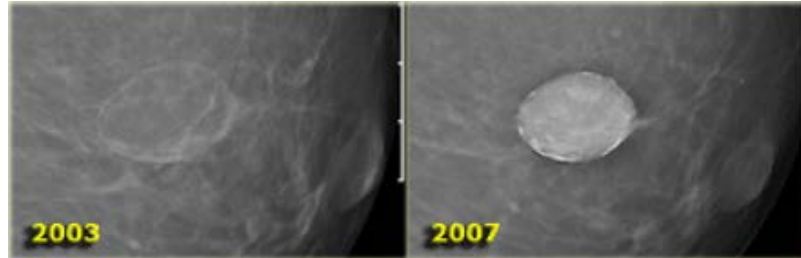ACR 1-4 breasts

- Signs of malignancy in a lymph node:
 - o Thickening of the cortex (>1cm)
 - o Loss of fatty meddulla (hilum)
 - o Increased in size (least important criterion)
- Classification of masses:
 - o Benign: Round or oval mass, well circumscribed, fat containing mass
 - o Malignant: Speculated, irregular, ill defined margins
 - o Other masses are equivocal
- Calcifications: We comment on the morphology and distribution of calcifications
 - o Morphology:
 - Benign:
 - Skin calcifications: round or oval calcifications within 1 cm of the skin
 - Round calcification away from the skin
 - Eggshell calcifications away from skin: indicate fat necrosis
 - Vascular calcifications: railroad appearance; they appear as either continuous or fragmented masses; increase with age
 - Popcorn calcifications: also called coarse calcifications; the presence of a popcorn calcification inside an isodense/hypodense well circumscribed mass is diagnostic of an involutingfibroadenoma which is a benign lesion.
 - Plasma cell mastitis: large rod calcifications
 - Dystrophic: ill defined calcifications usually following a surgery or a biopsy
 - Suture calcifications: calcifications at a suture site. Now rarely seen due to the use of absorbable sutures.
 - Intermediate risk:

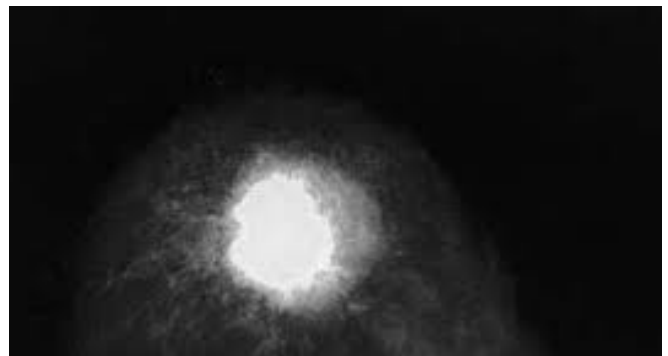
- Amorphous calcifications: powder like calcifications; can indicate sclerosingadenosis (benign) or low grade DCIS (malignant). They need to be biopsied.
- Malignant calcifications:
 - Pleomorphic: multiple calcifications that are irregular; crushed stone appearance. Indicate high grade DCIS
 - Fine linear branching calcifications; indicate high grade DCIS



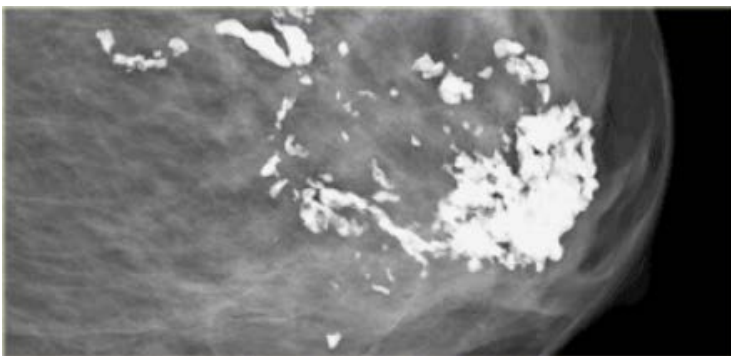
Multiple skin calcifications



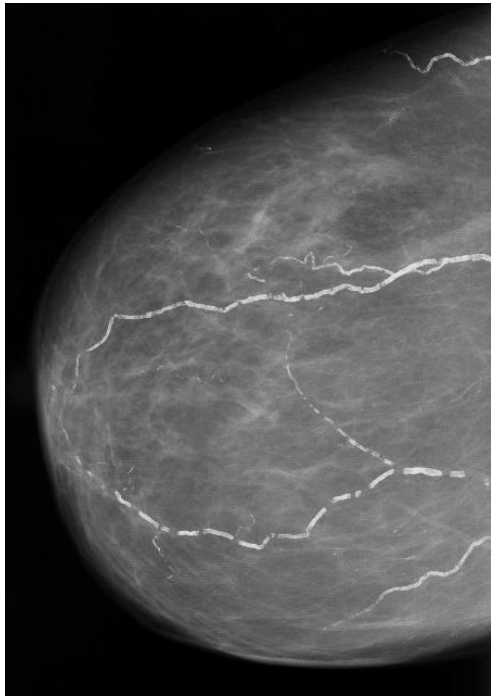
Eggshell calcifications



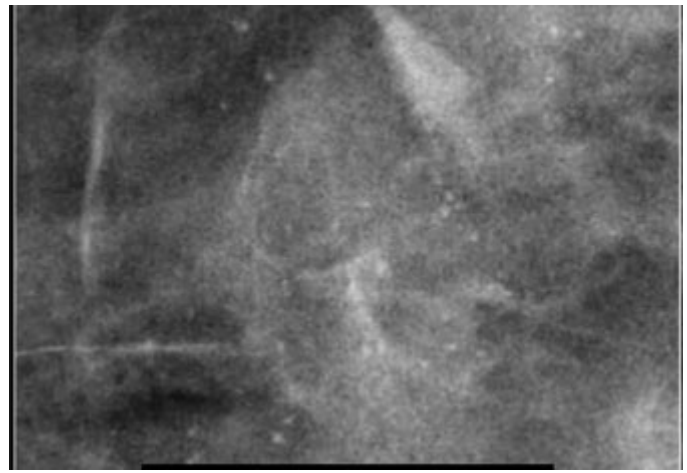
Popcorn calcification in a well circumscribed mass; involuting fibroadenoma



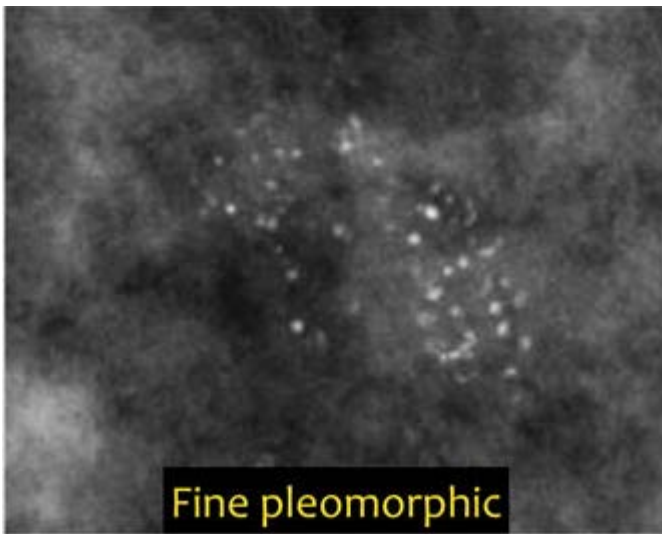
Dystrophic calcifications




Vascular calcifications breast



Amorphous calcifications



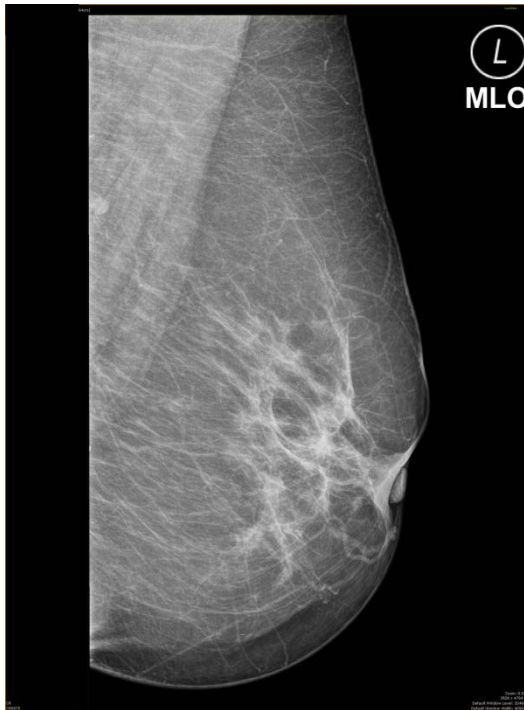Fine pleomorphic



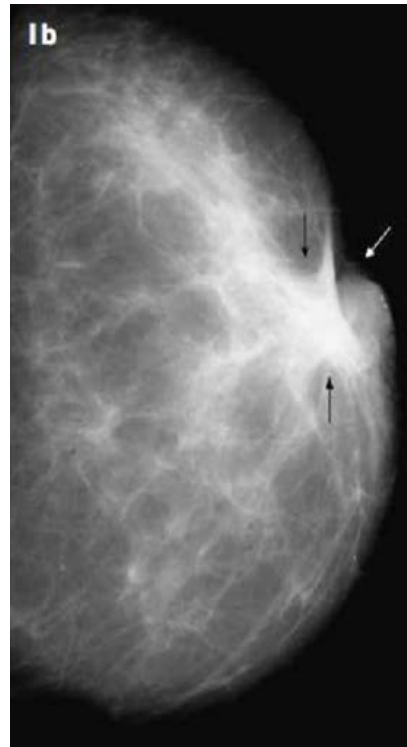
Fine linear branching

- Distribution of calcifications:
 - Clustered: the calcifications are close to each other (1-2 cm apart)
 - Linear calcifications: can be localized within two imaginary lines.
 - Segmental: triangular distribution; the base of the triangle is towards the chest wall and the apex is at the nipple
 - Regional: calcifications occupying 2-3 quadrants of the breast
 - Diffuse: calcifications distributed throughout the breast; mostly seen post-radiation due to fat necrosis.
- Classification of calcifications based on distribution:

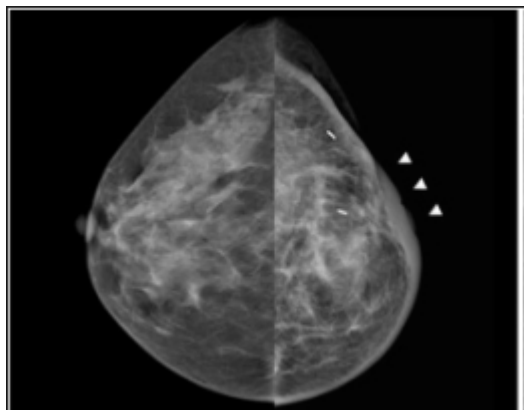
- Regional, loosely grouped or diffuse calcifications are usually benign
 - Segmental and cluster calcifications are usually malignant.
- Secondary signs of cancer:
- Nipple inversion (nipple going inside)
 - Architectural distortion
 - Thickened skin
 - Axillary lymphadenopathy
 - Skin retraction
 - Tissue asymmetry: differences in fibroglandular tissue distribution between the two breasts.



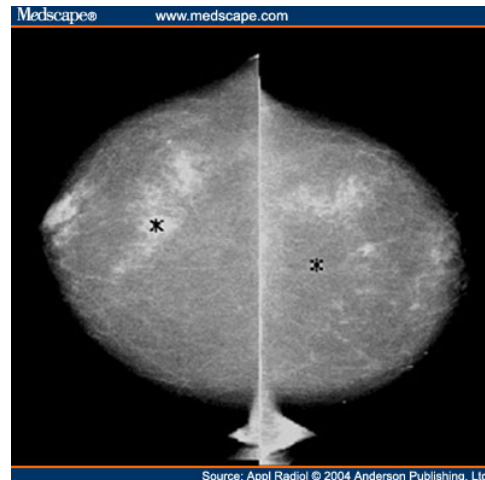
Nipple inversion



Skin retraction white arrow



Thickening of the skin (white arrows)



Tissue asymmetry (asterisk)

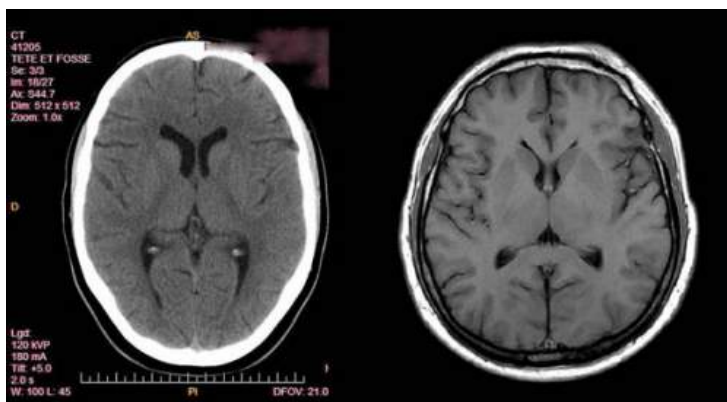
- The most common site of a mass is at the upper outer quadrant

- BI-RADS classification (breast mammogram report):
 - BI-RADS: 0 needs additional imaging and further evaluation; cannot assess the image.
 - BI-RADS 1: negative findings: there is nothing to comment on (no positive findings)
 - BI-RADS 2: benign finding; no need for short interval follow up; ex. Involuting fibroadenoma
 - BI-RADS 3: probably benign finding; <2% malignancy; follow up at 6,12,24 months (Initial short-interval follow up) ex. Fibroadenoma without a calcification
 - BI-RADS 4: suspicious finding (amorphous calcification); needs biopsy; 2-95% malignancy
 - BI-RADS 5: highly suggestive of malignancy >95% chance of malignancy; appropriate action needs to be taken
 - BI-RADS 6: a case of a proven malignancy by a biopsy; here the image is taken as follow up for treatment or to look for a different focus of metastasis. After chemotherapy or radiotherapy; the patient remains a BI-RADS 6. However, after surgical removal of a lesion, the patient returns to BI-RADS 1.

Brain MRI

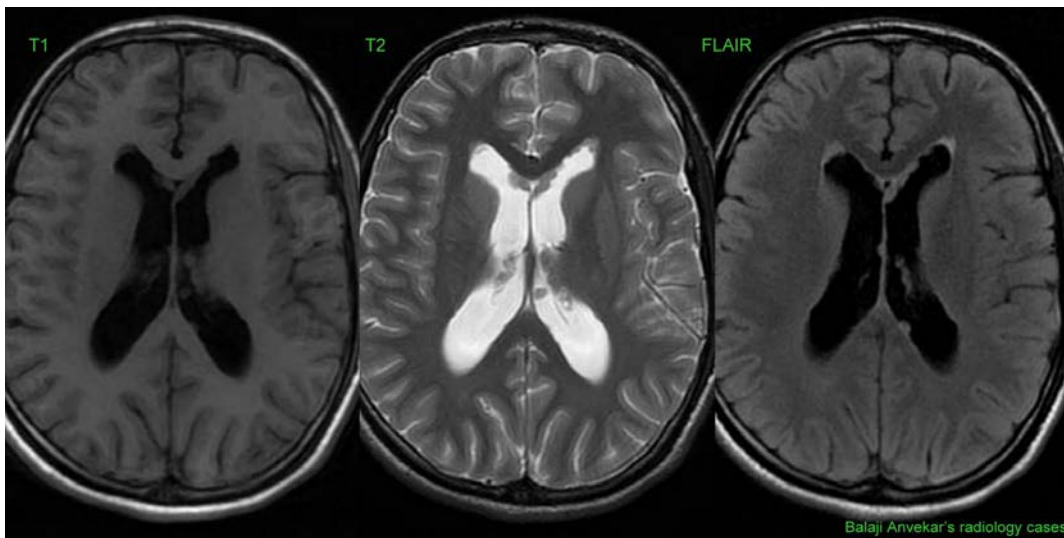
- MRI is different in principle than other modalities.
- MRI and ultrasound are non ionizing radiations.
- MRI:
 - o A field produced using a magnetic field.
 - o The power of magnetic field is measured using units of Tesla.
 - o Air is a weak magnet (0.5 tesla).
 - o The MRI machines used in clinical practice have a power of 3 Teslas.
- Physical principles of MRI:
 - o All protons will align with the magnetic field of the machine. The protons here are hydrogen atoms found in water molecules. Therefore, MRI is good for imaging organs with high water content. Bones and ligaments do not contain water; therefore, MRI is not used for detecting bony lesions.
 - o Once the protons are aligned we administer an electrical wave perpendicular to the magnetic field (at 90 degrees).
 - o The electrical current is turned off, and the protons are realigned with the magnetic field. The machine measures the time needed for protons to realign with the magnetic field.
 - o A computer program interprets these data and projects an image of the tissues.
 - o Each tissue has a different realignment speed of its protons. Therefore, different tissues appear in different colors.
 - o Whiter tissues are called hyperintense, darker tissues are called hypointense.
- MRI is superior to CT scan in visualizing soft tissues. An MRI scan is the ideal study to study the contents of the posterior fossa of the brain. Moreover, it is better to visualize the white matter, cranial nerves, basal ganglia, foramina, and vessels.
- The MRI machine has multiplanar capabilities. This means that the image is taken in different planes. A CT machine takes axial cuts, and a computer reconstructs the other planes. Therefore, if on the axial cuts, a certain cut is not clear its reconstruction will be aberrant. However, on an MRI this does not happen because the machine takes the image in all planes.
- Advantages:
 - o Superior soft tissue contrast
 - o No ionizing radiation: suitable for pediatrics and pregnancy
 - o Relatively safe contrast media:
 - The contrast media used in a CT scan is iodine based. Iodine based contrast materials are associated with a high rate of allergic reactions (If a patient has a history of an allergic condition, it increases the risk of an anaphylactic reaction.) To prepare a patient with a previous history of allergy for a CT scan, we need to administer corticosteroids.

- The contrast media used in an MR scan is Gadolinium based. Gadolinium is safe in comparison to iodine. It is associated with less allergic reactions. Moreover, allergic reactions to environmental substances (ex pollen) does not increase the risk of an allergic reaction to Gadolinium. No need to take any precautions in cases of allergy. However, if the patient has a history of an allergic reaction to Gadolinium, we do not perform an MR scan.
- Can be used with caution in patients with renal failure.
- Multiplanar capability
- Disadvantages:
 - Expensive
 - Not widely available: the facility that contains an MRI machine needs to be designed beforehand. The building needs to meet certain requirements for the installment of an MRI machine.
 - Not used in cases of emergency. MRI takes time (the average time is 15 minutes); therefore, in an emergency setting, we use a CT scan.
 - Not suitable for patients with claustrophobia. The MRI machine is a closed tube. There are some MRI machines called open MRI machines; however, these machines give a very low resolution because their power does not exceed 0.5 Teslas.
 - Cannot be used to visualize bone and tendons.
 - Cannot be used to visualize moving substances (blood); we use MRI to detect thrombosed blood.
- Contraindications:
 - First trimester of pregnancy due to lack of sufficient clinical data
 - Pacemakers: some pacemakers are MRI compatible; however, they are only compatible with powers up to 1.5 Teslas.
 - The presence of a ferromagnetic metal inside the body. The presence of a non-ferro-magnetic metal is a relative contraindication
 - Recent prosthesis installment <6 weeks.
- How to differentiate a brain CT scan from a brain MRI:
 - On a CT scan, the bone looks thick, hyperdense, and adjacent to the brain parenchyma.
 - On an MRI the bone looks black; the hyperintense line surrounding the brain on an MRI is the scalp fat.
 - Superior detail of the brain on an MRI.



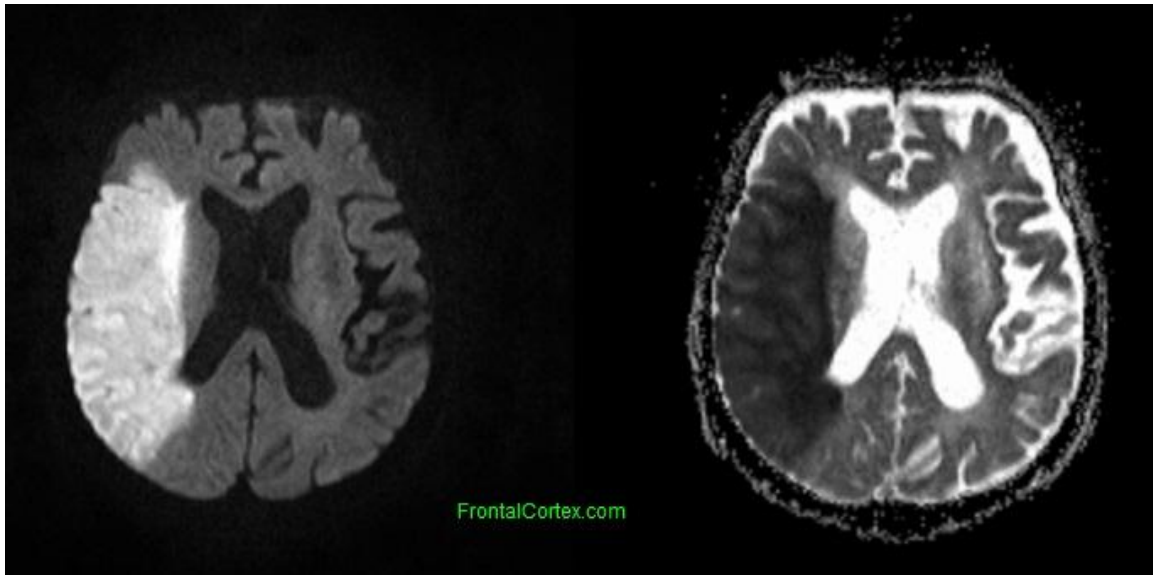
Brain CT scan (left) and Brain MRI (right). Notice the superior brain tissue clarity on MRI, and the hyperdense bone on CT.

- Sequences used in brain and spine MRI:
 - o T1: used to visualize anatomy and localize a lesion; most lesions look hypointense on a T1 sequence.
 - The CSF looks hypointense
 - Grey matter looks hypointense (on the periphery)
 - White matter looks hyperintense (centrally)
 - Hyperintense structures on a T1 sequence:
 - Fat
 - Subacute hemorrhage
 - Melanin containing tumors (melanomas)
 - Calcifications
 - o T2: used to detect pathology; all fluids appear hyperintense on a T2 sequence; therefore, it is hard to differentiate between a normal fluid (free fluid) and pathological fluids.
 - The CSF looks hyperintense
 - Grey matter looks hyperintense
 - White matter looks hypointense
 - o FLAIR sequence: Used to detect abnormal fluids
 - FLAIR stands for Fluid Attenuation Inversion Recovery sequence.
 - In this sequence, the computer device removes the free fluid (normal fluid) in the brain and keeps the abnormal fluids.
 - CSF is hypointense
 - White matter is hypointense
 - Grey matter is hyperintense



Axial brain MRI's showing the differences between T1, T2, and FLAIR

- Important pathologies:
 - o Cerebral ischemia
 - o Hemorrhage
 - o Tumor
- Cerebral ischemia:
 - o In cases of a suspected stroke, the first study to be done is a non-contrasted CT. A non-contrasted CT can reveal the site of a hemorrhagic infarct. However, a CT scan gives limited information about edema.
 - o To diagnose an ischemic infarct, we use an MRI scan.
 - o How does an edema form?
 - Following an ischemic event, the Na/K pumps will be disrupted.
 - This leads to fluid entrapment inside the cells leading to cellular swelling.
 - This swelling appears on an MRI scan as a diffusion restriction, which is a well demarcated area that respects the arterial territory of the infarcted vessel. This is called cytotoxic edema.
 - If the edema does not respect an arterial territory, the cause is not a stroke.
 - o Causes of edema:
 - Cytotoxic edemas are usually caused by strokes
 - Vasogenic edemas are either caused by an abscess or a tumor. To differentiate between an abscess and a tumor, we give a contrast material. The presence of ring enhancement indicates an abscess. The presence of a heterogenous enhancement indicates a tumor.
 - o How do we diagnose a stroke on MRI?
 - On a T1 scan, the infarcted area looks hypointense.
 - On a T2 scan the infarcted area looks hyperintense and well demarcated.
 - The golden standard for the diagnosis is a DWI and ADC sequences:
 - DWI: diffusion weighted image; this sequence is not used to study the brain's anatomy. Therefore, it looks hazy. However, the area of ischemia will look hyperintense and well demarcated. On a DWI sequence, the CSF looks hypointense.
 - ADC: apparent diffusion coefficient. The area of a stroke will look hypointense (the hyperintense area on DWI will look hypointense on ADC). On an ADC sequence, the CSF looks hyperintense.
 - The DWI sequence and the ADC sequence need to be viewed side by side. To make a diagnosis of a stroke, you need to have a well demarcated wedge shaped lesion that respects the arterial territory. It must look hyperintense on DWI and hypointense on ADC.
 - DWI and ADC can detect infarcts up to 1 week of age. After 1 week, the area of cellular swelling disappears.

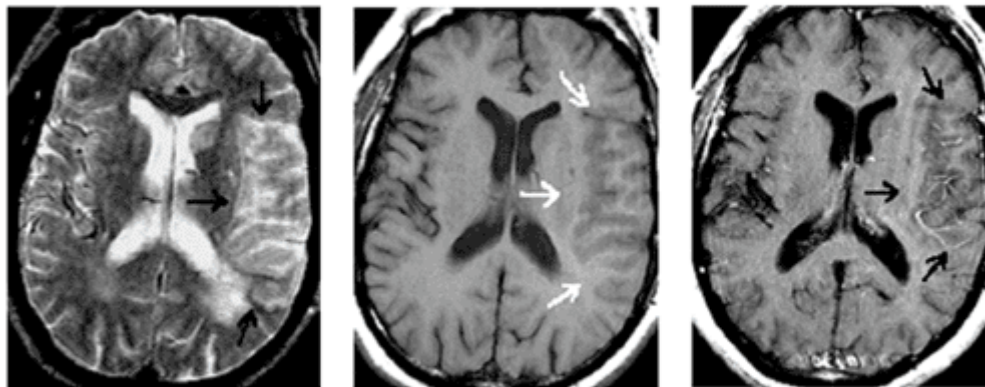


Axial brain MRI's showing a DWI (left) and an ADC (right) sequences with a middle cerebral artery infarct. Notice the wedge shaped lesion and the lack of cerebral details.

Medscape®

www.medscape.com

MRI of Acute Stroke



T2

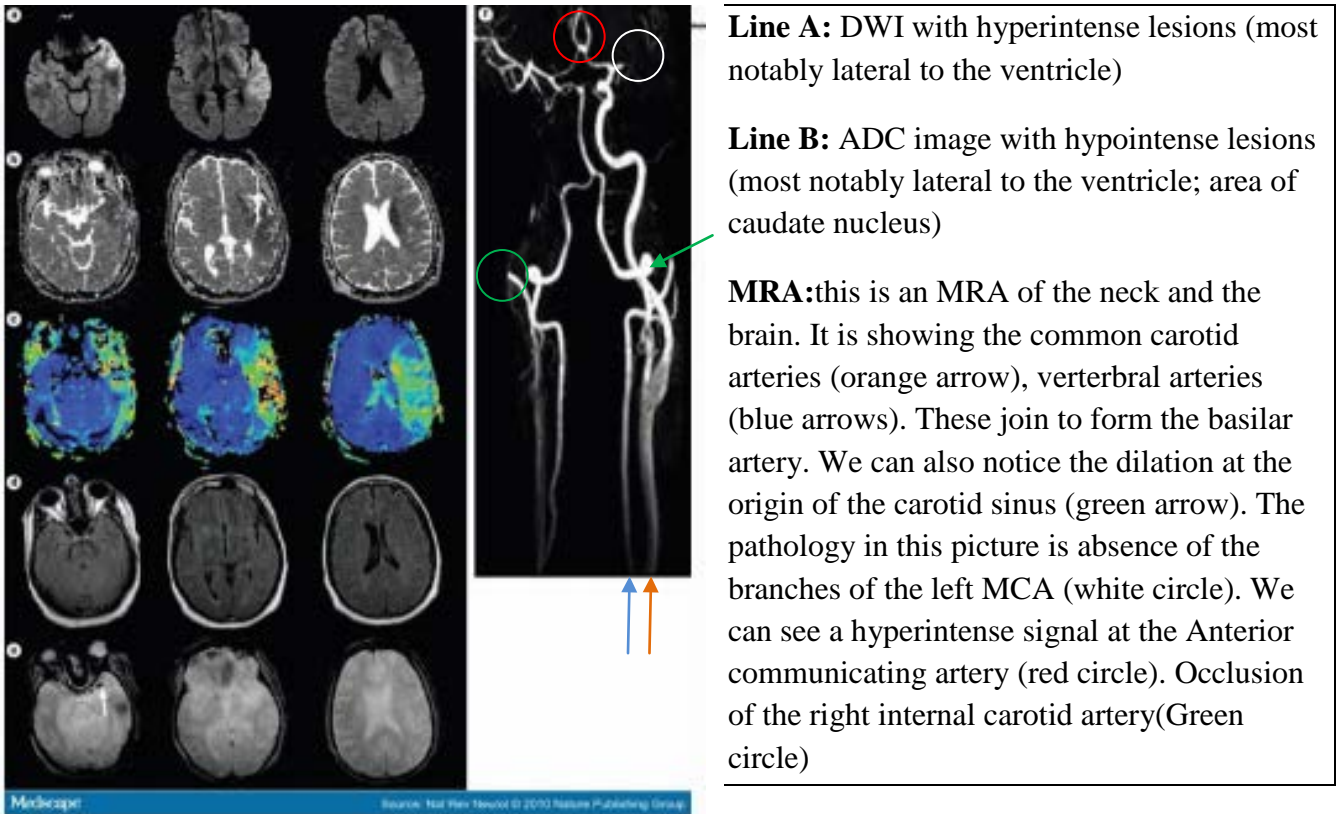
T1-non

T1-gad

Source: South Med J © 2003 Lippincott Williams & Wilkins

Axial brain MRI's showin an acute stroke. The T2 image shows a well demarcated hyperintense lesion. The T1 non contrasted images shows a hypointense area (white arrows). The T1-gad (contrasted) shows a hyperintense rim at the area of the stroke (black arrows)

- MRA:
 - An MRA can show the artery involved and can be used to differentiate between an acute and a chronic stroke. With a chronic stroke, we can see collaterals.
 - An MRA only shows the vessels.

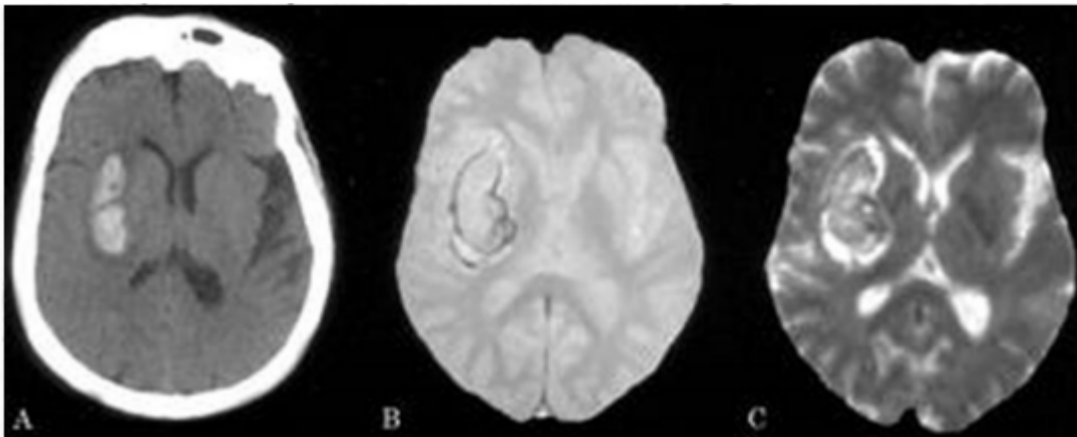


- A normal angiographic study does not show this hyperintense signal at the level of the Anterior communicating artery. The presence of this sign indicates collateralization. In the picture above, the right internal carotid artery occlusion is chronic (notice the collaterals on the right side)

- Hemorrhage:

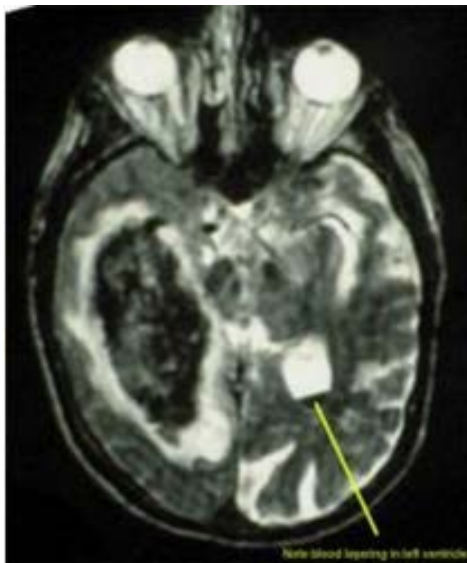
- The most sensitive modality for detecting a hemorrhage is a CT scan; however, in certain settings an MRI can be useful.
- On an MRI, the appearance of a hemorrhage depends on its age and the sequence used.
- On a T2 weighted scan, a hemorrhage looks as a heterogenous lesion.
- On a T1 scan, a subacute hemorrhage looks as a hyperintense lesion.

- The most important sequence for detection of a stroke is called an SWI (susceptibility weighted image) sequence. An SWI is a subtype of a gradient echo sequence. If the suspected lesion is a hemorrhage, an SWI sequence will show a hyperintense lesion with a hypointense rim. A tumor will show as a hyperintense lesion without a hypointense rim.
- FLAIR sequence: very sensitive for detecting a subarachnoid hemorrhage. A subarachnoid hemorrhage will look as a hyperintense lesion on a FLAIR sequence.
- We need to differentiate between two terms:
 - Area of abnormal intensity signal: this term indicates the presence of an abnormal signal without a change in the architecture of the brain (no midline shift, no effacement of sulci). This is characteristic of a stroke.
 - Space occupying lesion: an area of abnormal signal intensity with loss of normal brain architecture due to mass effect (midline shift and effacement of sulci). This can be seen in cases of hemorrhage and tumors.
- Signs of mass effect:
 - Effacement of sulci
 - Midline shift
 - Compression of ventricles

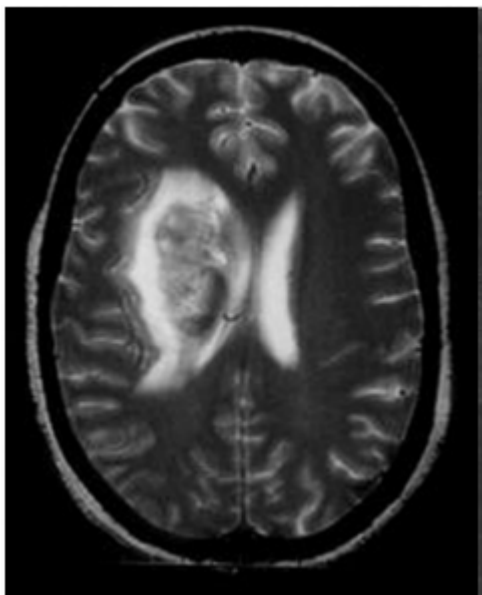


Axial cuts of the brain (A) A CT scan of the brain showing a hyperdense lesion at the area of the basal ganglia. (B) an SWI sequence showing hyperintense lesion surrounded by a hypointense rim in the area of basal ganglia. This indicates hemorrhage in the basal ganglia. (C) T2 weighted MRI a heterogeneous lesion with a hyperintense rim at the area of basal ganglia. The lesion is exerting a mass effect evidenced by minimal midline shift and effacement of sulci.

- How to localize a lesion (how to determine the level of the cut)
 - o The axial cuts are not straight cuts. The cuts are taken in an oblique fashion.
 - o If you cannot see the third ventricle: the anterior 2/3 represent the frontal cortex, the posterior 1/3 represents the parietal lobe. The most posteromedial aspect represents occipital lobe
 - o If you can see the third ventricle: the anterior 1/3 frontal lobe, the middle 1/3 temporal lobe, the posterior 1/3 occipital lobe.
 - o At the level of the eye globes: the anterior portion temporal lobe, the posterior portion is the occipital lobe
 - o If you can see the cerebellum, the anterior portion represents the temporal lobe (inferior surface of temporal lobe)

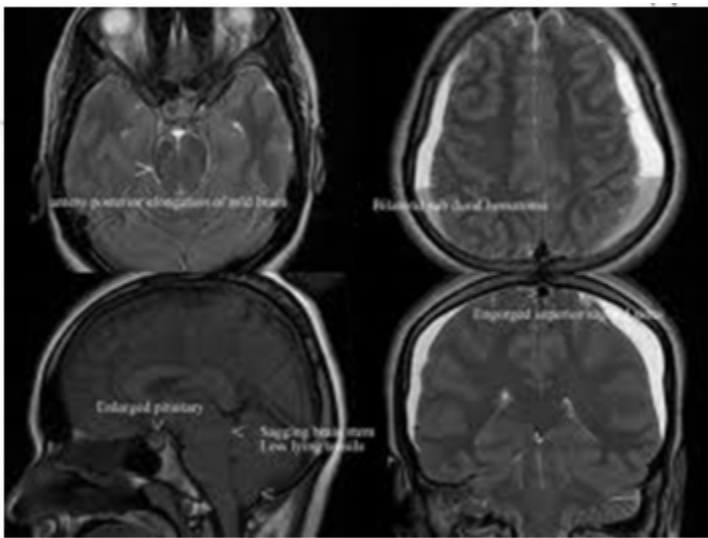


An Axial T2 weighted sequence; showing a heterogenous mass on the left temporal lobe. The mass is hypointense with a hyperintense rim. The mass is not wedge shaped and does respect an arterial territory; it is most probably a hemorrhage (compressing the ventricles with effacement of sulci). The hemorrhage is extended to the left side (yellow arrow). Here the left sided hemorrhage is inside the lateral ventricle (notice the fluid level)



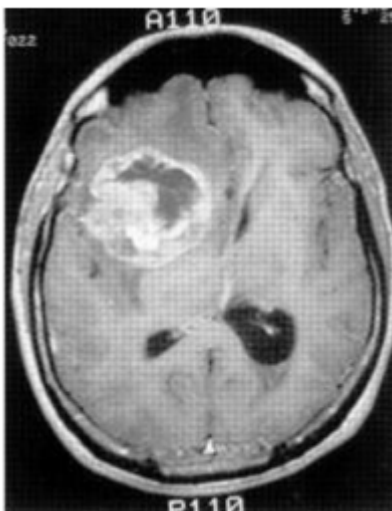
A T2 axial brain MRI; supratentorial cut showing a right frontal lobe space occupying lesion. The mass is heterogenous with a hyperintense rim. It is surrounded by an area of edema. It is exerting a mass effect manifested as effacement of sulci, midline shift, and compression of right lateral ventricle.

- The differential diagnosis for a heterogenous lesion with a hyperintense rim is either a tumor or a hemorrhage. To differentiate between a hemorrhage and a tumor, we give contrast material. Tumors will become hyperintense. Hemorrhages do not change in intensity (they do not take up contrast material)
- The typical sites for a hypertensive hemorrhage are the basal ganglia, thalamus, cerebellum, and pons. The presence of a hemorrhage outside of these areas is an indication for an MRI 6 weeks after the date of the current image.
- To differentiate between an edema and a hemorrhage on a FLAIR scan, look at the homogeneity of the lesion. A homogenous hyperintense lesion indicates an edema. A heterogenous lesion indicates a hemorrhage.



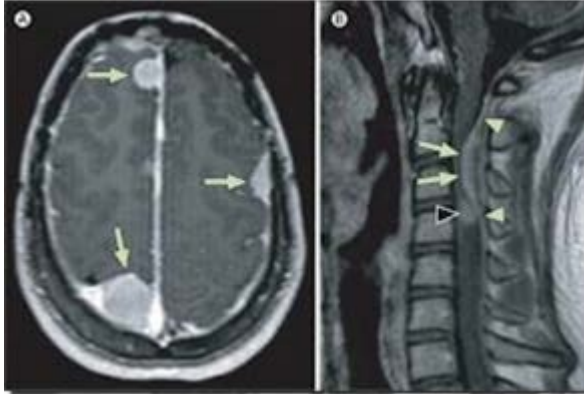
FLAIR sequence showing bilateral subdural hematoma.

- Tumors:
 - o The most important sign for detecting a tumor is enhancement. We take a T1 image before injecting a contrast (the tumor usually looks as a hypointense lesion). We inject contrast material, and take another image. A tumor will become a hyperintense lesion after injection of contrast material. Hemorrhages never enhance.

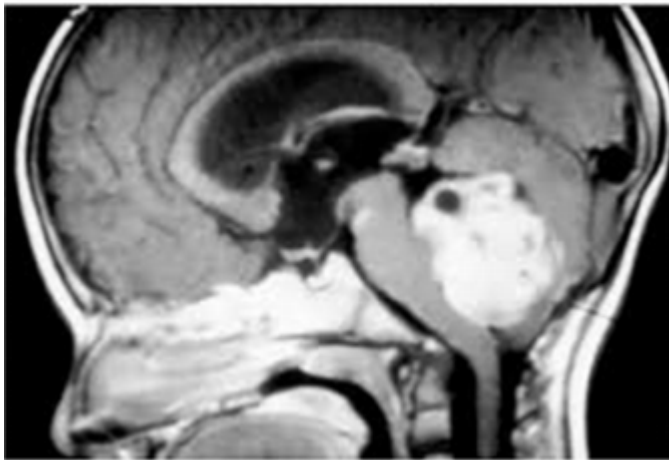


An axial brain MRI with contrast (notice the vessels) showing an enhancing lesion on the right frontal lobe. The mass looks hyperintense with an area of central necrosis (hypointense area inside the mass). Moreover, we can notice a hypointense area surrounding the mass indicating edema.

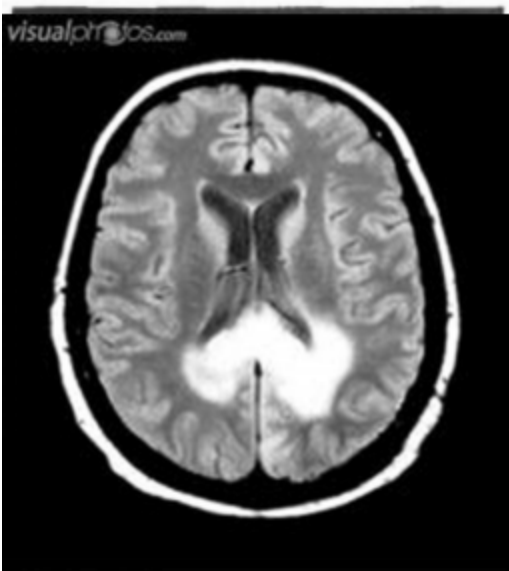
- How to differentiate between an intra-axial and an extra-axial mass:
 - If the widest diameter of the mass attaches to the meninges, it is an extra-axial mass.
 - If the dura enhance, it is an extra-axial mass. Enhancement of the dura is known as the dural tail sign.



- (a) An axial brain MRI post contrast showing multiple enhancing masses (arrows) with enhancing dura. These features are suggestive of an extra-axial mass. The most likely diagnosis is meningioma
- (b) A spinal sagittal MRI of the same patient showing a mass compressing the spinal cord.

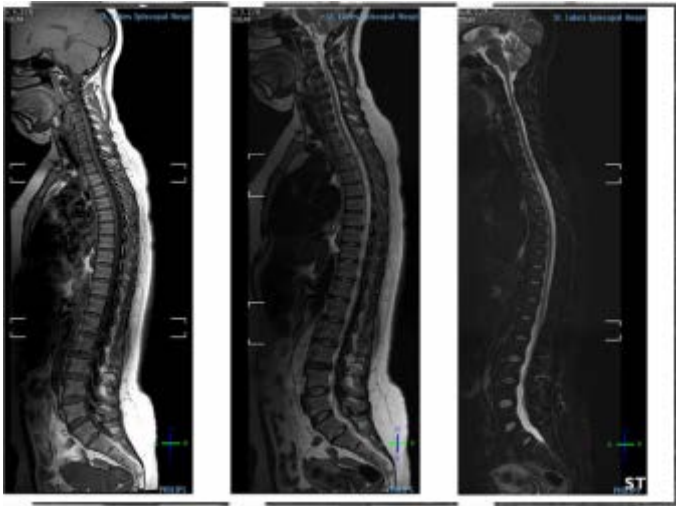


Sagittal post contrast brain MRI showing an enhancing lesion in the fourth ventricle. The lesion has a cyst inside it.



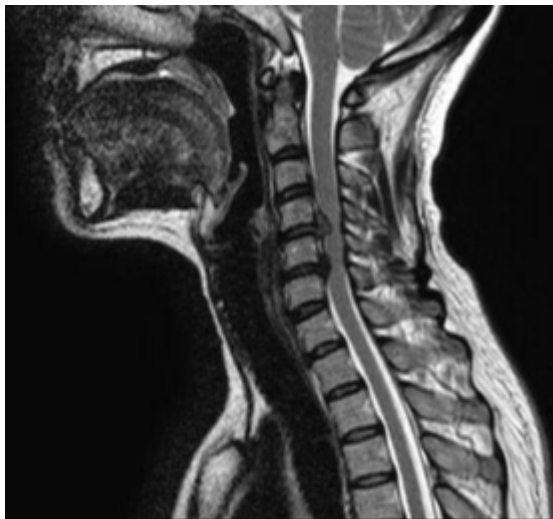Axial brain MRI scan; FLAIR post contrast. Showing an enhancing lesion on the splenium of corpus callosum. The lesion is exerting a mass effect as manifested by asymmetry of the occipital horns of the lateral ventricles; the most likely diagnosis is glioblastoma

- Spinal MRI:
 - o There are three types of studies done on the spine:
 - T1
 - T2
 - Fat suppression: the signal from fat is removed; it makes the anatomy clearer. Usually used with a T2 scan.
 - o When looking at a spinal MRI comment on the alignment of the vertebrae, herniation of discs, any abnormal intensities, especially in the posterior element of the vertebral body (common site for metastasis)
- Example images:

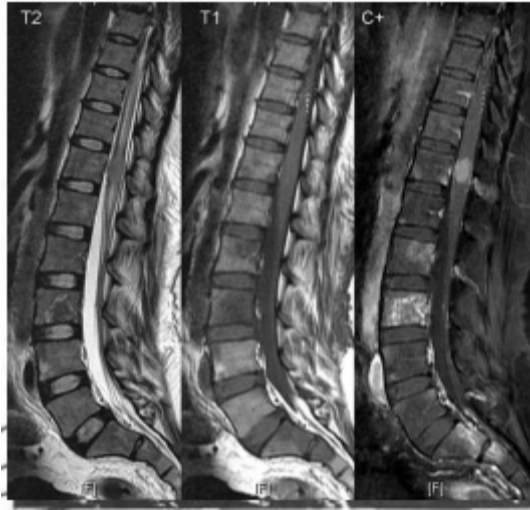

Sagittal spinal MRI

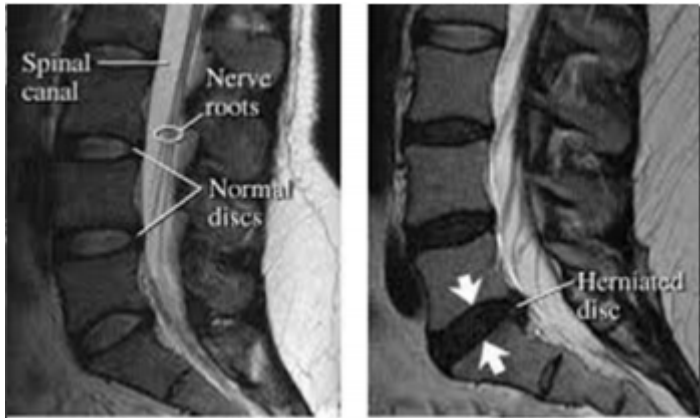
- (a) T1 weighted image; the CSF is black, the fat is hyperintense
- (b) T2 weighted image; the fat is hyperintense, and CSF is hyperintense
- (c) Fat suppression T1: CSF is white, fat signal removed. On this image, we notice some loss in the hyperintensity inside the discs. This is due to disk dehydration (aging process)



T2 Sagittal cervical spine MRI showing a herniated disc at the level of C4/C5 and C5/C6. This herniation is causing spinal cord compression



T2,T1,post-contrast sagittal lumbar MRI showing multiple osteolytic lesions and multiple enhancing masses on the lower lumbar area (C+ photo) indicating metastasis



T2 sagittal lumbar spine MRI showing a disc prolapse at level of L5/S1. The discs also show degenerative changes (loss of fluids) compare to the image on the left.

Nuclear medicine (introduction)

- Nuclear medicine is a separate branch of radiology. In Arab countries, it is still not developed.
- Basic principle: the patient receives a radioactive material. The radioactive material called a radiopharmaceutical. The substance emits radiations that are detected by a gamma camera. The gamma camera produces an image.
- How does it work?
 - o Gamma rays and X-rays are similar. A gamma ray is produced through nuclear decay of a certain atom; however, X-rays are produced when electrons travel down energy levels emitting energy on the way.
 - o Gamma rays travel in all directions; therefore, the image produced by gamma rays is hazy. Nuclear medicine is not used to study the anatomy of a certain organ (the image is of a low quality). However, nuclear medicine can be thought of as the study of function of a certain organ. A nuclear image takes time, while an X-ray is almost instantaneous.
 - o Depending on the organ, different materials are used.
- Most common radiopharmaceuticals:
 - o ⁹⁹Tc: Technetium 99 is the most commonly used radioactive substance because:
 - The only radiopharmaceutical that produces pure gamma rays (other substances produce other rays)
 - Has a suitable energy level (140 kilo electron volt (keV)); if the energy was lower, the rays would not penetrate the body. If the energy was higher, the rays would cause damage to the body.
 - Suitable half life: 6 hours; if the half life was shorter, we would need a more continuous supply materials.
 - It is available and cheap
 - o ⁹⁹Mo: ⁹⁹Molybdenum is a radioactive substance that decays into ⁹⁹Tc.
- Types of nuclear studies:
 - o Planar imaging:
 - Here, the images can be dynamic or static.
 - They take an image of the organ in any direction
 - A common example is a renal nuclear scan
 - o SPECT:
 - Single Photon Emission Computer Tomography
 - The radioactive material used produces one photon only; ex. Technetium
 - The body emits a radiation, and a camera takes an image. Then, a computer reconstructs a 3D representation of the structure.
 - The radioactive materials here are of a high molecular weight.
 - The resolution of this photo is lower than a PET scan.

- PET
 - Positron Emission Tomography
 - The PET scan uses positron emitting substances. These substances include radioactive fluorine (most important), radioactive oxygen, radioactive carbon, radioactive nitrogen, and gallium.
 - A positron is an electron with a positive charge; it is produced through a process called positron emission or beta decay.
 - How is a positron produced?
 - A proton inside the radionucleotide is transformed into a neutron.
 - When this transformation happens, the neutron decays into a particle called a positron.
 - The positron is released from the molecule.
 - Upon its release, the positron loses energy. As it loses energy, the positron can interact with electrons in the surroundings.
 - The process of interaction between a positron and an electron is called annihilation. The process of annihilation produces gamma rays. (both the positron and electron need to have 520 keV energy to interact)
 - The produced gamma rays are detected by a gamma camera, and the image is recorded
 - As you have noticed, a PET scan uses two particles to produce gamma rays. Therefore, its resolution is higher than a SPECT scan.
 - These radionucleotides can be inserted into normal compounds in order to obtain the image. For example, we can use radioactive amino acids, radioactive water, or radioactive RBCs, etc....
 - The most commonly used radionucleotide is fluorine.
 - The mostly commonly used radioactive compound is radioactive glucose
 - Radioactive glucose (fluorodeoxyglucose)
 - We replace the hydroxyl group of glucose with a radioactive fluorine atom.
 - Radioactive glucose will be taken up by the cell just like normal glucose.
 - It will start the glycolysis pathway; however, it will not proceed until the end (due to the replacement of hydroxyl with fluorine)
 - These molecules will accumulate inside the cells, and will emit a radiation that is detected by the detectors placed around the patient.
 - Any cell with increased glucose uptake, will emit more radiation.
- So, a PET scan using radioactive glucose can show any small

increase in metabolism inside a certain cell. This is ideal for detecting small tumor cells

- Hybrid imaging: new techniques that combine a CT scan with a PET scan or a CT scan with a SPECT scan. These give both anatomical and functional findings in a certain organ. However, they are not used in Jordan.
- Important procedures in nuclear medicine (you don't need to know how to interpret a nuclear image; however, you need to know the theory)
 - Thyroid scan:
 - Indications of a thyroid scan:
 - Any case of low TSH is an indication for a thyroid scan.
 - Low TSH can be a result of hyperthyroidism, subacute thyroiditis, or Hashimoto's thyrotoxicosis.
 - Normal thyroid physiology:
 - The thyroid has an Na-I symporter; that transports sodium along with iodine into the thyroid.
 - In the thyroid, iodine atoms undergo two processes:
 - Trapping: the iodine ion is transformed into I_2 under the effect of the enzyme thyroid peroxidase (TPO)
 - Organification: iodine is incorporated into a tyrosine molecule before it is transformed into T3 or T4. The resultant T3/T4 will bind to colloid.
 - Radioactive iodine can undergo both trapping and organification producing radioactive iodine. However, ^{99}Tc only undergoes trapping. Therefore, we prefer to use radioactive iodine because it is more physiological.
 - What materials can we use in a thyroid scan:
 - ^{99}Tc : can enter the cell; however, it will be expelled directly (because the intracellular enzymes cannot organify it)
 - I-123: the best material that can be used for a thyroid scan. However, it is very expensive and has a short half life
 - I-131:
 - Half life; 8 days
 - In high doses, used for radio iodine ablation therapy
 - In low doses, can be used to assess thyroid function.
 - It emits beta particles; therefore we need a high dose of radiation.
 - Advantages: used in treatment, cheap and widely available
 - Disadvantages: high dose of radiation, which can cause some damage.
 - Prerequisites for the procedure:

- The patient should be fasted
- The patient should not be on any medications that affect the results of the test
- Contraindicated in pregnancy and lactation
- Normal results: a normal thyroid gland will take only 10-30% of the administered iodine dose. Any increase or decrease is considered abnormal.
- Pathologies:
 - Grave's disease:
 - Diffuse increase in uptake because the thyroid is hyperactive
 - Positive antibodies
 - Treatment: surgery, radioactive iodine ablation, or anti-thyroid drugs.
 - Nodules:
 - Hot nodules:
 - Single: here, we do not take a biopsy, because a single nodule is benign. A single nodule can never cause hyperthyroidism. However, it can be treated using surgery or radioactive iodine ablation. We do not use antithyroid medications, because once you stop them, the nodule will be activated again.
 - Multiple: can cause hyperthyroidism. On an uptake scan, there is one dominant nodule that takes up most of the radioactive iodine. Treated the same way as a single nodule
 - Cold nodules:
 - Require a biopsy as they might be malignant.
 - Treatment is usually surgical.
 - Thyroiditis:
 - In cases of thyroiditis, there is a history of infection. It might be painful or painless.
 - The uptake is decreased due to destruction of the thyroid.
 - Treatment is supportive with beta blockers and NSAID's
 - Hashimoto's thyroiditis:
 - It can present as hyperthyroidism or hypothyroidism depending on the stage of disease
 - Positive antibodies
 - Presents as decreased uptake due to autoimmune destruction of the thyroid.

- Treated with levothyroxine

- Lung perfusion scan (V/Q scan)
 - We use this scan in cases of a suspected PE.
 - The radioactive material used (Macroaggregates of albumin labeled with Tc99):
 - Larger than RBC.
 - These macroaggregates are administered IV; they will follow the circulation until they reach the pre-capillary arterioles where they are stuck (their size is too big to cross these arterioles).
 - In principle, we cause a microdiffuse PE. However, this is not dangerous as the lungs have a huge reserve that will deal with this temporary compensation in the lung function.
 - We usually use 500,000 particles for the scan. However, if the lung's function is compromised or the patient has previously underwent a lobectomy, we use a smaller number of particles.
 - The macroaggregates are removed from the lungs via the macrophages (a process that takes a couple of hours) Radioactive substance macroaggregate of albumin larger than a red blood cell if given IV will reach the pulmonary capillaries and precapillary arterioles. We cause a microdiffuse PE (we give 500,000 particles) we do not affect the pulmonary function. The hallmark of PE. Low perfusion but high ventilation. This is called a ventilation perfusion scan.
 - A PE will look like a wedge-shaped defect on the perfusion scan.
 - To confirm the diagnosis, we use a ventilation scan.
 - Ventilation/perfusion match: not a PE
 - If the ventilation is high, this is known as ventilation perfusion mismatch, which is highly suggestive of a PE.
 - Materials used for a ventilation scan: Tc99 labeled DTPA
 - If you are still in doubt of the diagnosis, order a spiral CT scan.
 - Contraindications of a VQ scan: intracardiac shunting
 - When do we use a CT scan? When in doubt of the diagnosis, chronic PE, if the patient has contrast allergy.
 - A V/Q scan can be used to tell you about the differential function of the lung (right vs left function). Therefore, it is important to perform this scan before performing a lobectomy (pneumectomy)

- Myocardial perfusion scanning:
 - Cardiac diseases are becoming one of the leading causes of mortality. This is because the population is aging.
 - When do we use a myocardial perfusion scan?
 - In high risk patients, a myocardial perfusion scan is useless. These patients need to be admitted and catheterized in order to detect the abnormality
 - In low risk patients, catheterization would be too invasive. Therefore, we use a myocardial nuclear perfusion scan.
 - Methods used to study the heart, its anatomy, and its function:
 - CT scan is excellent for visualizing the anatomy of the heart. However, it requires a high dose of contrast (contraindicated in diabetics) and it requires high expertise for interpreting the problem. It does not show subtle changes
 - Echocardiogram: great for the evaluation of cardiac contractility.
 - Stress echocardiogram: We measure cardiac contractility before administration of a stressing agent (dobutamine or adenosine); then, we measure cardiac contractility after the administration of the material. A decrease in contractility in one of the parts of the heart after the administration of dobutamine indicates ischemia.
 - Stress ECG: shows ST depression when the heart is stressed by exercise or dobutamine. However, this procedure is somewhat invasive.
 - Normal physiology:
 - In a normal heart, there is a large amount of cardiac reserve. Therefore, if you increase the heart's activity, the heart can compensate using the reserve flow. Therefore, there will be no decrease in perfusion.
 - In a diseased heart, the patient uses most of the cardiac reserve during rest. Therefore, during exercise, perfusion cannot be increased. This will appear as an ischemic area on a perfusion stress scan.
 - Note: exercise increases cardiac flow by 3 times; adenosine increases cardiac flow by 5 times.
 - The ischemic cascade (early to late)
 - Change in perfusion: the first apparent abnormality is a decrease in perfusion in response to stress testing. Therefore, a nuclear scan is the most sensitive test to detect cardiac disease. At this stage, the patient is usually asymptomatic or complains of non-specific symptoms.

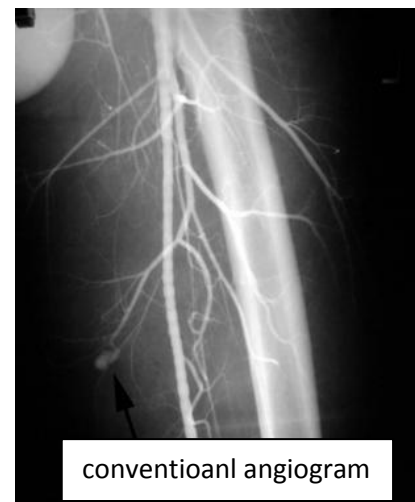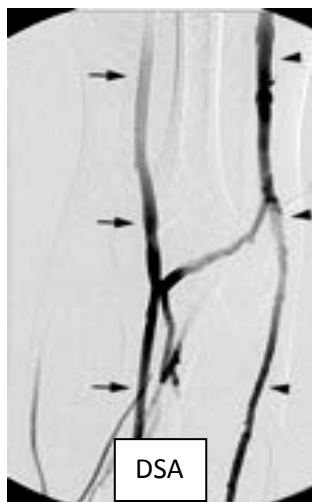
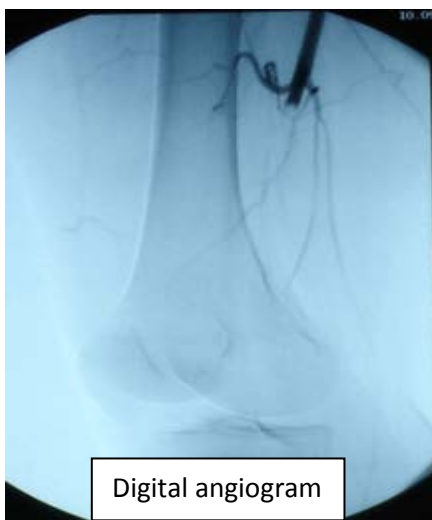- Altered contractility: systolic, then diastolic, followed by global dysfunction (both systolic and diastolic). This can be detected using an echocardiogram.
 - ST depression on stress testing: ECG
 - Angina pectoralis: indicates severe ischemia
- Materials used: Tc99 tetrofosmin, sestamibi, and thalium (analogue of potassium)
- How is the test done?
 - Administer radioactive material; take image before applying a stress
 - Take image after applying stress (adenosine or dobutamine)
- How to interpret the result:
 - If an area receives perfusion during rest and after stress, the test is negative and perfusion is normal
 - If the area receives perfusion before stress, and perfusion stops after stress: ischemia
 - If the area does not receive perfusion before stress and still doesn't receive perfusion after stress: infarct
- Using a PET scan, we can also calculate the contractility of the heart and ejection fraction.
- Bone scintigraphy (bone scan)
 - The main class of radiopharmaceuticals used in bone scans is the diphosphonates; there are many types of diphosphonates:
 - MDP: methylene diphosphonate
 - HEDP: hydroxyethelenediphosphonate
 - HMDP: hydroxymythelenediphosphonate
 - This material is injected IV, and it is distributed to areas where there is:
 - Increased blood flow
 - New bone formation (increased amount of hydroxyapatite crystals)
 - Interruption of sympathetic blood supply: complex regional pain syndrome
 - Used for detection of:
 - Trauma (stress fractures); however, the scan might be negative during the early phase of a trauma
 - Infection
 - Tumors that produce a bony reaction
 - We don't use it for the detection of osteolytic lesions. Osteolytic lesions cannot be visualized using a bone scan. The most important example is multiple myeloma. In cases of multiple myeloma, we use a PET scan. A PET scan will detect the increased metabolism at the tumor site.

- This type of scan is very sensitive; however, it is not specific unless interpreted within the clinical context.
 - We can see a neuroblastoma on a bone scan; however, metastases of this tumor can only be visualized using MEBG.
- Renal scans:
 - The radiopharmaceuticals used in a renal scan depend on the type of image.
 - In static images we use a DMSA scan. DMSA goes to the cortex
 - If you want to scan renal function in terms of secretion or filtration (dynamic scan), use MAG3 and DTPA.
- PET scans (details):
 - A PET is either taken with an MRI scan or a CT scan. This means that we never perform a PET scan alone. The machine itself has a CT or an MRI apparatus with it. This technique is called hybrid imaging.
 - The most important radiopharmaceutical used in a PET scan is fluorodeoxyglucose (FDG)
 - Acute and chronic cholecystitis (acute no filling) chronic filling but no removal
 - When do we use a PET scan?
 - In cases of cholecystitis:
 - Hepatobiliary PET scan using Tc99-mebrofebrin
 - In cases of acute cholecystitis, the gallbladder will not emit any radiation.
 - In cases of chronic cholecystitis, the gallbladder will take the material up but will not secrete it.
 - Used to assess lymphoma treatment: After two cycles of treatment, the lesions should disappear completely. If they don't disappear, use a more aggressive treatment or opt for surgical treatment.
 - Myocardial: viability and activity
 - Determine focus of a seizure
 - F-dopa PET scan: controversial, because we do not have enough clinical data about its significance. Can be used to visualize decreased basal ganglia activity in cases of Parkinson's disease.
- Radiation exposure:
 - There are no clinical studies that associate cancers with diagnostic doses of radiation. The only significant correlation is between radiation and thyroid cancer.

- The only patient you need to isolate is the patient receiving high doses of radioactive iodine for treatment of thyroid conditions. Other patients can interact with others without causing any damage to the others
- Doctors working with radiology have a similar life expectancy to those who don't. Therefore, working with radiation is not dangerous; it is less dangerous than passive smoking.

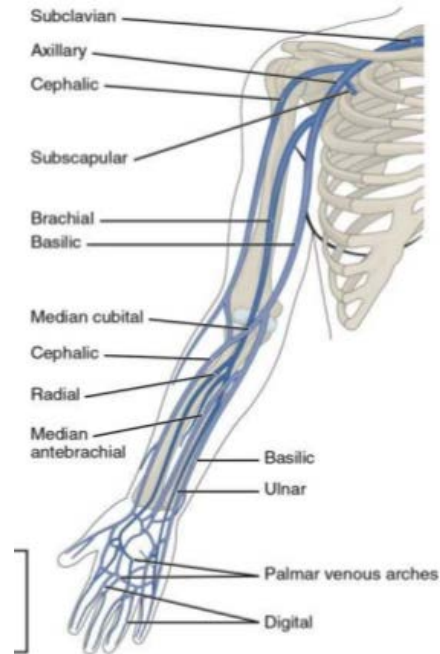
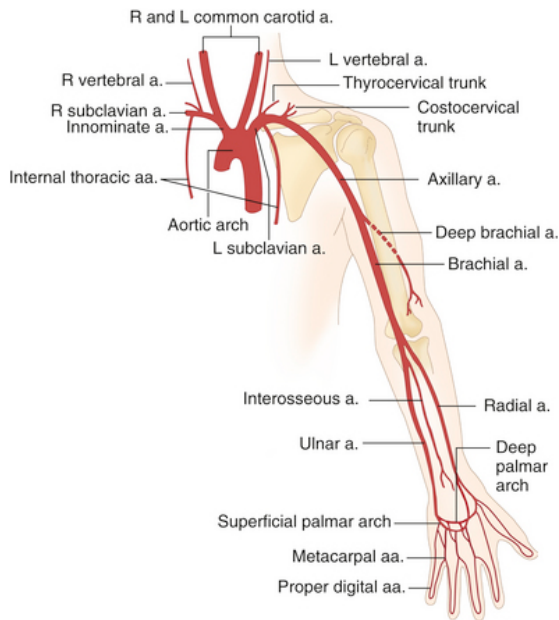
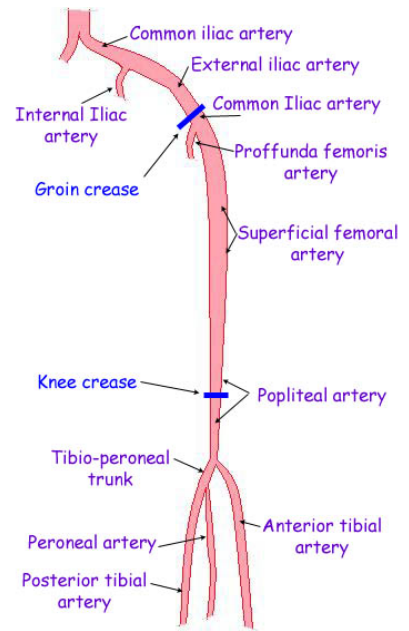
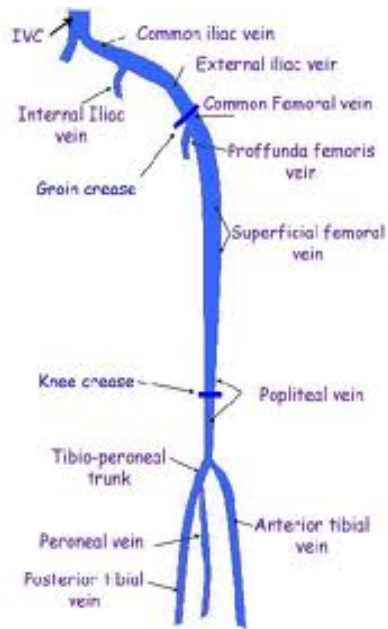
Vascular and interventional radiology

- Interventional radiology: A subspecialty of radiology that provides minimally invasive techniques with the help of imaging modalities to diagnose or treat certain conditions.
- Advantages:
 - o Minimally invasive: 8/10 procedures use skin incisions smaller than 5 mm.
 - o Local anesthesia
 - o Early recovery
 - o The interventions can be both therapeutic and diagnostic.
 - o Most of the time, the procedures are outpatient procedures (short recovery time)
- Common procedures:
 - o Stent placement
 - o Embolization: embolus in a vessel feeding a fibroid or a tumor
 - o Thrombolysis
 - o Balloon angioplasty: for stenosed arteries or veins
 - o Atherectomy: removal of an atheromatous plaque
 - o Nephrostomy
 - o Percutaneous biliary drainage
 - o Radiofrequency ablation
 - o Abscess drainage
 - o Percutaneous biopsies
- Angiography: An X-ray is used to examine the vessels. We use a contrast material to visualize the vessels. We can use it to image arteries or veins.
- Angiographic techniques:
 - o Conventional: In conventional angiography, the contrast material looks white. The bone looks white and we can easily visualize the medulla and cortex.
 - o Digital angiography: a computer inverts the color; therefore, both contrast material and bones look black. The bone can be differentiated into a cortex and medulla (clear visualization of the bone structure)
 - o DSA (digital subtraction angiography): the color of the contrast looks black; however, the computer "subtracts" the bony structures. The bone, can sometimes be seen; however, you cannot see a clear cortex and medulla.



- Contrast materials:
 - o High osmolar weight: can cause fluid shift and electrolyte imbalances
 - o Low osmolar weight: safer
- Contraindications to angiography:
 - o There is no absolute contraindication
 - o Relative contraindications include:
 - poor renal reserve
 - Abnormal coagulation profile
 - Allergy: either to contrast medium or any general allergic conditions
 - Metformin: if the patient is taking metformin and has poor renal function, the patient should stop metformin 2 days before the study and 2 days after study
- Preparation:
 - o NPO 4-6 hours before the procedure
 - o The patient needs to be on a trolley
 - o In hospital gown
 - o Groin shave
 - o Consent
 - o Well hydrated
 - o Should void before procedure
- Complications of angiography: (very low complication rate; 0.16%)
 - o Puncture site complications (ex:groin hematoma, A-V fistula,pseudoaneurysm).
 - o Contrast related complications (anaphylactic reaction).
 - o Catheter related complications (vessel dissection)
 - o Therapy related complications (CNS bleeding during thrombolysis)
 - o CNS complications: neurological deficits
- Post-procedural care:
 - o Compression on the puncture site
 - o The patient should stay in bed for 4 hours after the procedure
- Relevant clinical anatomy:
 - o Arterial anatomy:
 - Upper limb:
 - The subclavian vein continues until the end of the lateral border of the first rib
 - Beyond the lateral border of the first rib, the subclavian artery becomes the axillary artery
 - The axillary artery then becomes the brachial artery; until the level of the cubital fossa.
 - Beyond the cubital fossa, the brachial artery divides into the ulnar and radial arteries

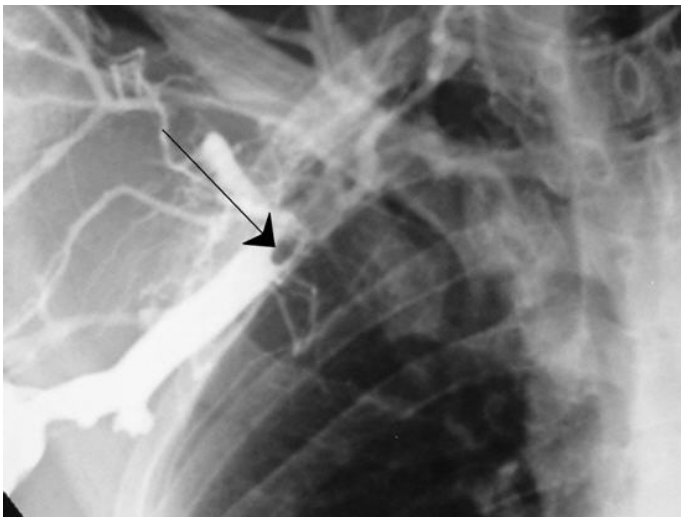- At the wrist, the radial and ulnar arteries form the superficial and deep palmar arches.
- Abdomen and lower limb:
 - When the aorta leaves the thoracic area, it becomes the abdominal aorta.
 - At the level of L4, the abdominal aorta divides into the right and left common iliac arteries
 - The common iliac arteries give rise to the internal and external iliac arteries
 - The external iliac artery continues until the level of the inguinal ligament
 - At the inguinal ligament, the iliac artery becomes the common femoral artery
 - The common femoral artery divides into the superficial femoral artery and profundafemoris artery
 - The superficial femoral artery continues until the popliteal fossa, where it becomes the popliteal artery
 - Beyond the popliteal fossa, the popliteal artery becomes the peroneo-tibial trunk.
 - The peroneo-tibial trunk gives rise to the anterior tibial artery, posterior tibial artery, and peroneal artery.
- Venous anatomy:
 - Upper limb:
 - The forearm contains basalic and median veins (superficially), and radial and ulnar veins (deep veins)
 - In the arm, the brachial veins and basilic vein join to form the axillary vein
 - The axillary vein become the subclavian vein
 - Abdomen and lower limb
 - The anterior tibial vein, posterior tibial vein, and peroneal vein join to form the tibeoperoneal trunk
 - The tibeoperoneal trunk continues to form the popliteal vein
 - The popliteal vein drains into the superficial femoral vein
 - The superficial femoral vein joins the deep femoral vein to form the common femoral vein
 - The common femoral vein drains into the external iliac vein
 - The external and internal iliac veins join to form the common iliac veins
 - The common iliac veins join to form the inferior vena cava



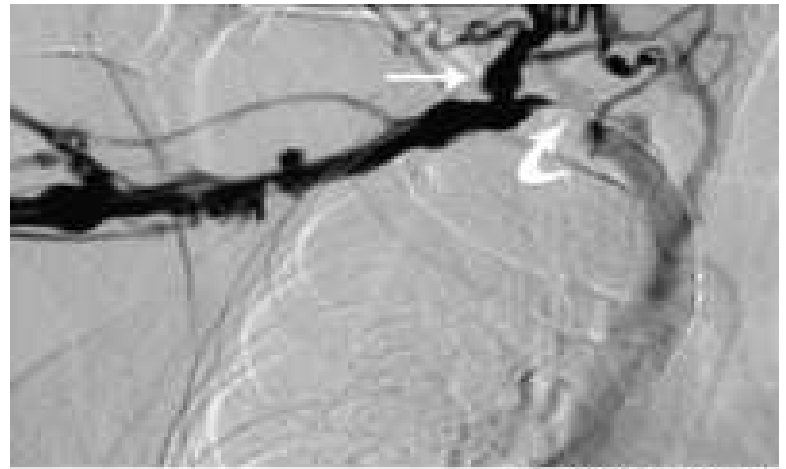
- How to differentiate an angiogram from a venogram:
 - o Veins have a wider lumen
 - o Veins look irregular (due to the presence of valves), while arteries look uniform. The only valveless vein in the body is the inferior vena cava (IVC)
 - o In the upper limb, the internal mammary artery (IMA) is a descending artery that has no corresponding vein. If you see the IMA, then the image is an arteriogram.
- Commenting on a study:
 - o Type of study (conventional, digital, or DSA)

- Arteriography or venography
 - Anatomical location (upper limb, lower limb, abdomen)
 - Defect or pathology in the picture
- Arteriography:
- Indications:
 - Disorders of the blood vessels
 - Arterial anatomy before surgery
 - Investigation of bleeding from the GI tract
 - Tumors: to visualize the feeding arteries of a tumor; can be used to embolize the arteries feeding a tumor
 - Technique (Seldinger technique)
 - We usually enter through the femoral artery (choice of artery is discussed later)
 - Insertion of a needle and a guidewire; the needle penetrates the artery (we actually perforate the artery)
 - The needle is slowly withdrawn until we see backflow
 - Take the needle out and insert a catheter over the guidewire
 - Take the guidewire out.
 - Why use the right femoral artery:
 - Easily accessible and superficial.
 - If bleeding happens after procedure, you can compress the artery easily.
 - Large caliber vessel
 - Well defined landmarks
 - Most angiographers are right handed
- Venography:
- Indications: thrombi in veins (VTE)
 - Technique: the contrast medium is injected into a small vessel in the dorsum of the hand or foot.
- Venous pathologies:
- VTE: a venous thromboembolism occurs when a thrombus or an embolus cause obstruction in a vein.
 - A thrombus is a blood clot that forms within the vessel itself.
 - An embolus is a blood clot that travels and blocks a vessel
 - DVT: thrombosis in the deep veins; it is a serious condition because it is associated with pulmonary embolisms.
 - DVT is most common in the lower extremities; however, it can be found in the upper extremities.

- DVT's are usually associated with Virchow's triad: a hypercoagulable state, endothelial cell injury, and stasis
- On angiography (appearance):
 - Filling defect: the thrombus appears as a well demarcated region that does not take up contrast. We can see blood flow beyond the filling defect.
 - Non-visualization: the supply beyond the area of the thrombus is completely gone. Non-visualization appears as a gradual tapering followed by inability to visualize the remainder portion of the vein.
 - To differentiate acute VTE's from chronic ones, we look at the presence of collaterals and the presence of faint opacifications.
 - In cases of a chronic VTE, due to the presence of collaterals, some blood flow might return. This blood flow is visualized as a faintly filled vein beyond the level of the cut-off.



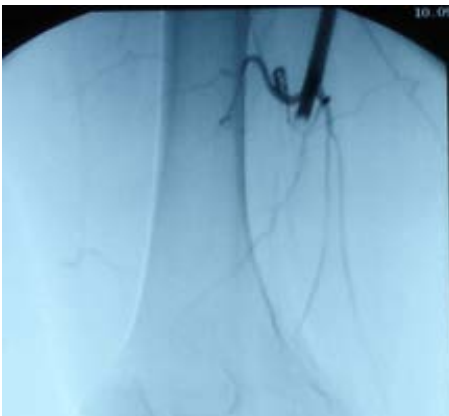A conventional venogram showing a thrombus in the right axillary/subclavian vein. Seen as a filling defect (black arrow). It is acute (no collaterals)



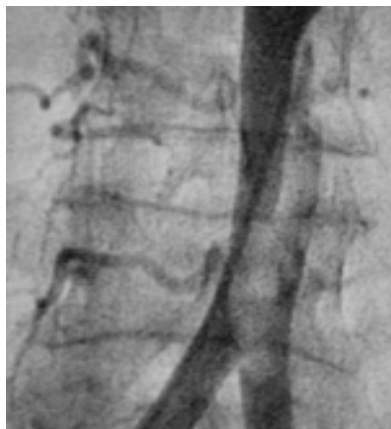A DS venogram showing a thrombus in the right axillary/subclavian vein. Seen as a non visualization (white curved arrow). It is chronic (notice the collateral at the straight white arrow), and the presence of faint opacification

- Arterial pathologies:
 - Peripheral vascular disease:
 - Disorders that interfere with natural flow of blood through peripheral vessels.
 - Patients can have arterial and venous disease.
 - Chronic condition

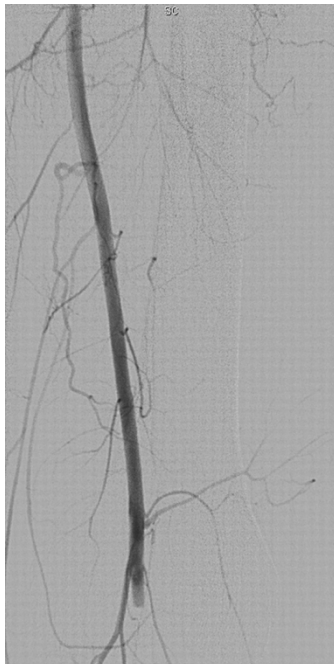
- Systemic manifestation of atherosclerosis
 - Arterial occlusive disease: can be acute or chronic
 - Fontaine classification:
 - I: Asymptomatic atherosclerotic lesion
 - II: Intermittent claudication:
 - mild (free walking distance > 100 - 200 m)
 - severe (walking distance less than 100 m)
 - III: Rest pain
 - IV: Trophic changes with necrosis & gangrene.
 - Arterial occlusive disease can be classified into:
 - Embolic:
 - Always acute
 - Emboli are the most common cause of acute arterial occlusion
 - Six P's of ischemia
 - Most emboli originate from the femoral artery (46%)
 - Emboli can be of a cardiac origin: MI or atrial fibrillation
 - Thrombotic:
 - Acute: 90% are caused by atherosclerosis; the clinical signs depend on the location and extent of thrombosis; however, they are generally less severe than acute embolic events.
 - Chronic
 - On angiograms:
 - Emboli:
 - Meniscus sign: the arterial supply seems to be cut off, and a concavity appears at the site of the embolus
 - Filling defect
 - Thrombi:
 - Acute: sharp cut off or non-visualization; no collaterals
 - Chronic: sharp cut off or non-visualization; collaterals present.



A digital arteriogram showing an acute embolic event in the superficial femoral artery; notice the meniscus sign

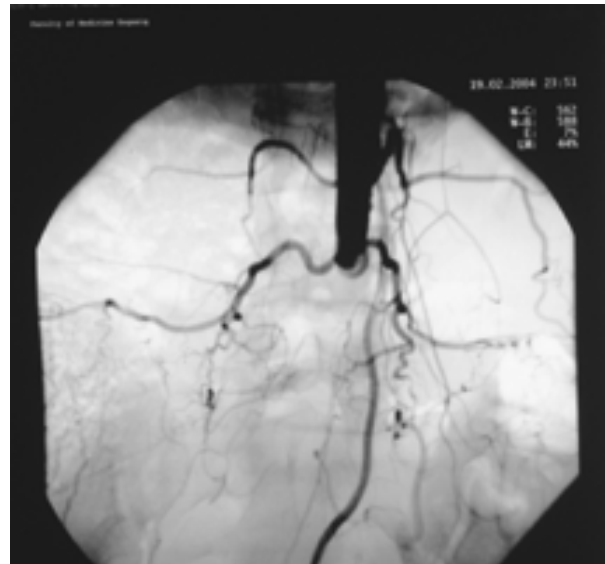


A DS arteriogram showing an acute embolic event in the abdominal aorta. Notice the filling defect.



A DS arteriogram showing an acute thrombotic event in the popliteal artery; notice the sharp cut off.

LT



A DS arteriogram showing an acute embolic event at the bifurcation of the abdominal aorta; notice the meniscus sign; this case is known as Leriche's syndrome

- Leriche's syndrome:
 - An acute occlusion at the level of the bifurcation of the abdominal aorta.
 - The classical triad is: buttocks claudication, impotence (erectile dysfunction), and absent femoral pulses.
- Aneurysms:
 - Defined as a dilation of an artery
 - Can be: fusiform or saccular(shape)
 - Can be classified into:
 - True: the aneurysm includes all the layers of the artery; they appear fusiform. The pathogenesis is usually due to degeneration of the media layer. The etiology is usually traumatic or iatrogenic.
 - False: they do not include all the layers of an artery; they appear saccular.
 - Aneurysms of the abdominal aorta are defined as dilation >3cm; aneurysms of the thoracic aorta are defined as dilations >4cm.
 - To study aneurysms we use a CT angiogram.
 - Aneurysms may dissect:
 - A dissecting aneurysm happens due to dissection of the intima or/and media layers.
 - This leads to the formation of a false and a true lumen separated by an intimal flap. The intimal flap extends between the two arterial walls.
 - The false lumen usually compresses the true lumen.
 - Any leakage of contrast outside the vessel is indicative of dissection.

- Popliteal aneurysms are the most common peripheral aneurysms. In 50% of the cases, they are bilateral.
- Many aneurysms can be repaired using interventional radiology techniques including endovascular repair.
- Other interventional radiology techniques:
 - Angioplasty
 - Therapeutic embolization
 - Vascular catheterization for infusion purposes
 - Percutaneous puncture or drainage
 - Vascular stents: used to treat stenosed arteries or veins
- IVC filters:
 - Filters inserted into the inferior vena cava to prevent PE. The usual entry point is the femoral vein
 - Indications:
 - Recurrent DVT
 - Contraindication to coagulation
 - Complications of anticoagulation
 - Complications:
 - Migration of the filter
 - Failure of the filter
 - Thrombosis
 - Groin complications
- Therapeutic embolization:
 - Arteries are occluded by introducing a variety of materials through a catheter placed in a selected artery.
 - Indications:
 - Tumors
 - Fibroids
 - Bleeding
 - Aneurysms
 - AV malformations
 - Complications:
 - Post embolization syndrome
 - Thrombi
 - Infection of embolized area
 - Reflux of embolic material

Chest X-ray

- Chest X-rays are the most common radiographs; however, they are the most difficult image to interpret.
- Using a systematic approach minimizes the chance of missing an abnormality.
- How to look at a chest X-ray?
 - o Documentation:
 - Date
 - Age: to determine the general age group of the patient (pediatric or adult) we look at the humeral epiphyseal plate; the presence of a radiolucent line within the humeral line tells you the patient is less than 20 years old.
 - Gender
 - Technical factors:
 - Exposure: determined based on the visibility of spinous processes. If the spinous processes are barely seen, the image has a good exposure. If the spinous processes are very clear, there is over-exposure. If the spinous processes cannot be seen at all, the exposure is low.
 - Centralization and rotation: the spinous processes should lie between the medial ends of both clavicles. If the medial end of one clavicle is closer to the spinous process than the other one, the patient might be slightly rotated. If the patient is rotated, a false diagnosis of cardiomegaly might be made (the heart appears larger when the patient rotates)
 - Inspiratory effort: judged by how many ribs can be visualized. If you can visualize 6-8 anterior ribs and 8-10 posterior ribs, the patient has a good inspiratory effort; sometimes, an expiratory phase image might be needed (in cases of a small pneumothorax)
 - o Position: the standard position is erect PA. If the patient cannot stand erect, a supine AP view might be suitable. Sometimes, a lateral view is taken to determine the precise location of a pathology.
 - o How to differentiate between an AP and a PA view:
 - Usually, the view is written on the top of the radiograph.
 - Look at the inferior border of the scapula. If the inferior border of the scapula is outside the lung field, the radiograph is PA.
 - If the inferior border of the scapula is within the lung field, we usually assume that the radiograph was taken in the standard PA view; however, we look at other signs (mentioned later) to determine if the radiograph was taken in an AP view.
 - o Look at:

- Lungs
 - Pleura
 - Mediastinum (heart shadow)
 - Bones
 - Soft tissue
- Look at the hidden areas (usually missed):
 - Retrocardiac masses
 - Lungs apices
 - Subdiaphragmatic space
- For a better interpretation of the radiograph, the lungs are divided into three zones (they DO NOT correspond to the lobes):
 - Superior zone: the first 2 intercostals
 - Middle zone: the middle 4 intercostals
 - Lower zone: the remaining portion of the
- Lungs anatomy:
 - The right lung:
 - Divided into three lobes: upper, middle and lower
 - Has two fissures: the transverse fissure separates the upper lobe from the middle lobe. The oblique fissure separates the middle lobe from the lower lobe.
 - The left lung:
 - Divided into two lobes: the upper lobe and lower lobe. The upper lobe has a structure called the lingula. The lingula is part of the upper lobe and corresponds to the middle lobe of the right lung.
 - The lobes are separated by a single fissure; the transverse fissure.
 - On a PA chest X-ray, the lower lobes occupy a wedge shaped area at the periphery of the inferior (lower) zone of the lungs. The lateral view is the best view to visualize the lower lobes.
- How is an AP view (supine) different from a PA view?
 - On an AP view, the heart shadow looks exaggerated due to divergence of X-ray beams
 - A pleural effusion will look as an increased density in the hemithorax; on an AP view it appears as an obliteration of the costophrenic angles (details in the pathologies section)
 - A pneumothorax is hard to detect on an AP view. The air will accumulate in front of the lungs, and it might be missed.
 - On an AP view, the diaphragm will appear elevated, and the lung volumes will appear smaller than they are
 - The upper zones look prominent on an AP view.
- Radiological divisions of the mediastinum:

- Anterior in front of the anterior pericardium and trachea
- Middle: within the pericardial cavity, including the trachea
- Posterior: behind the pericardium and the trachea.
- Pathologies on a chest X-ray:
 - Opacities:
 - Opacities indicate a pleural effusion, consolidation, or lung collapse (loss of volume)
 - They appear radio-lucent due to high attenuation and low penetration.
 - Radiolucencies:
 - Indicate a pneumothorax or a tension pneumothorax.
 - They appear black due to high penetration and low attenuation.
 - Usually associated with loss of vascular markings on the lung.
 - Distortion of normal anatomical structures.
- Opacities:
 - Description:
 - Describe the location (upper, middle, or lower zone)
 - Shape
 - Borders
 - Density: compare the density of the opacity to the mediastinum. If the opacity is darker than the mediastinum, we call it faint. If it the same color or brighter than the mediastinum, we call it dense.
 - Homogeneity
 - Comment on the four following features:
 - Presence of calcifications inside the opacity
 - Presence of cavitations; there is a wide differential diagnosis for cavitations. The most important differential diagnoses are sarcoidosis and TB.
 - The presence of an air bronchogram: an air bronchogram is defined as the shadow of bronchi and bronchioles. This shadow appears as a result of fluid collection inside the alveoli. As a rule, the presence of an opacity with an air bronchogram is diagnostic of a consolidation.
 - Silhouette sign: a silhouette appears when the lung parenchyma covers an adjacent structure. It helps in locating the anatomical position of the lesion.
 - Silhouettes of the left lung:
 - Left heart border: lingular pathology; if the opacity extends superiorly, the whole upper lobe is affected
 - Left heart border + diaphragm: lower lobe pathology
 - Silhouettes of the right lung:
 - Right heart border: middle lobe pathology

- Right heart border + diaphragm: lower lobe pathology or combined middle and lower lobes pathology
 - No silhouette: upper lobe pathology
- How to differentiate between the types of opacities:
 - Consolidation:
 - The presence of an opacity with an air bronchogram is diagnostic of a consolidation.
 - If there is no air bronchogram, look for signs of collapse. If they are absent, then it is a consolidation.
 - Collapse: (signs); can be caused by a foreign body or a tumor.
 - Transposition of the transverse fissure
 - Traction of the hilum
 - Tenting of the right diaphragm: only seen in upper and middle lobe pathologies. In cases of left upper lobe pathologies, the diaphragm is not tented
 - Tracheal or mediastinal deviation towards the side of the lesion. Normally, 1/3 of the heart border lies to the right and 2/3 of the heart's border lie to the left. Alteration of this ratio, indicates deviation.
 - Pleural effusion:
 - Erect:
 - They appear as a homogenous dense opacity.
 - Blunting or obliteration of the costophrenic angles; the costophrenic angles are sharp acute angles. If they appear rounded or obtuse, this indicates pleural effusion.
 - The presence of meniscus sign: fluid accumulation in the pleura will make the overlying lung parenchyma look convex inferiorly. We need 200-300mL of fluid for the meniscus sign to be obvious
 - If the pleural effusion is large, the mediastinum might be shifted to the contralateral side.
 - Supine:
 - Dense hemithorax: the density appears graded being most dense inferiorly.
 - Loss of costophrenic angles and meniscus sign
 - Small effusion:
 - Small effusions might be missed; therefore, if a small effusion is suspected a lateral decubitus radiograph is taken.

- The effusion will appear as a straight dense line along the periphery of the lung.
- Radiolucency: a radiolucent lesion indicates a pneumothorax or a tension pneumothorax.
 - Pneumothorax (criteria)
 - A radiolucent area extending at the periphery of the lung parenchyma
 - Visualization of the visceral pleura: the pneumothorax separates the parietal pleura from visceral pleura. The visceral pleura will appear as a thin radio-opaque line along the periphery of the lung
 - Loss of vascular markings beyond the visceral line
 - Tension pneumothorax:
 - Major criteria:
 - Mediastinal shift to the contralateral side
 - Shifting of the heart ratio (1/3:2/3)
 - Minor criteria:
 - Flattening of the ipsilateral diaphragm
 - Widening and flattening of the intercostal spaces on the ipsilateral side
 - Congestion (increased vascular markings) of the hila

- Hila:

- Anatomical Vs. radiological hilum:
 - The anatomical hilum includes the pulmonary artery, pulmonary vein, lymph nodes, nerves, and bronchus
 - The radiological hilum includes the pulmonary vessels only.
- Hilar markings:
 - The hila appear as hyperdense regions lateral to the heart borders. This hyperdensity is the result of the density of the vessels.
 - The left hilum is 1cm higher than the right hilum
 - The right hilum is more obvious than the left hilum because the left heart shadow is larger and can hide hilar markings.
- Hilar abnormalities:
 - Distortion of the hila can indicate fibrosis or lung collapse
 - If one hilar appears prominently larger or denser than the other hilum, then there is an abnormality. This increased density is due to the congestion of pulmonary vessels.
- Diaphragm:

- The diaphragms appear as dome-like radio-opaque structures at the inferior surface of the lung.
 - The right diaphragm is usually 2.5 cm higher than the left diaphragm because it is pushed upwards by the liver.
 - If the right and left diaphragm are on the same level, the left diaphragm is elevated and might indicate a collapse in the left lung.
 - Diaphragmatic elevation vs. diaphragmatic eventration:
 - Elevation of the diaphragm is defined as total upward displacement of the diaphragm. It indicates diaphragmatic muscle paralysis or lung collapse
 - Eventration of the diaphragm: dome like elevation in the central portion of the diaphragm. It is a normal finding in older patients (due to weakness of the diaphragmatic muscles)
- Pleura:
 - The pleura follow the contour of the lungs.
 - Any thickening in the pleura is indicative of pleural nodules; to detect thickening we look at the pleural margins.
 - The presence of an air fluid level in the pleura indicates hydro-pneumothorax.
- Diagnosis of heart failure on chest X-ray:
 - Cardiomegaly: the heart shadow usually occupies less than 50% (adults) or 60% of the chest. The ratio is measured by dividing the widest diameter of the heart base by the widest diameter of the chest.
 - Pleural effusion
 - Cephalization and congestion of lung vasculature: on a normal chest radiograph, the lower vessels appear clearer than the superior vessels due to the effect of gravity. In cases of heart failure, the superior vessels appear more radio-opaque due to pulmonary venous congestion

Musculoskeletal Radiology

- Arthritis:
 - Arthritis can be divided into:
 - Inflammatory:
 - Multiple joints:
 - Seronegative
 - Seropositive
 - Single joint: septic arthritis
 - Non-inflammatory (degenerative):
 - Typical
 - Atypical
 - General features of inflammatory arthritis:
 - Uniform joint space loss across the articulation surface
 - Bone erosions: discontinuation of the bony cortex
 - Osteopenia: loss of bone density
 - Soft tissue swelling
 - Features of multiple joints seropositive arthritis; (Rheumatoid arthritis)
 - General features of inflammatory arthritis
 - Resorption of ulnar process
 - Absence of osteophytes: no extra bone formation
 - Deformities:
 - Subluxation of MCP
 - Z deformity
 - Atlanto-axial instability:
 - A C-spine X-ray is taken to look at C1/C2
 - It is considered an unstable that may cause cord compression
 - Abnormal values: >3mm in adults, >5mm in pediatric patients
 - Features of multiple joints seronegative arthritis: (ankylosing spondylitis)
 - General features of inflammatory arthritis
 - Sacroiliitis:
 - The earliest sign
 - Bilateral, symmetrical
 - Begins in the superior part of the joint then extends inferiorly
 - Spine signs:
 - Lateral view:
 - Squaring of anterovertebral wall due to bridging syndesmophytes across the anterior longitudinal ligament
 - Shiny corner sign due to discovertebral junction sclerosis at corners of the vertebrae

- AP view:
 - Bamboo sign: due to ossification of the outer layer of annulus fibrosis
 - Dagger sign due to ossification of interspinous ligaments
 - Trolley track sign due to facet joint fusion
- To differentiate between seropositive and seronegative arthritis:
 - Seronegative arthritis involves the DIP
 - Seronegative arthritis is bilateral asymmetrical
- Single joint inflammatory arthritis (septic arthritis): general features of inflammatory arthritis involving one joint only
- Degenerative arthritis:
 - Typical degenerative arthritis:
 - Usually affects the elderly
 - Affects weight bearing joints mainly. Most commonly involved joints are the knee (medial side) and hip joints
 - General features:
 - Asymmetrical joint space loss
 - Subchondral sclerosis
 - Subchondral cyst
 - Osteophyte formation
 - Atypical degenerative arthritis:
 - Affects young patients
 - Affects atypical joints; midfoot, first metatarsal
 - Causes:
 - Neuropathic:
 - Caused by DM; due to repetitive trauma to the area caused by sensory loss
 - Affects midfoot joints: navicular, cuboidal, cuniforms
 - Has general features of degenerative arthritis
 - Bone fragmentation
 - Subluxation
 - Vascular calcifications
 - Crystal deposition disease; gout:
 - Punched out erosions with sclerotic rim
 - Preserved joint space
 - Soft tissue swelling
 - Formation of tophi: it is a sign of chronic disease caused by soft tissue swelling around the joint
 - Trauma

- Hemophilia

- Bone lesions:

- To describe a bone lesion, we comment on:

- Borders:
 - Well defined: benign
 - Ill defined: aggressive
- Transition zone:
 - Narrow: benign
 - Wide: aggressive
- Sclerotic rim
- Background:
 - Sclerotic; white
 - Lytic; black
- Periosteal reaction (a sign of an aggressive lesion):
 - Codman's triangle
 - Sun-burst appearance (hair-on-end sign)
 - Multi-lamellated layers; onion peel sign
 - Single peri-osteal layer reaction
- Soft tissue extension (a sign of an aggressive lesion)

- Aggressive bone lesions:

- Malignant:

- Osteosarcoma:
 - Age: <20 (primary); in the elderly (metastasis)
 - Ill-defined border
 - No sclerotic rim
 - Usually has a sclerotic background
 - Periosteal reaction in the form of Codman's triangle or Sun burst appearance
 - Soft tissue extension might be seen
- Ewing's sarcoma:
 - Ill-defined border
 - Wide transition zone
 - No sclerotic rim
 - Usually has a lytic background
 - Periosteal reaction in the form of onion peel sign
 - Soft tissue extension can be seen
 - The patient can have fever and leukocytosis; therefore, it is hard to differentiate from osteomyelitis and imaging is not conclusive.

- Aggressive non-malignant bone lesions:

- Osteomyelitis:
 - An aggressive lesion
 - First signs on X-ray appear after 10 days of the disease. Before 10 days, the X-ray is completely normal
- Benign bone lesions:
 - Osteoid osteoma:
 - Well defined border
 - Narrow transition zone
 - Background: intercortical radio-lucent nidus
 - Fusiform thickening of the bony cortex
 - No periosteal reaction
 - No soft tissue extension
 - Characterized by pain that increases during the night, and is released by NSAIDs
 - Non-ossifying fibroma (NOF):
 - Well defined border
 - Narrow transition zone
 - Septated lesion
 - No periosteal reaction
 - No soft tissue extension
 - Usually asymptomatic
- Metabolic bone diseases:
 - Rickets:
 - Diffuse osteopenia
 - Cupping of metaphysis
 - Fraying and irregularity of the metaphysis
 - Widening of the growth plate
 - Bowing of the limbs
 - Ricketic rosary: ossification of the chostochondral junction
 - Delayed appearance of carpal ossification centers; usually 2 are present at birth
 - Hyperparathyroidism:
 - Diffuse osteopenia
 - Bone resorption
 - Sub-periosteal resorption of the radial aspect of the middle phalanx of the 2nd, 3rd, and 4th fingers
 - Resorption of the termina tuft of the distal phalanx
 - Brown tumors that appear as multiple lytic lesions
 - Focal bone resorption
 - Skull sign: salt and pepper appearance

- Rugger Jersey spine: diffuse osteopenia of the vertebrae with subperiosteal endosteal plate sclerosis
- Looser sign/Looser zones: a fracture line that appears along the neck of femur