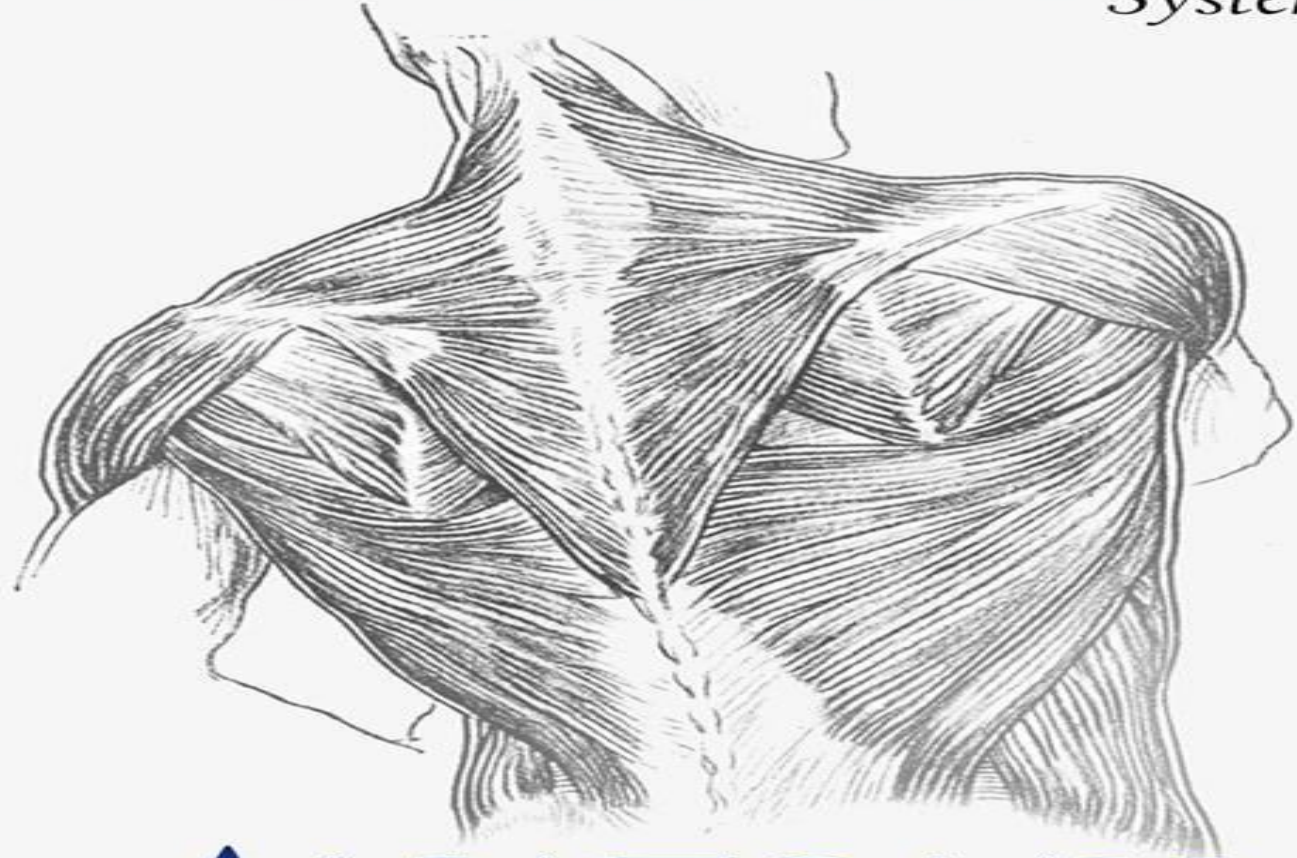


The Skin and
MUSCULOSKELETAL
System



ANATOMY

SLIDES
SHEET

DOCTOR: **Dr. Amjad**
DONE BY:

Number #6-Contents of the Posterior Fascial Compartment of the Thigh

Contents of the Posterior Fascial Compartment of the Thigh

1-Muscles:

❖ Biceps femoris

❖ Semitendinosus

❖ Semimembranosus

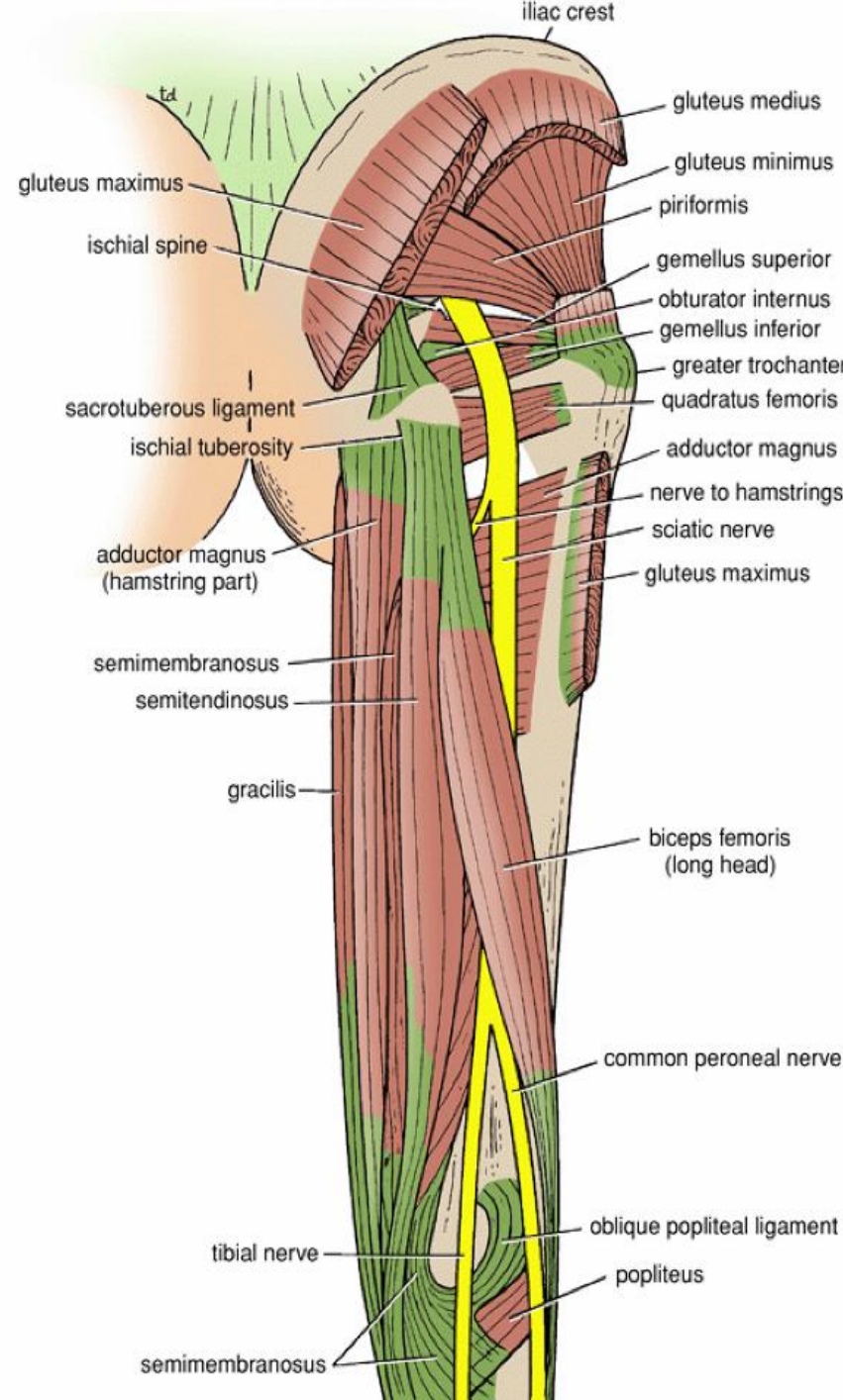
❖ a small part of the adductor magnus

(hamstring part

or ischial part)

2-Blood supply: *Branches of the profunda femoris artery*

3-Nerve supply: *Sciatic nerve*



Biceps femoris

Origin: two heads

1-Long head: ischial tuberosity

2-Short head: linea aspera, lateral supracondylar ridge of shaft of femur

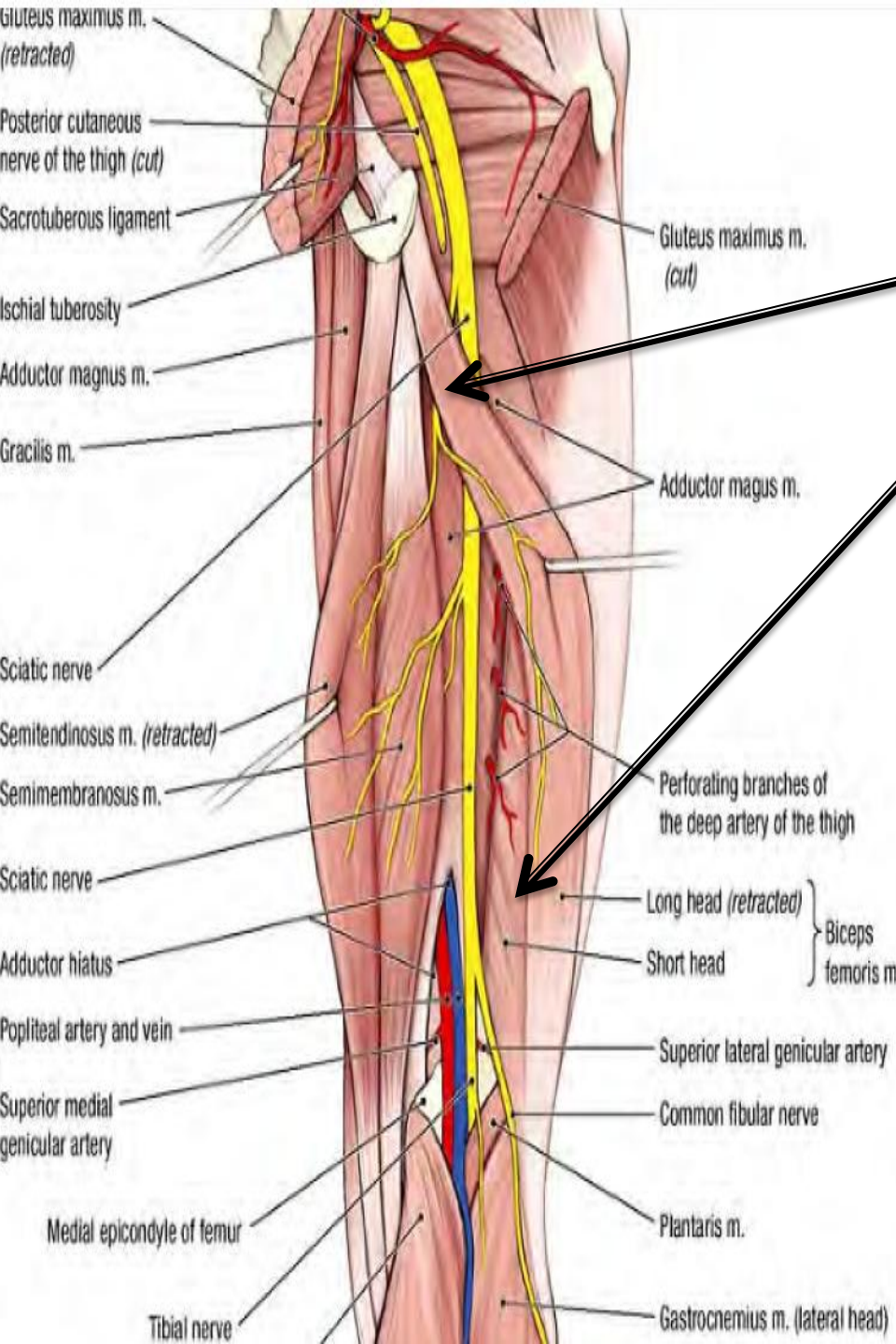
Insertion: Head of fibula

Nerve supply:

Long head: tibial portion of sciatic nerve

Short head: common peroneal portion of sciatic nerve

Actions: Flexes and laterally rotates leg at knee joint; long head also extends thigh at hip joint



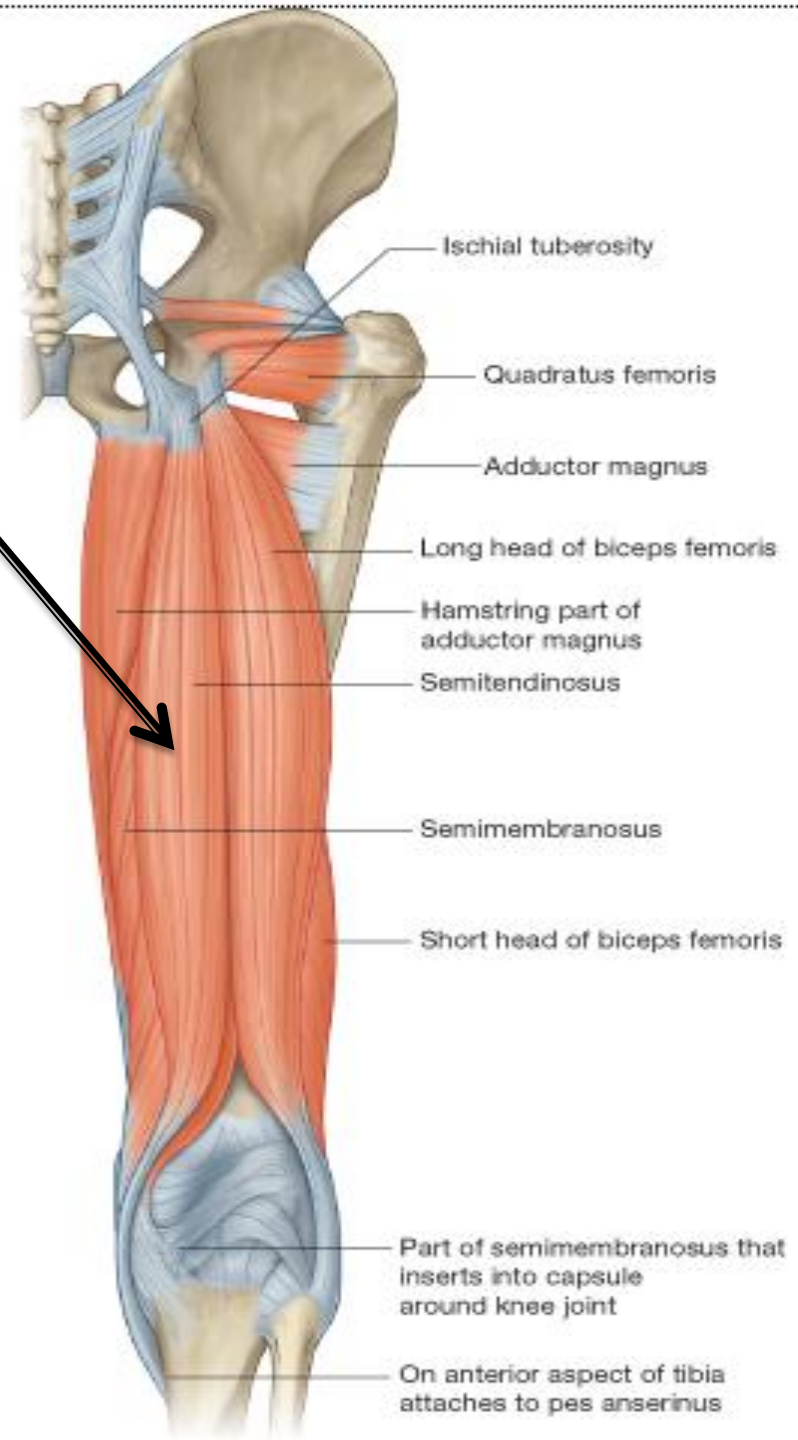
Semitendinosus

Origin:
Ischial tuberosity
Where?

Insertion:
Upper part of medial surface of
shaft of tibia
(SGS area)

Nerve supply: Tibial portion of
sciatic nerve

Actions: Flexes and medially
rotates leg at knee joint;
extends thigh at hip
joint



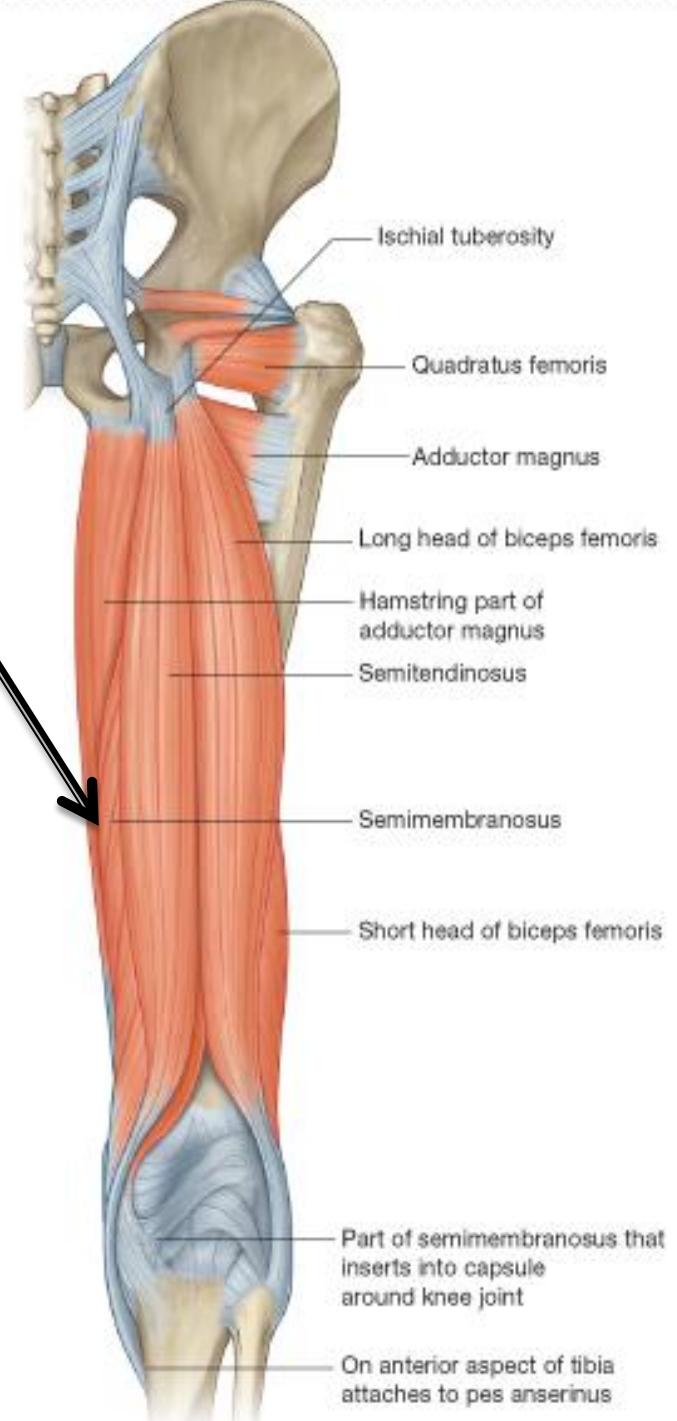
Semimembranosus

Origin: Ischial tuberosity, where?

Insertion: Medial condyle of tibia

Nerve supply: Tibial portion of sciatic nerve

Actions: Flexes and medially rotates leg at knee joint; extends thigh at hip joint



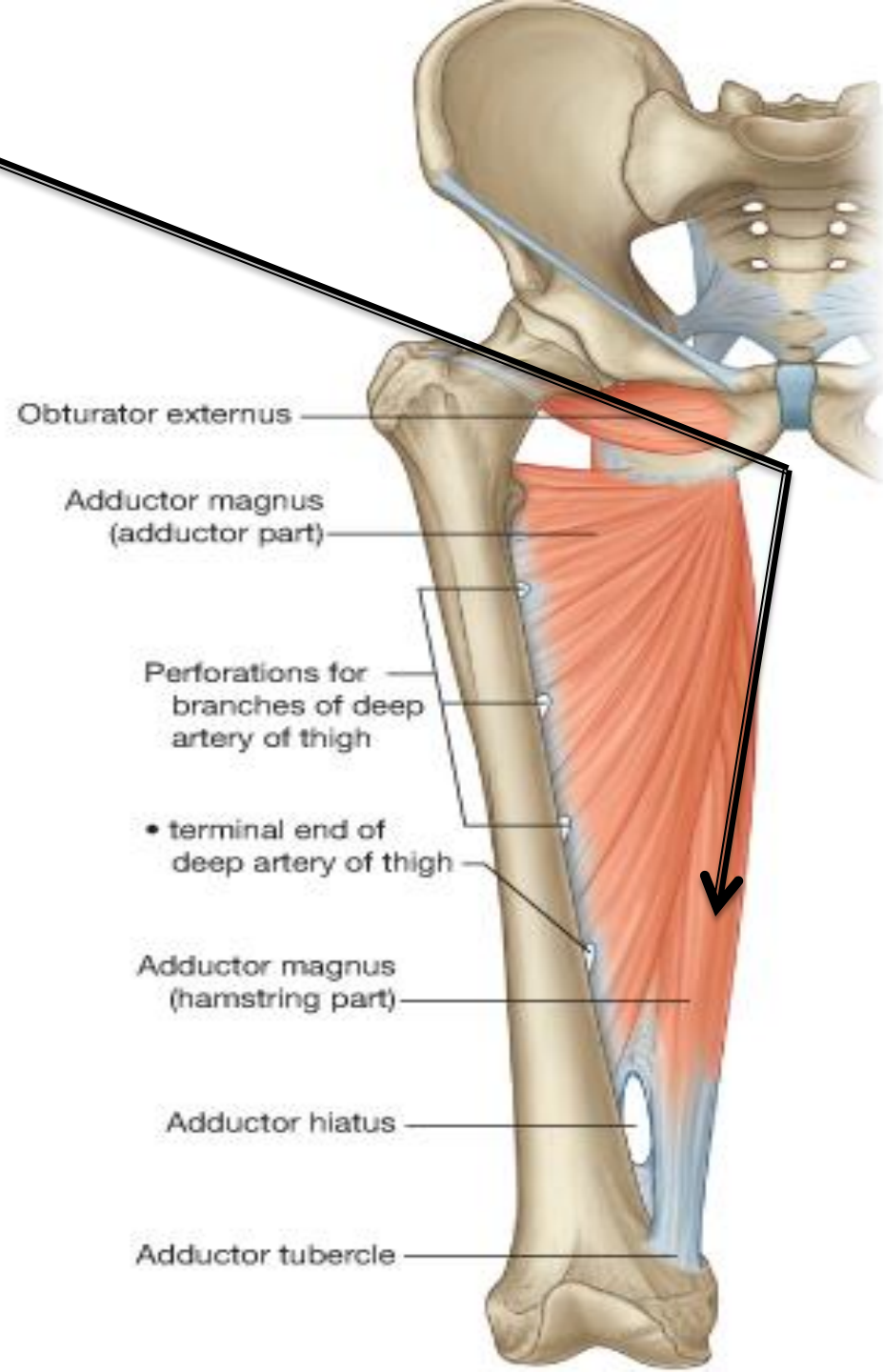
**Adductor magnus
(hamstring portion)
Or ischial part**

Origin: Ischial tuberosity

Insertion: Adductor tubercle of femur

**Nerve supply: Tibial portion of sciatic
nerve**

**Actions: Extends thigh at hip
joint
Does it flex the knee?**



Pay attention to the fact that the muscles of the thigh are designed

To act on the knee joint

For example, quadriceps femoris occupies the anterior compartment of the thigh but its

Main action is **to extend the knee joint**

The same should be considered for the muscles of the posterior compartment of the thigh

Although they occupy the posterior compartment of the thigh

Their main function is to **flex the knee joint**

Now think!

Which muscles will rotate the knee joint medially and laterally?

Keep in your mind that when the knee joint is extended medial and lateral rotation is not possible!

The joint said to be locked

Therefore, we need to unlock the extended (locked) knee joint

A small muscle called **popliteus** unlocks the knee joint by rotating the femur on the tibia laterally before any flexion of the knee can take place

Now the joint said to be unlocked

Only now when the knee joint is semiflexed

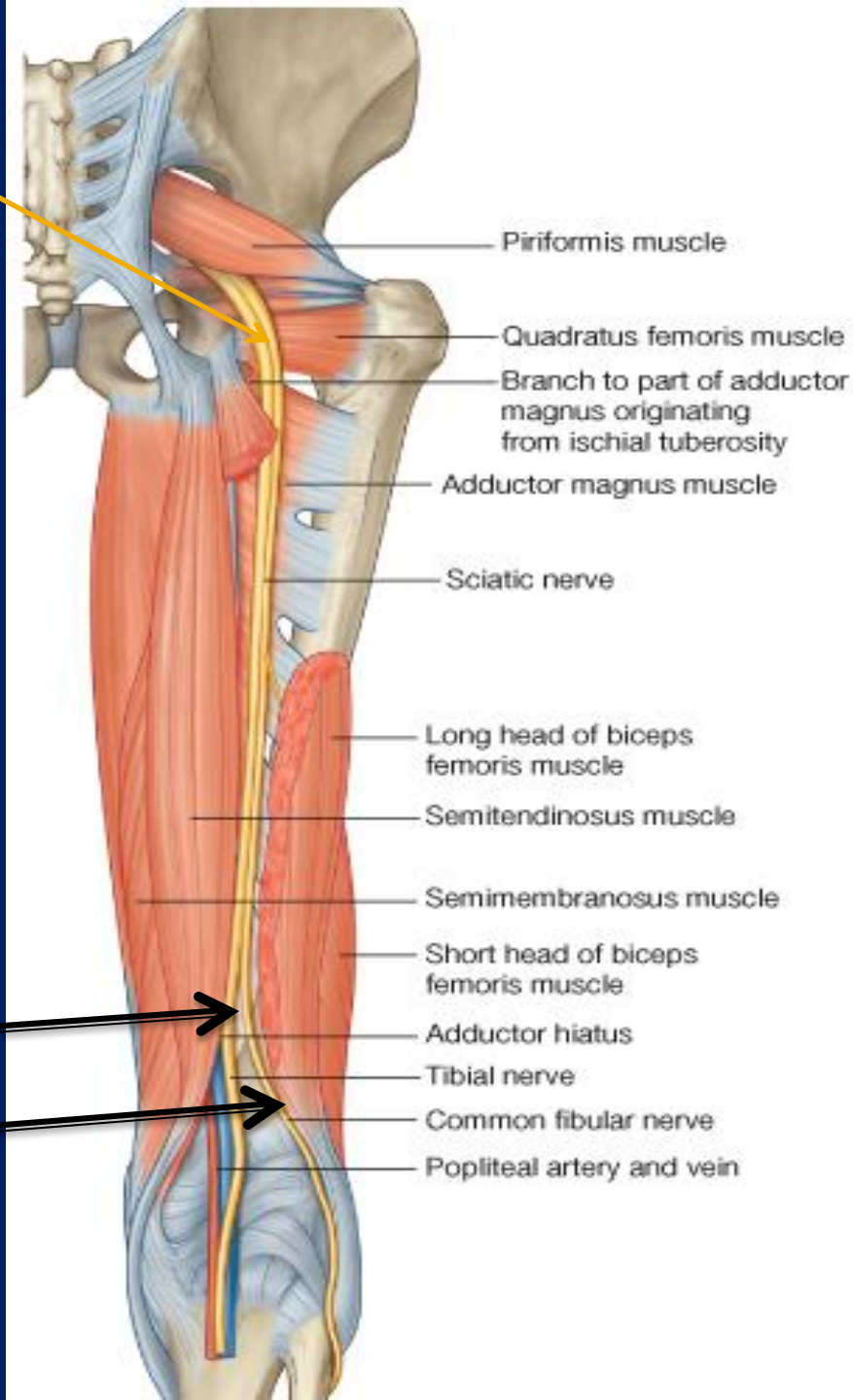
The biceps femoris **can act as lateral rotators of the leg**

The semimembranosus and semitendinosus **can act as medial rotators of the leg**

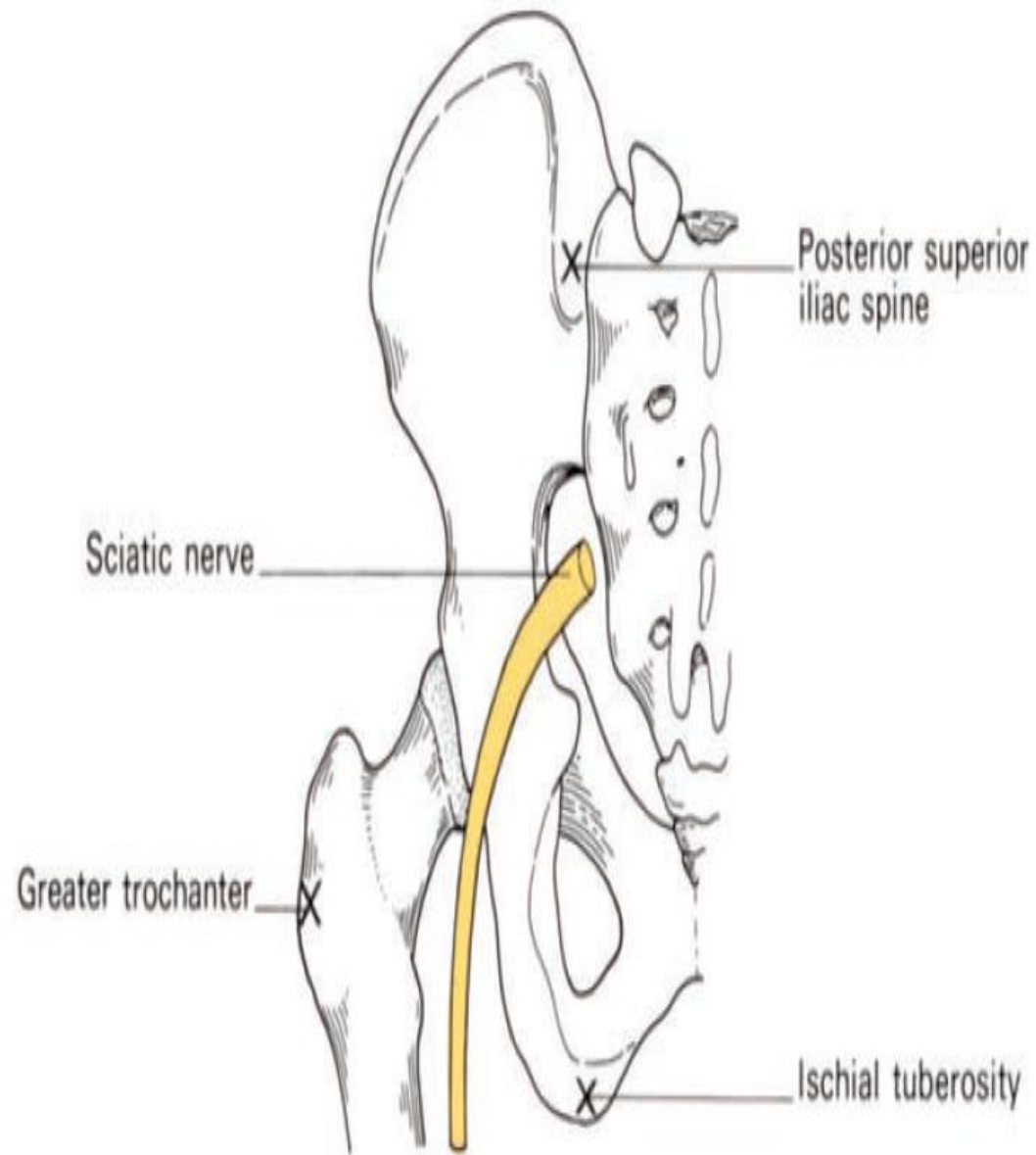
Sciatic Nerve

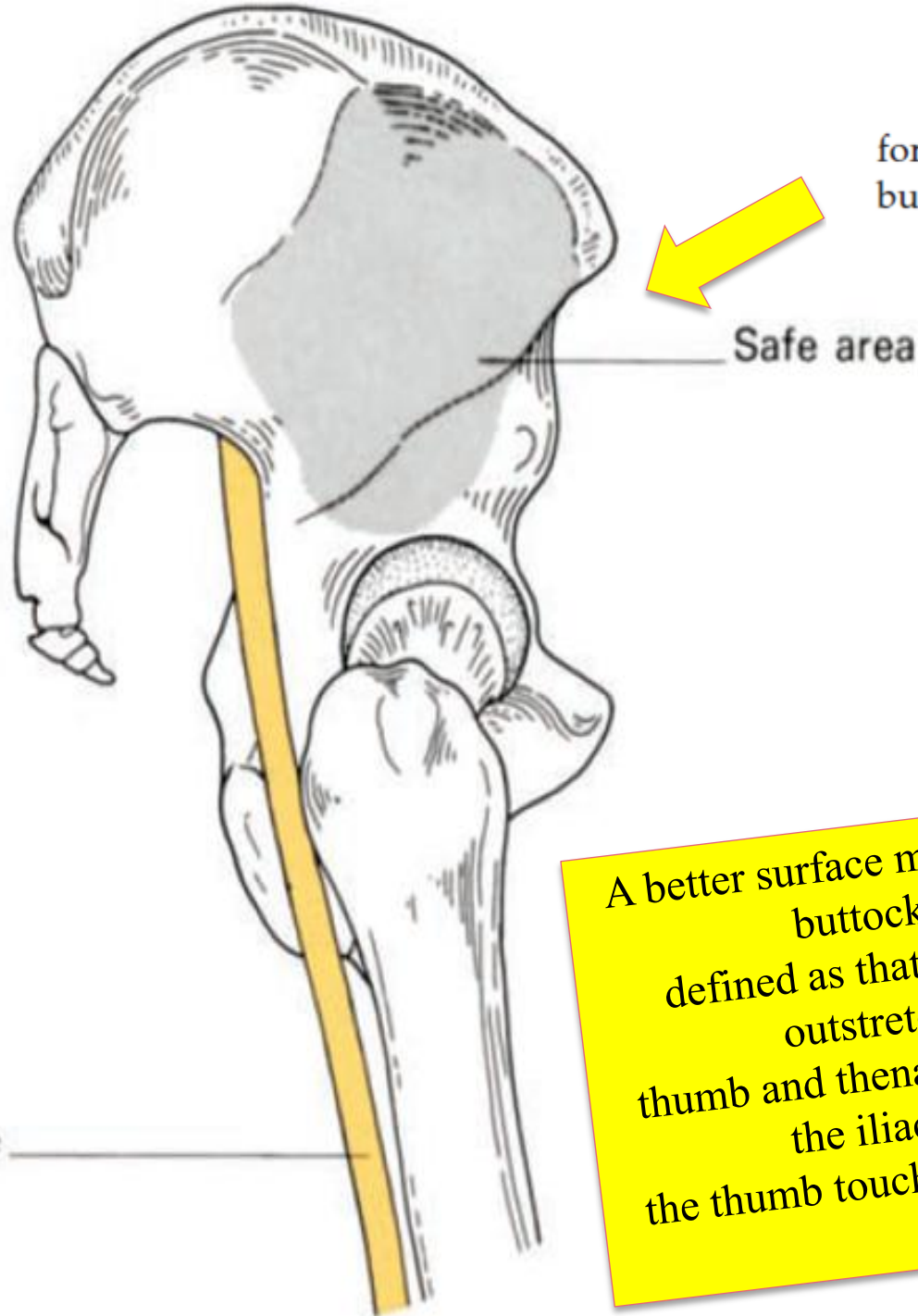
- A **terminal** branch of the **sacral plexus** (L4 and 5; S1, 2, and 3)
- Emerges from the pelvis through the lower part *of the greater sciatic foramen below the piriformis muscle*
- It is the largest nerve in the body and consists of the **tibial** and **common peroneal** nerves bound together with fascia.

- *Commonly terminates in the middle of the thigh* by dividing into **Tibial Nerve** (medial popliteal nerve) and **Common peroneal** (lateral popliteal nerve **ALSO CALLED common fibular nerve**)



The surface markings of the sciatic nerve. Join the midpoint between the ischial tuberosity and posterior superior iliac spine to the midpoint between the ischial tuberosity and the greater trochanter by a curved line; continue this line vertically down the leg—it represents the course of the sciatic nerve.





The 'safe area' for injections in the buttock.

A better surface marking for the 'safe area' of buttock injections can be defined as that area which lies under the outstretched hand when the thumb and thenar eminence are placed along the iliac crest with the tip of the thumb touching the anterior superior iliac spine

Posterior Cutaneous Nerve of the Thigh

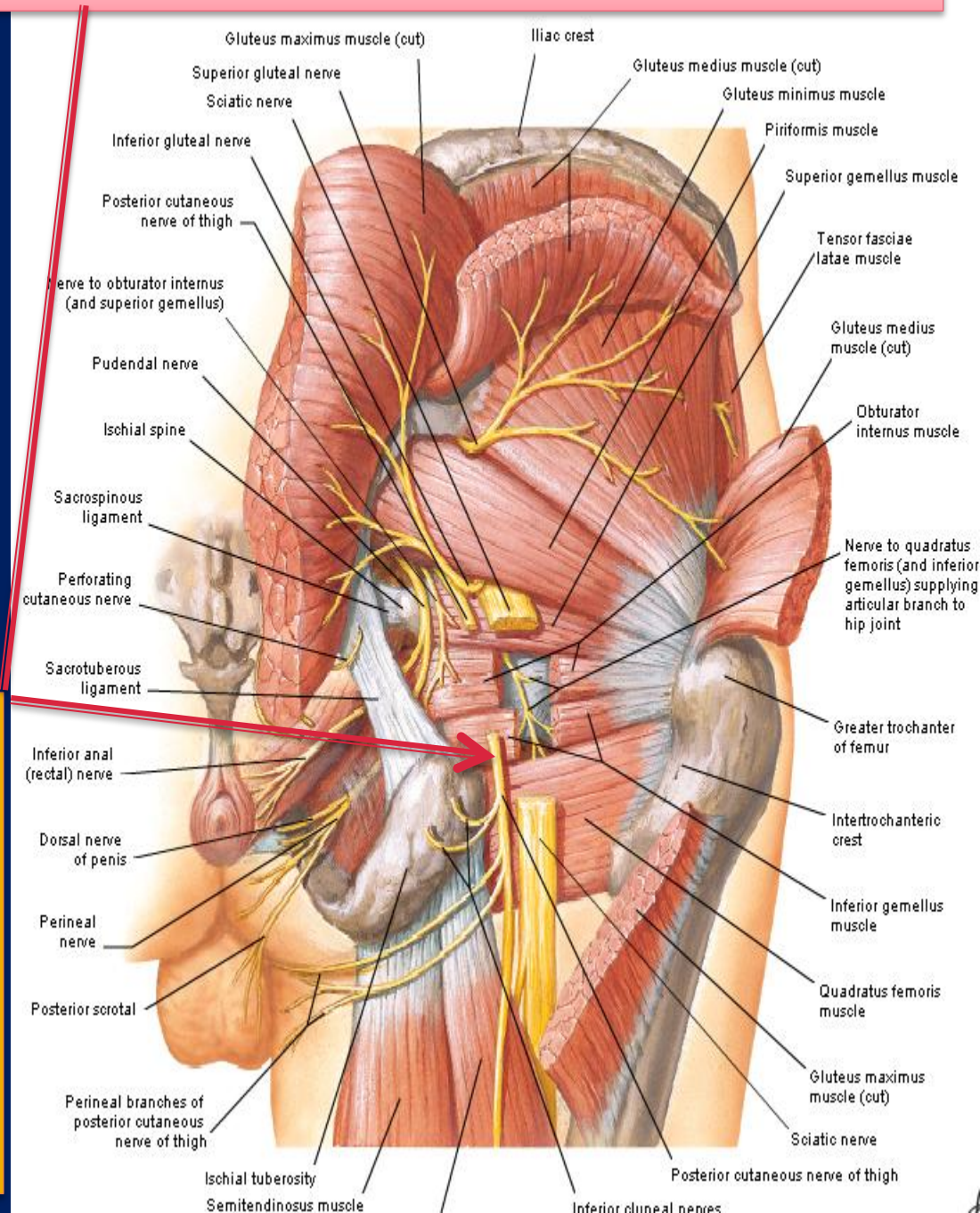
➤ A branch of the sacral plexus

S1,2,3.

➤ Enters the gluteal region through the lower part of the greater sciatic foramen below the piriformis muscle

➤ It passes downward on the posterior surface of the sciatic nerve and runs down the back of the thigh beneath the deep fascia.

➤ In the popliteal fossa it supplies the skin **OVER THE BACK OF THE** thigh and upper part of the leg.



THE POPLITEAL FOSSA

Popliteal Fossa

Is a diamond-shaped intermuscular space situated at the back of the knee

Boundaries

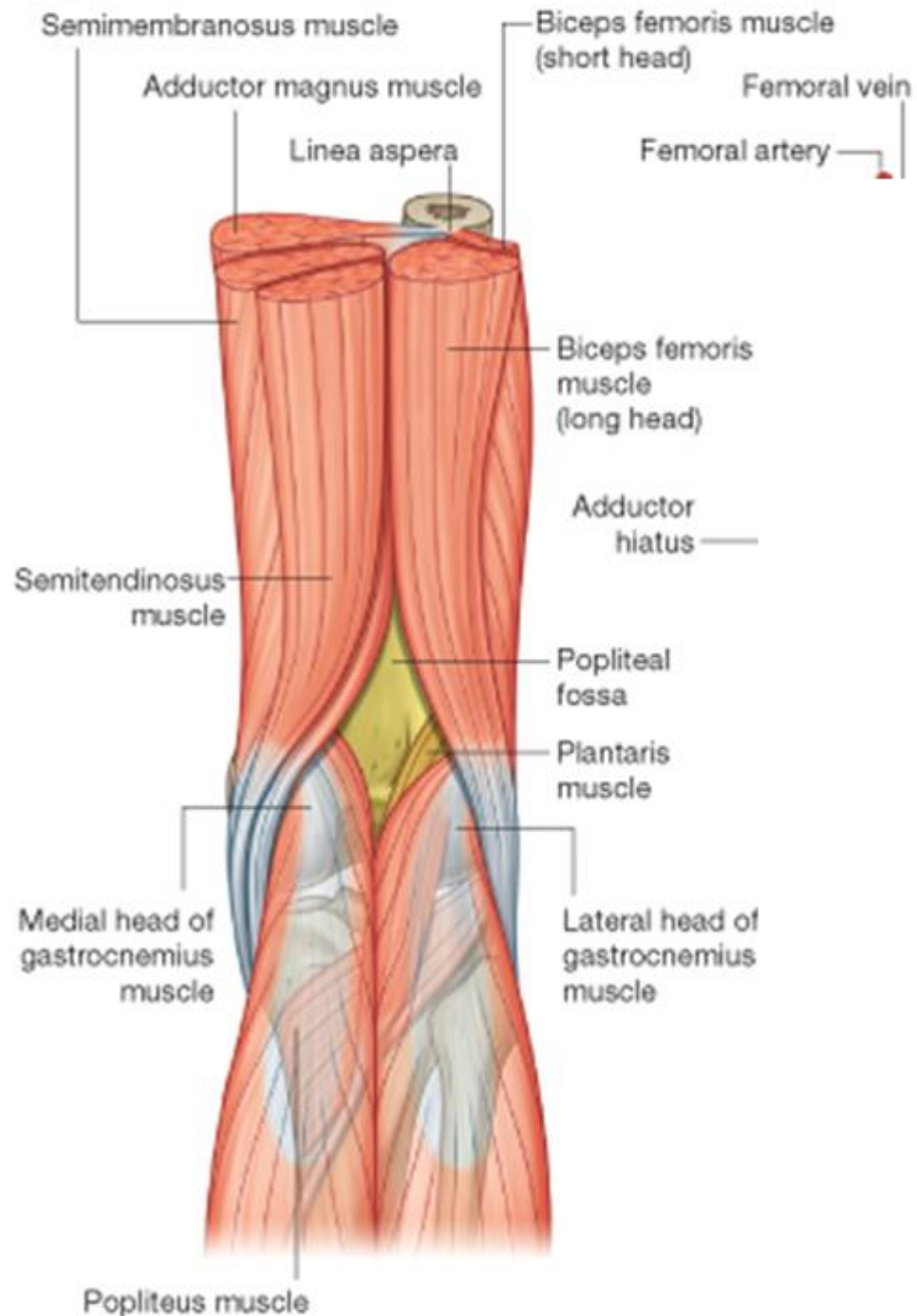
Laterally: (above)

The biceps femoris

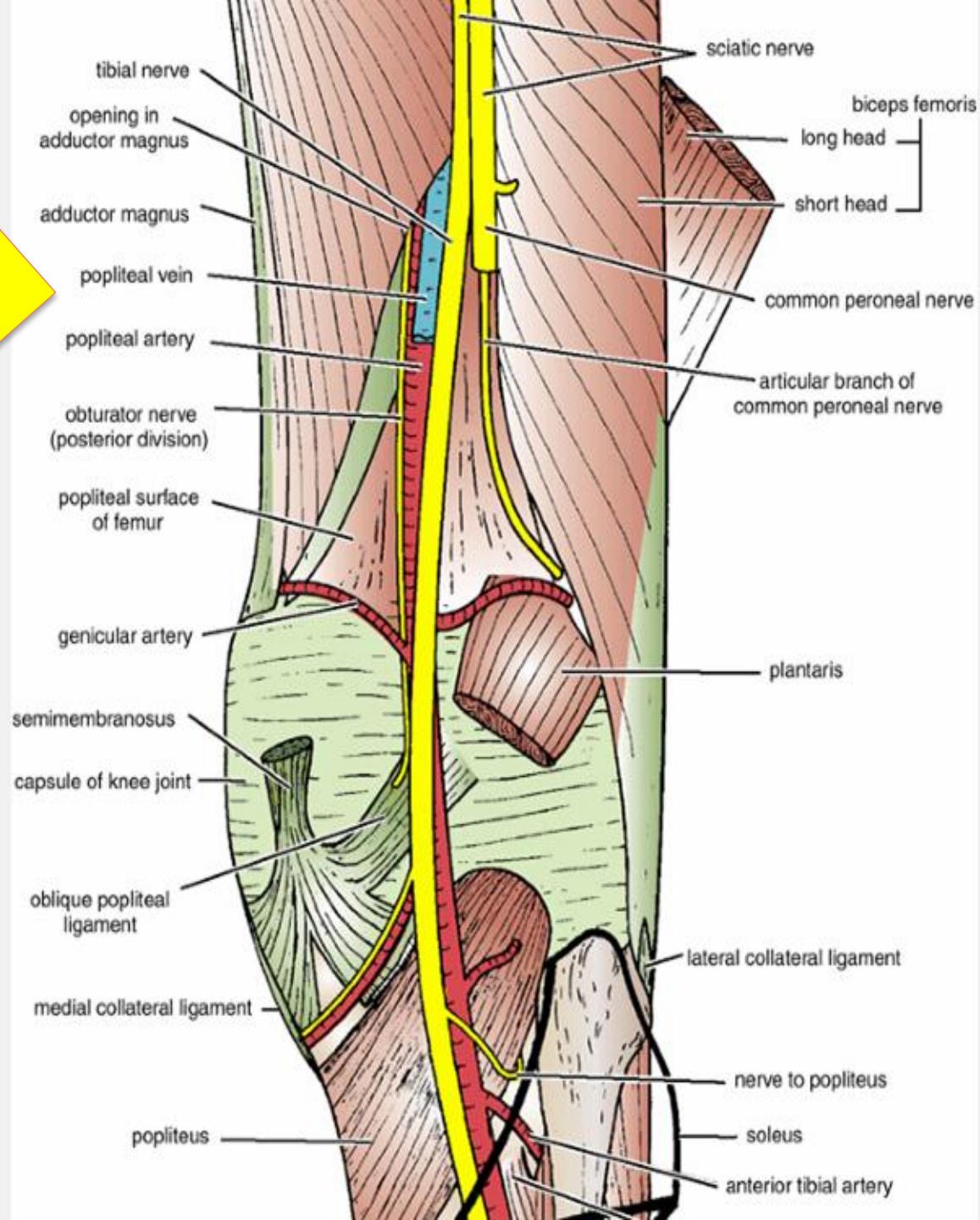
(below) *The lateral head of the gastrocnemius and Plantaris*

Medially:

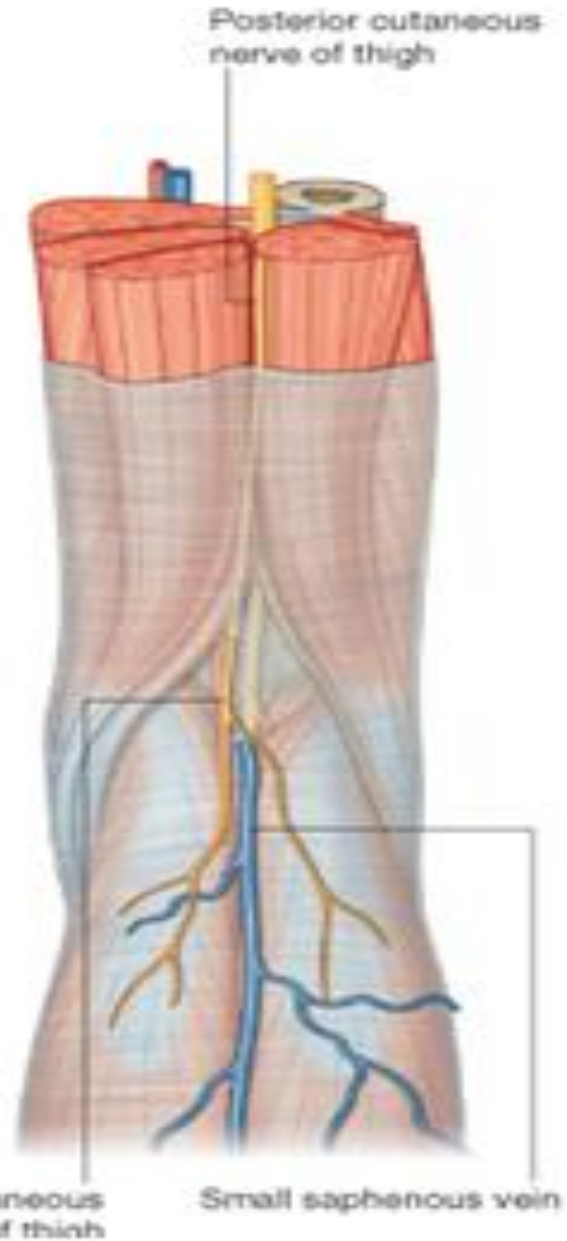
(above) *The semimembranosus and semitendinosus* (below) *The medial head of the gastrocnemius*

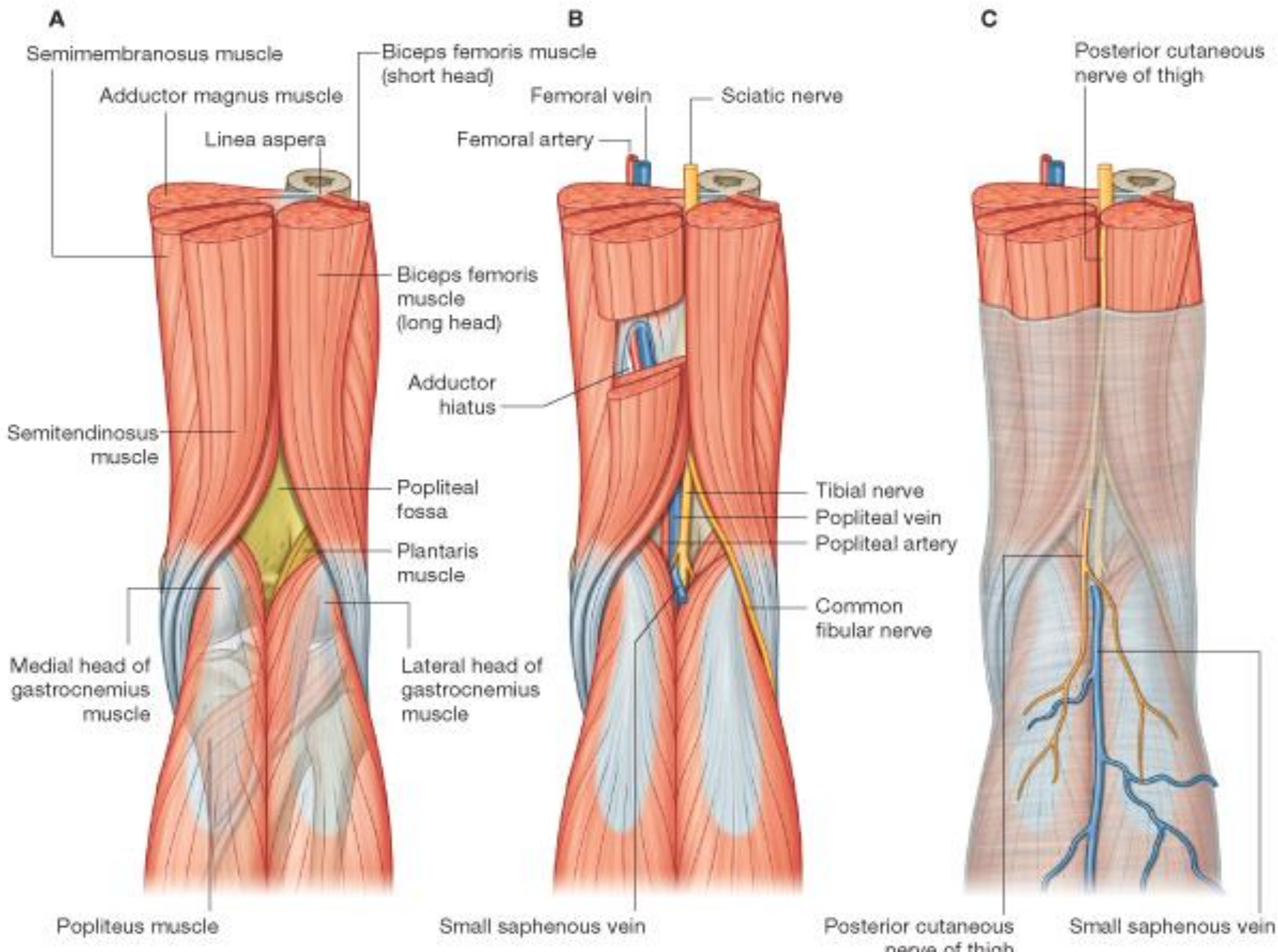


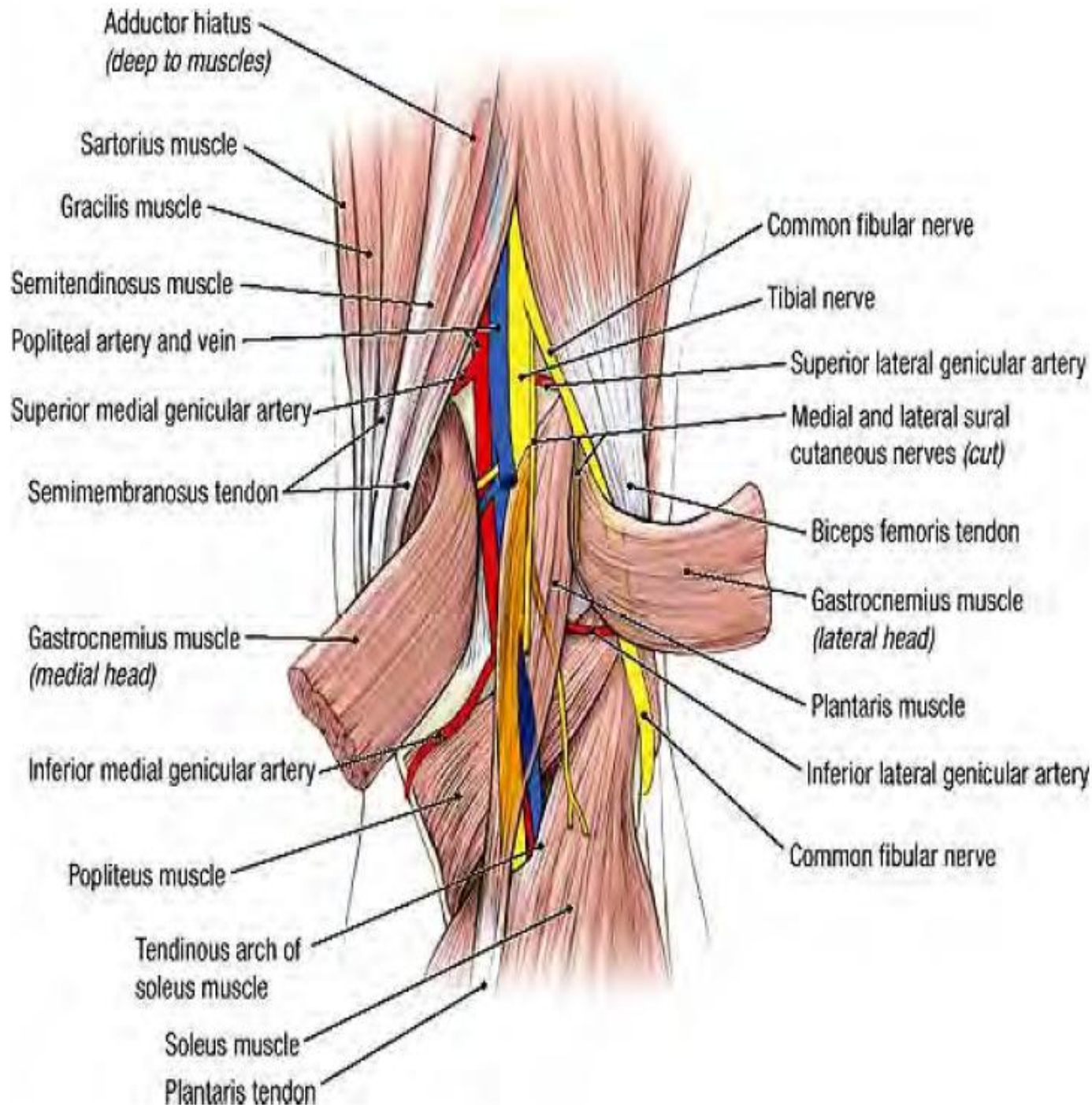
The Floor is formed by
The popliteal surface of the femur,
The posterior surface of the knee joint,
The popliteus muscle.



The Roof is formed by
Skin
Superficial fascia
The deep fascia of the thigh.





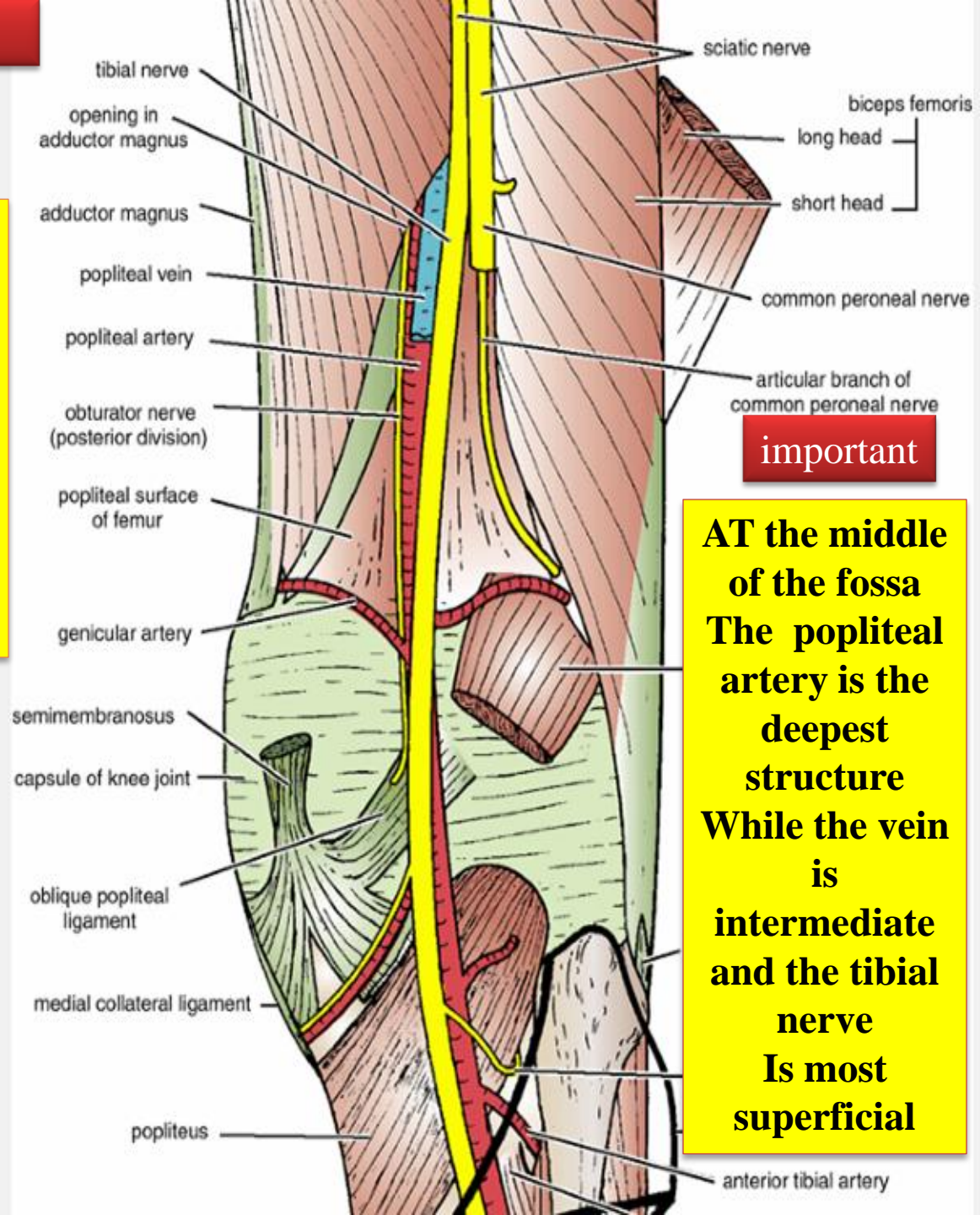


- Contents of the popliteal fossa***
- ***Popliteal artery and vein***
 - ***The common peroneal nerve (lateral popliteal nerve)***
 - ***Tibial nerve (medial popliteal nerve)***
 - ***The posterior cutaneous nerve of the thigh***
 - ***The small saphenous vein***
 - ***Connective tissue, and lymph nodes.***

The popliteal artery

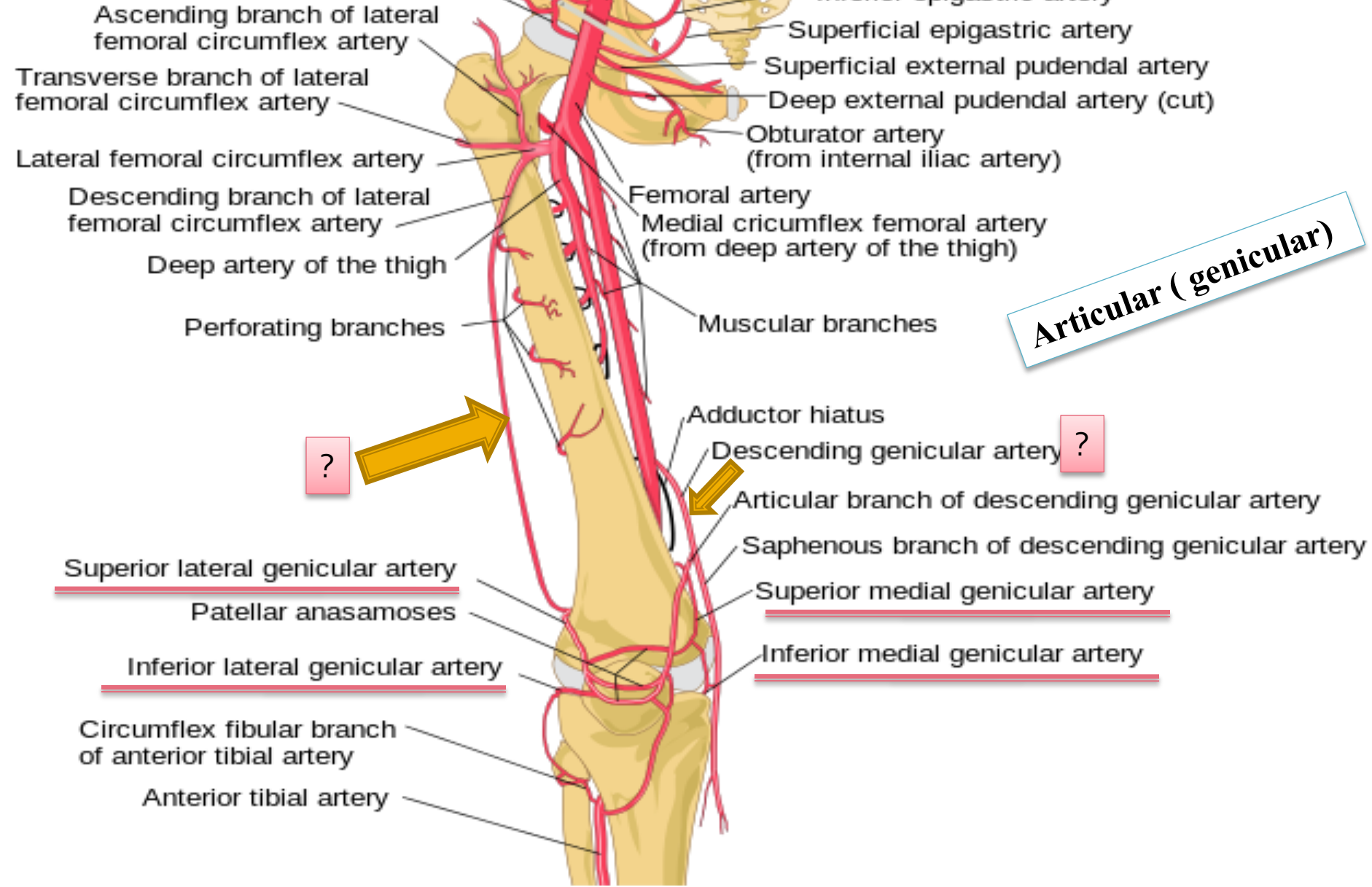
➤ Enters the popliteal fossa through the opening in the adductor magnus as a continuation of the femoral artery (the deepest structure in the fossa).
➤ It ends at the level of the lower border of the popliteus muscle by dividing into anterior and posterior tibial arteries

Branches
Muscular branches
Articular (genicular)
branches to the knee.



important

AT the middle of the fossa The popliteal artery is the deepest structure While the vein is intermediate and the tibial nerve Is most superficial



Articular (genicular)



Superior lateral genicular artery

Superior medial genicular artery

Inferior lateral genicular artery

Inferior medial genicular artery

Tibial Nerve

Ventral divisions of L4, 5, S1, 2, 3

- The **larger** terminal branch of the **sciatic nerve**
 - Arises in the lower third of the thigh.
 - It runs downward through the popliteal fossa
 - Enters the posterior compartment of the leg by passing beneath the soleus muscle.

Branches

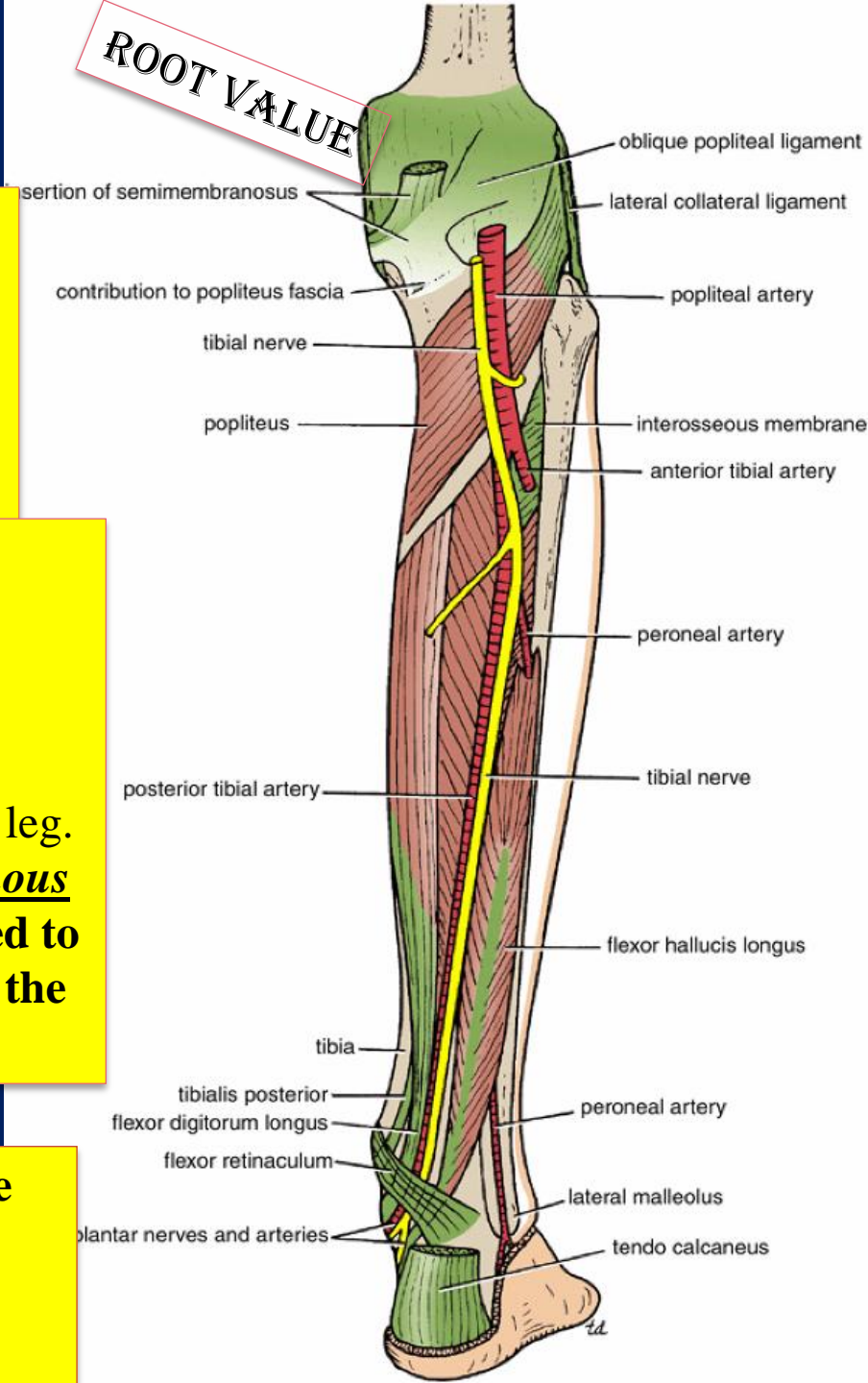
1-Cutaneous:

The sural nerve

- descends between the two heads of the **gastrocnemius muscle**
- Supplies the skin of the calf and the back of the leg.
- The sural nerve accompanies the small saphenous vein behind the lateral malleolus and is distributed to the skin along the lateral border of the foot and the lateral side of the little toe

2-Muscular: branches supply both heads of the gastrocnemius and the plantaris, soleus, and popliteus

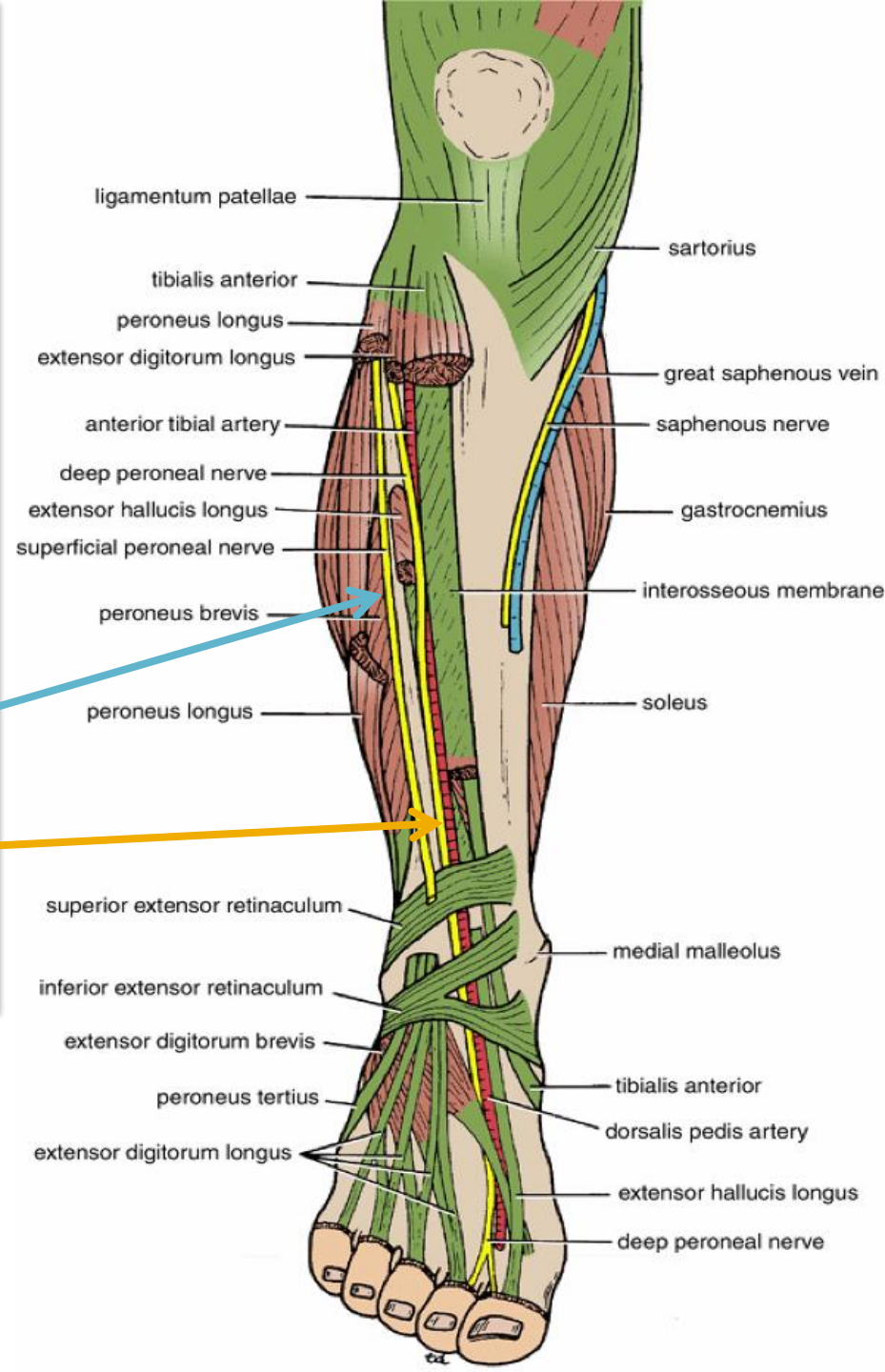
3-Articular: branches supply the knee joint.



Common Peroneal Nerve

L4, 5, S1, 2

- The smaller terminal branch of the sciatic nerve
- Arises in the lower third of the thigh.
- It runs downward through the popliteal fossa
- It leaves the fossa by crossing superficially the lateral head of the gastrocnemius muscle.
- *It then passes behind the head of the fibula, winds laterally around the neck of the bone (subcutaneous and exposed to injury), pierces the peroneus longus muscle.*
- **Divides into two terminal branches:**
 - The superficial peroneal nerve
 - The deep peroneal nerve



Branches

Cutaneous:

- **The sural communicating branch**
- The lateral cutaneous nerve of the calf supplies the skin on the lateral side of the back of the leg

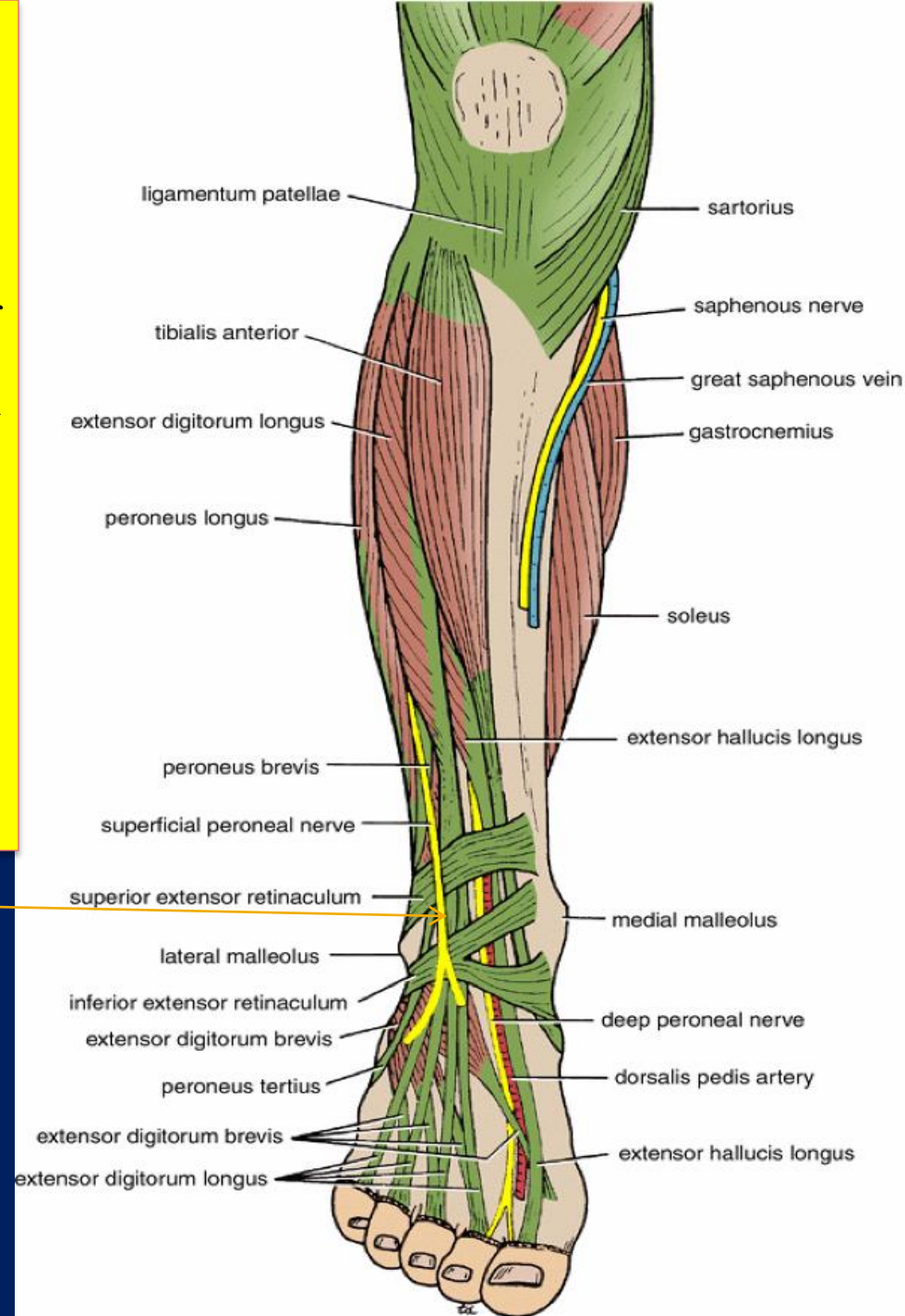
Muscular branch: to the short head of the biceps femoris muscle, which arises high up in the popliteal fossa

Articular: branches to the knee joint

Terminal branches

The superficial peroneal nerve
Also called the musclocutaneous
nerve of the leg,

Supplies two muscles and then becomes
cutaneous where
It supplies the skin over the leg



SMALL SAPHENOUS VEIN

