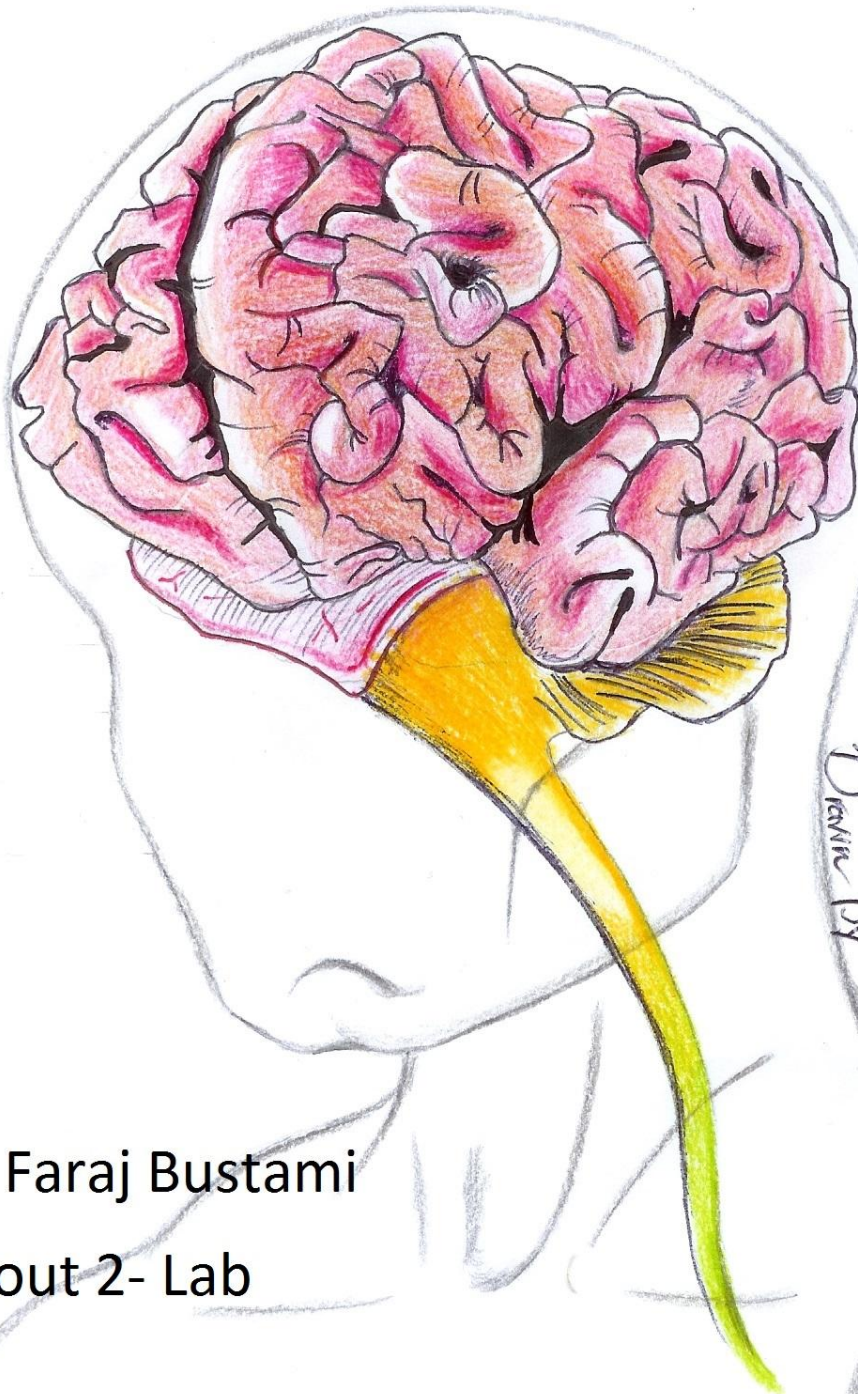


# CENTRAL NERVOUS SYSTEM

- Handout
- Sheet
- Slide
  
- Anatomy
- Physiology
- Pathology
- Biochemistry
- Microbiology
- Pharmacology
- PBL



Drawn By Tawiq Bushraaq...

Done By:

Dr. Name: Dr. Faraj Bustami

Lec #: Handout 2- Lab

Bustami

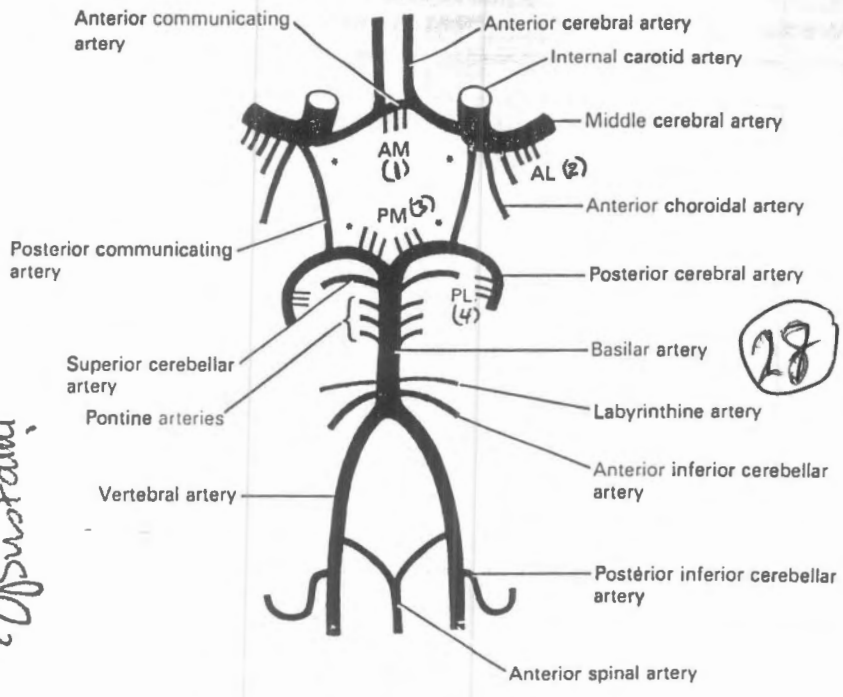


Fig. 14.1 Diagram of arteries at the base of the brain showing the circulus arteriosus\*. The groups of central branches are anteromedial (AM), anterolateral (AL), posteromedial (PM) and posterolateral (PL).

- The arteries supplying the brain are the internal carotid and the vertebral and their branches.

- Each internal carotid artery gives off two major branches to the brain: these are the anterior cerebral and middle cerebral arteries. The two vertebral arteries ascend on the anterolat. aspect of the medulla. At the lower border of the pons they unite to form the basilar artery. At the upper border of the pons the basilar artery bifurcates into two post. cerebral arteries.

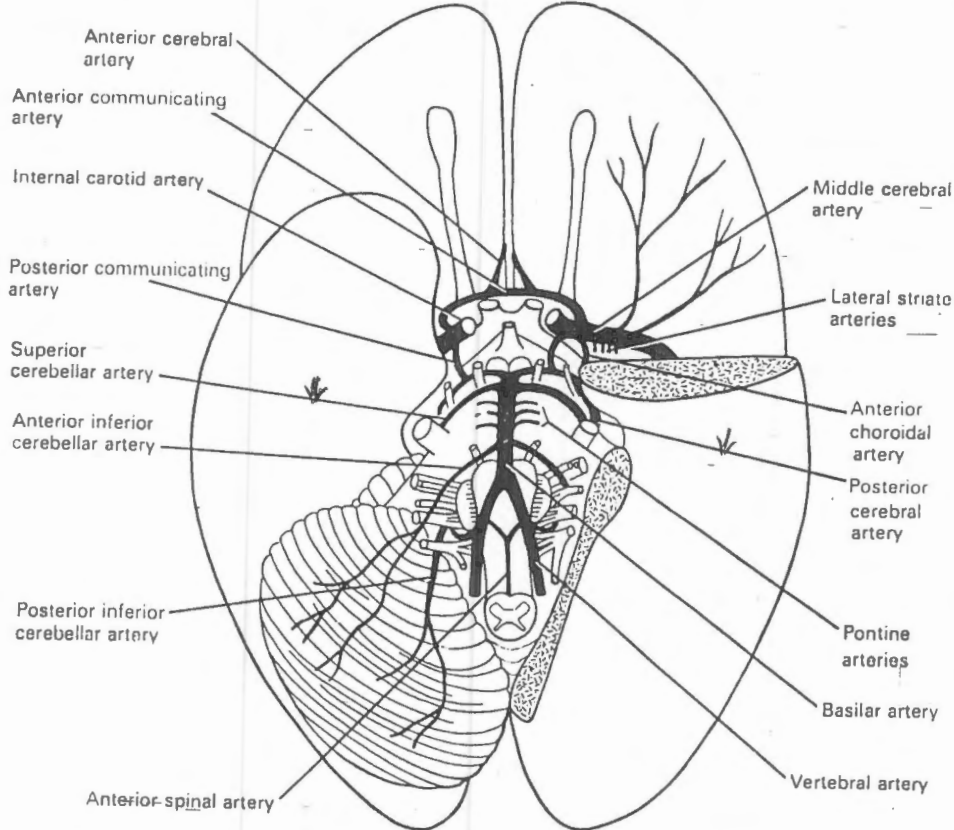


Fig. 14.2 Arteries at the base of the brain. The right cerebellar hemisphere and cerebral temporal lobe have been removed.

The internal carotid and vertebro-basilar systems are connected by the posterior communicating arteries. The two anterior cerebral arteries are connected by the anterior communicating artery. As a result of these anastomosis an arterial ring → the circulus arteriosus (or circle of Willis) is found in relation to the base of the brain - at the subarachnoid space.

In addition to the larger arteries mentioned above, two small branches of the internal carotid system must be noted. one of these is the anterior choroidal artery which arises directly from the internal

→ carotid, → runs backward in relation to the optic tract → enters the inferior horn of the lateral ventricle through the choroid fissure. The other is the recurrent branch of the ant. cerebral a. (artery of Heubner). This artery runs backward and laterally to enter the ant. perforated substance.

Bustami

29 (M) (16) (15)

The anterior, middle, and posterior cerebral arteries give rise to two sets of branches → Cortical & Central

→ The Cortical branches :- ramify on the surface of the cerebral hemisphere and supply the cerebral cortex

→ The Central (or Perforating) branches :- pass deep into the substance of the cerebral hemispheres to supply structures within it

Consist of 4 main groups ← anteromedial, anterolateral, posteromedial, posterolateral

① The anteromedial group; arise from anterior cerebral and anterior communicating arteries and enter the most medial part of the anterior perforated substance.

② The arteries of the anterolateral group are also called Striate arteries. They arise mainly from the middle cerebral artery, some arise from ant. cerebral. They enter the anterior perforated substance and divide into 2 sets, medial and lateral → The medial striate arteries ascend through the lentiform nucleus to reach the corpus striatum and internal capsule. The lateral striate branches ascend lateral to lentiform nucleus. They then turn medially and pass through the substance of the lentiform nucleus to reach the internal capsule → One of these lateral striate arteries is usually LARGER than the others; it is called Charcot's artery or artery of cerebral haemorrhage.

③ The posteromedial group of central arteries → arise from the posterior cerebral and posterior communicating arteries. They enter the interpeduncular region (i.e. between the 2 crus cerebri)

④ The branches of the posterolateral group: arise from the posterior cerebral artery as it winds round the cerebral peduncle

of Surotami

\* Arteries supplying the cerebellum

- Sup. surface → Sup. cerebellar branches of basilar a.
- Ant. part of inf. surface → Ant. inf. cerebellar " " "
- Post. part of inf. surface → Post. inf. " " = Vertebrala.

\* Arterial Supply of cerebral cortex → By cortical branches of

- Ant. cerebral arteries
- Middle cerebral arteries
- Post. cerebral arteries

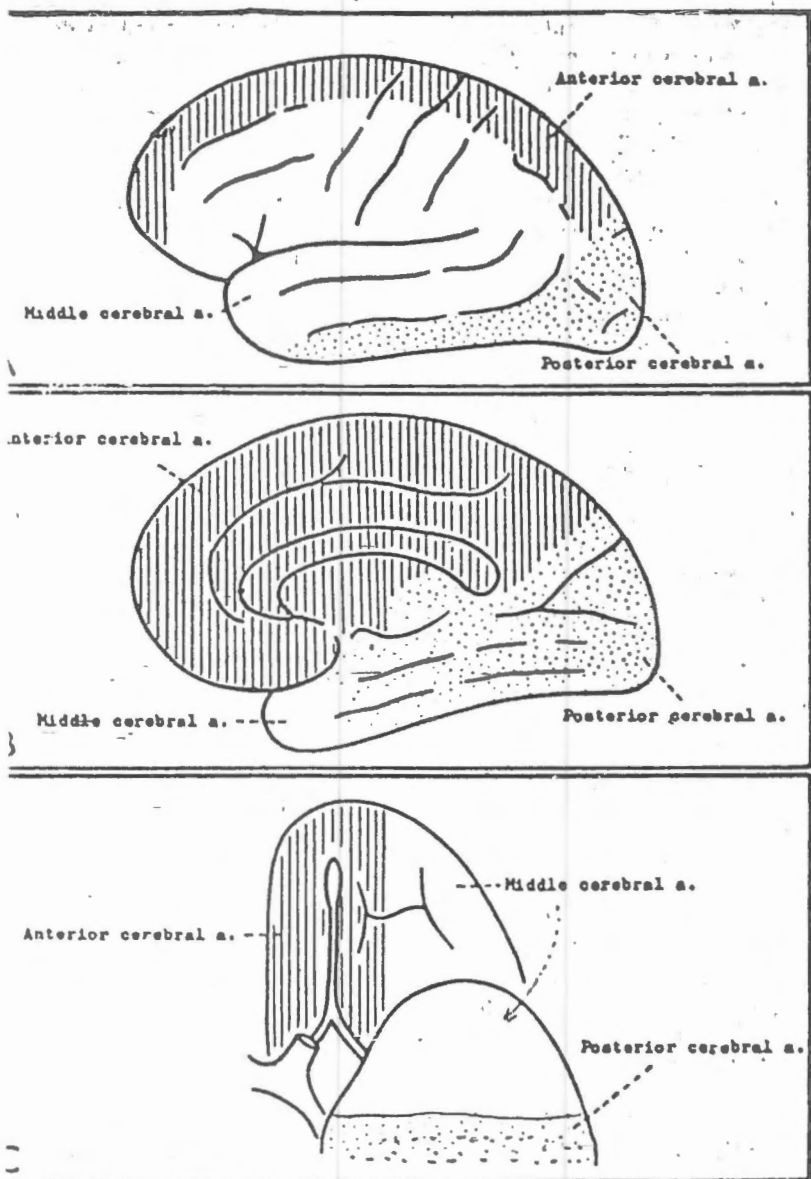


FIG. 18.4. Distribution of the anterior, posterior and middle cerebral arteries on the superolateral (A), medial (B), and orbital (C) aspects of the cerebral hemisphere. Note that in 'B' the upper part represents the medial surface, and the lower part represents the tentorial surface.

→ The greater part of the superolateral surface is supplied by the middle cerebral artery

Except for ① a strip 1/2-1 inch wide along the superomedial border extending from the frontal pole to the parieto-occipital sulcus → supplied by ant. cerebral a. ② occipital pole ③ inf. temporal gyrus → by post. cerebral a.

→ The main artery supplying the medial surface is → Ant. cerebral a. Except → area belonging to occipital lobe → by post. cerebral a.

→ The lateral part of the orbital surface → middle cerebral a. → the medial part → ant. cerebral a.

→ The tentorial surface is supplied by post. cerebral a. → the temporal pole is however, supplied by middle cerebral a.

From the above description it will be clear that:

- ① the main somatic motor & sensory areas are supplied by the middle cerebral a. Except → in the upper most part (leg areas) → by ant. cerebral a. → middle cerebral a.
- ② the auditory area is supplied by → middle cerebral a.
- ③ the visual area " " " → post. cerebral a.

N.B The part of the visual area responsible for macular vision (post. part) may receive a blood supply from middle cerebral a. either directly or through anastomoses with branches of post. cerebral a. → one explanation for sparing the macular vision in cases of thrombosis of post. cerebral a.

Dr. Swaraj

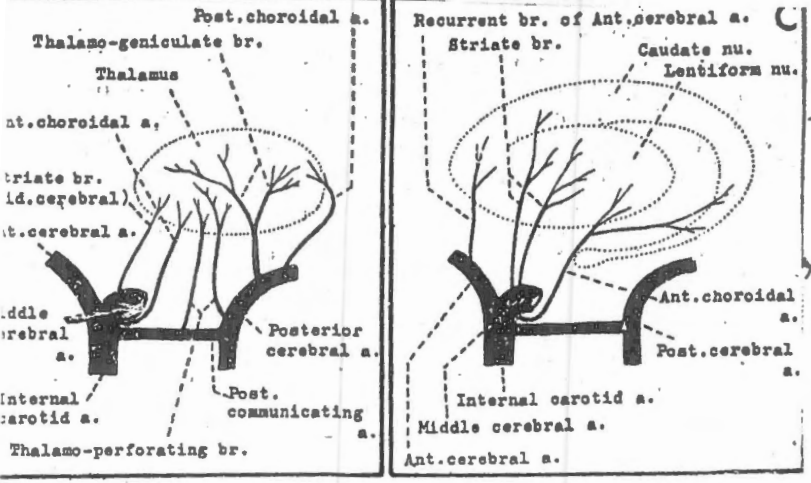


FIG. 18.5. Schemes to show the arterial supply of the thalamus (B), and the corpus striatum (C).

Arteries supplying the thalamus

- \* The thalamus is supplied mainly by perforating branches of the post. cerebral artery.
- \* The posteromedial group of branches (also called thalamoperforating arteries) supply the medial and anterior part.
- \* The posterolateral group (also called thalamogeniculate branches) supply the posterior and lateral parts of the thalamus.
- \* other sources → ant. + post. choroidal a.

Arteries supplying the hypothalamus

- Ant. part → by central branches of the anteromedial group (from ant. cerebral)
- post. part → by central-branches of the posteromedial group (from post. cerebral and post. communicating arteries)


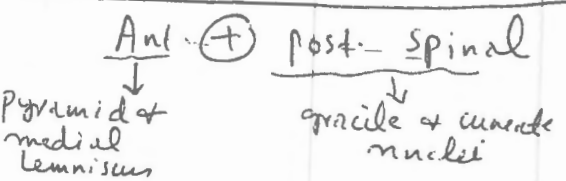
Arteries supplying the corpus striatum

- The main arterial supply of striate branches of the middle cerebral a. is derived from lateral caudate & putamen. In addition their anterior-most parts (including head of caudate nucleus) receive their blood supply from → Recurrent branch of ant. cerebral a. and their posterior parts (including tail of caudate nuc.) through the → ant. choroidal a.

- The main blood supply of the globus pallidus is from the anterior choroidal a.

Arterial supply of the Medulla

→ by various branches of the vertebral arteries




Arterial supply of pons

→ by branches of the basilar a. { Paramedian circumferential

Arterial supply of midbrain

→ mainly by branches of basilar artery



Substantia nigra

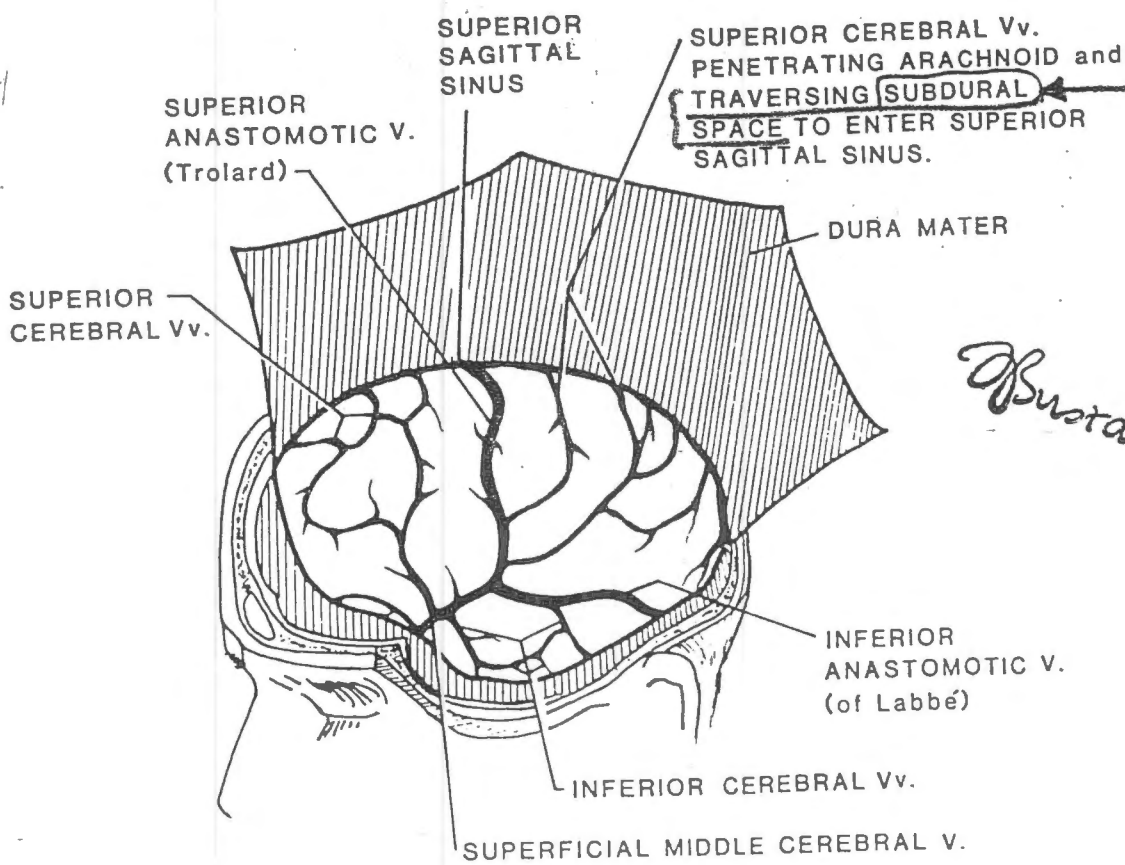


Figure 14A. Lateral View of the Superficial Cerebral Veins on the Surface of the Left Cerebral Hemisphere

Table 7. Extradural and subdural haemorrhage

(A) Extradural haemorrhage	(B) Subdural haemorrhage
1. Less common	1. More common.
2. Haemorrhage is arterial (middle meningeal).	2. Haemorrhage is venous. (superior cerebral v.)
3. Symptoms of cerebral compression are late.	3. Symptoms of cerebral compression are quick.
4. Lucid interval present. It is a temporary phase of consciousness between the earlier unconsciousness of cerebral concussion and the later unconsciousness of cerebral compression.	4. No lucid interval.
5. Paralysis first appears in the face and then spreads to the lower parts of the body.	5. The march of paralysis is haphazard.
6. There is no blood in CSF.	6. Blood in the CSF usually indicates subdural haemorrhage in cases with <u>trauma</u> (accidents).

(C) Subarachnoid haemorrhage

Commonly due to rupture of a congenital aneurysm in one of the cerebral arteries (so called berry aneurysm)

- blood in CSF
- Compression and signs of paralysis of one or more cranial nerves are not uncommon before rupture

توضيح

محاضرة د. فرج البساطي

25/2/2014

طلبة الطب البشري

### THE SPINAL CORD

CNS I

(الجزء المركزي)

51

كامله المجموع الثاني

- The spinal cord is a compressed cylindrical column (about 45 cm).
- It is 25 cm. shorter than the vertebral column.
- Above, it is continuous with the *medulla* at the level of the *foramen magnum*. Below, it tapers forming the *conus medullaris* and ends at the level of the intervertebral disc between the first and second lumbar vertebrae.
- A fine thread of neuroglia surrounded by pia mater called the *filum terminale*, descends from the *conus medullaris* to be attached to the back of the coccyx.
- The spinal cord is attached to the dura mater by lateral septa called the *denticulate ligaments* (which are folds of pia mater found between the ant. and the post. roots).
- The spinal cord is supported in the vertebral canal by 3 mechanisms :
  - a) the *filum terminale* : which is attached to the back of the coccyx.
  - b) the *denticulate ligaments* : which are attached to the dura mater.
  - c) the *dura mater* : which is attached above to the margins of the foramen magnum and on either side to the margins of the intervertebral foramina.

٢٥

The *dura mater* ends at the lower border of the second sacral vertebra. S<sub>2</sub>

### THE SPINAL NERVES

- 31 pairs of spinal nerves (8 cervical, 12 thoracic, 5 lumbar, 5 sacral and 1 coccygeal) are attached to the spinal cord.
- Each spinal nerve is attached to the spinal cord by means of 2 roots (a dorsal "sensory" root and a ventral "motor" root).
- Each root is attached by a series of filaments along the length of a segment of the spinal cord.

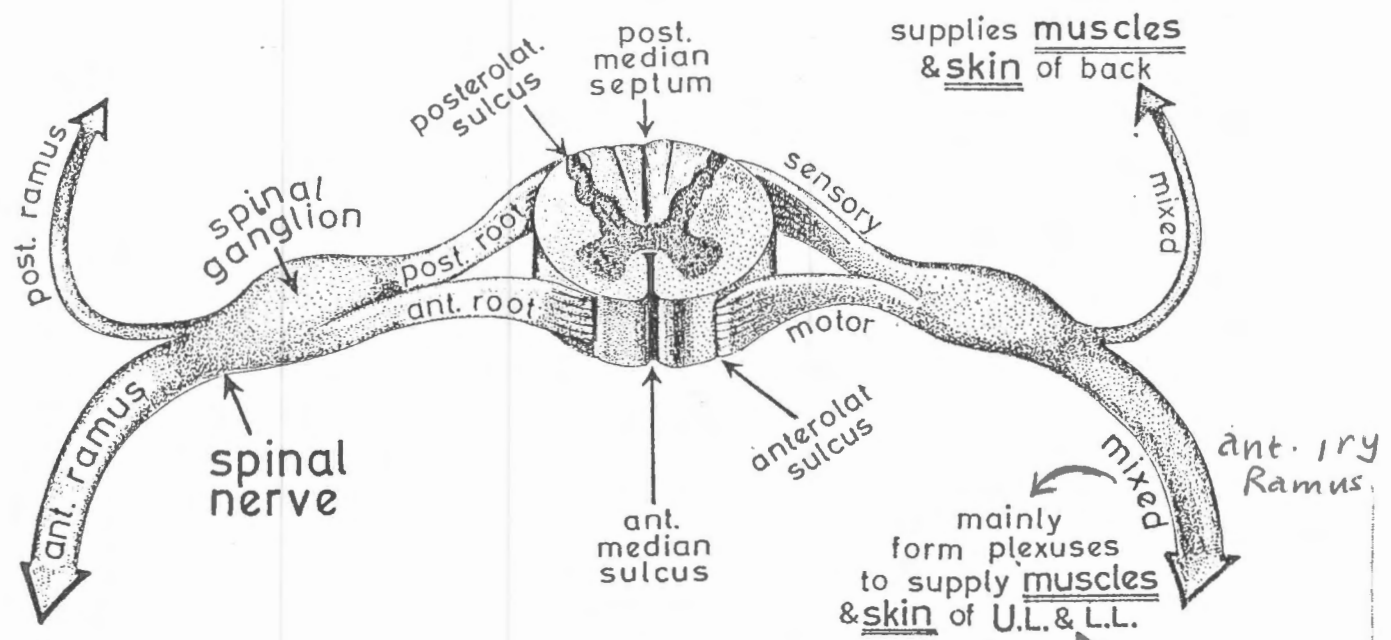


Fig. 66

A segment of the spinal cord with its sensory and motor roots.

Basirani

52

- When the foetus, is 3 months old the length of his spinal cord is equal to the length of his vertebral column, and the spinal cord fills the whole length of the vertebral canal.
- After 3 months, the vertebral column grows faster than the spinal cord.
- At birth, the spinal cord ends at the level of the 3rd lumbar vertebra.
- The adult spinal cord ends at the level of the intervertebral disc between L1 and L2.

Notice the following :

- 1 — The segments of the spinal cord are not in line with the vertebrae which correspond to them in number and the difference increases as we go downwards :
  - the spinous process of C6 is opposite the spinal cord segment C7
  - the spinous process of T3 is opposite the spinal cord segment T5
  - the spinous process of T9 is opposite the spinal cord segment T11.

Spinous process (vertebra)	Spinal cord segment
C6	C7
T3	T5
T8	T10
T10 - T12 L1 - L2	L1 - L5 S1 - end

- 2 — The spinal nerves leave the vertebral canal at the intervertebral foramina which are lower down than the level of origin of the spinal nerves; therefore, the ant. and post. roots have to descend in the subarachnoid space some distances; "the lower the segment of the spinal cord the longer the distance which the roots have to descend before they reach their intervertebral foramina."
- 3 — The lumbar and sacral nerves have very long post. and ant. roots. Their roots form a bundle called "the cauda equina" (because it resembles the tail of a horse).
- 4 — The subarachnoid space below L2 (after the spinal cord ends) contains only the cauda equina and filum terminale suspended in C.S.F. If we puncture the subarachnoid space below L2 (lumbar puncture) there is no danger of injury to the spinal cord.



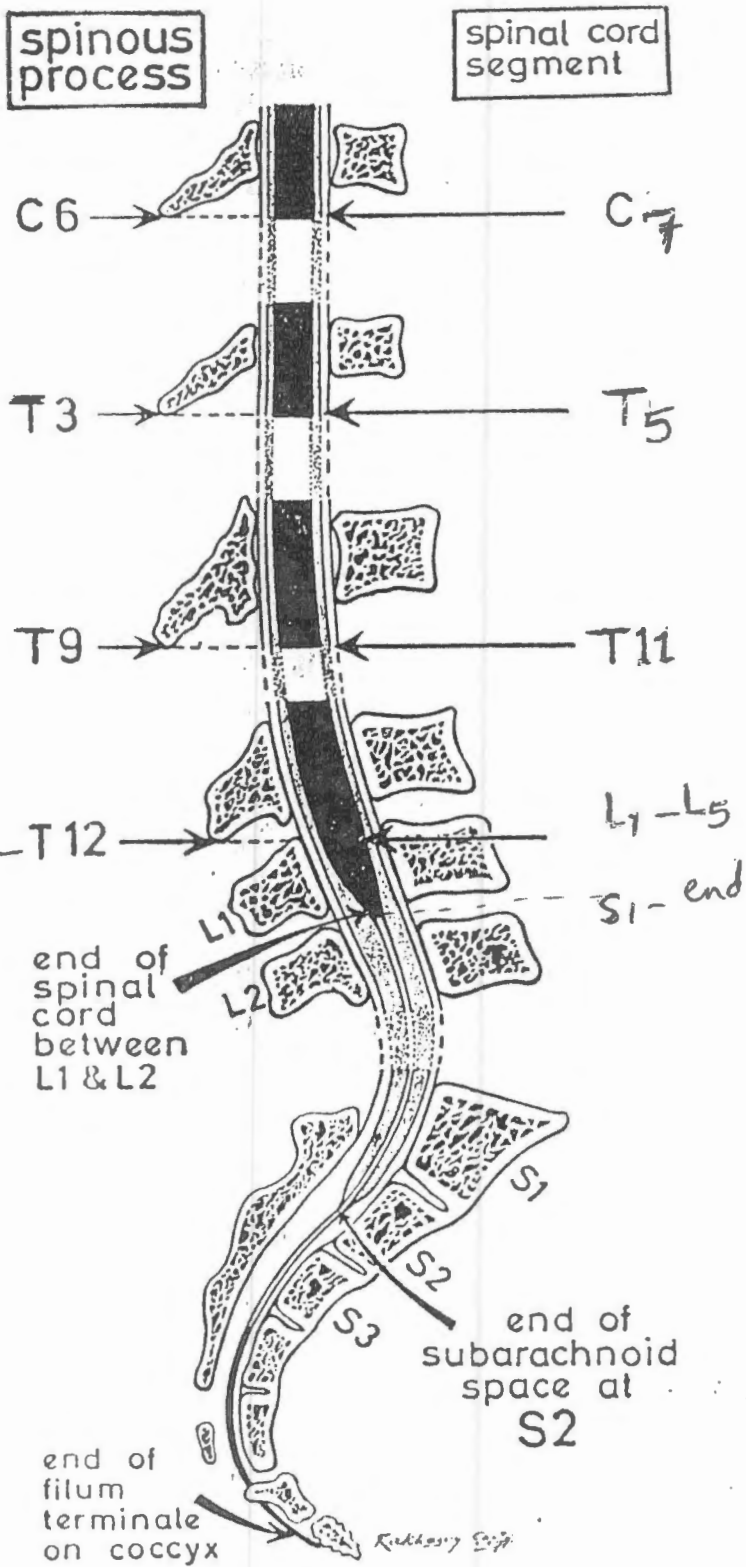


Fig. 83

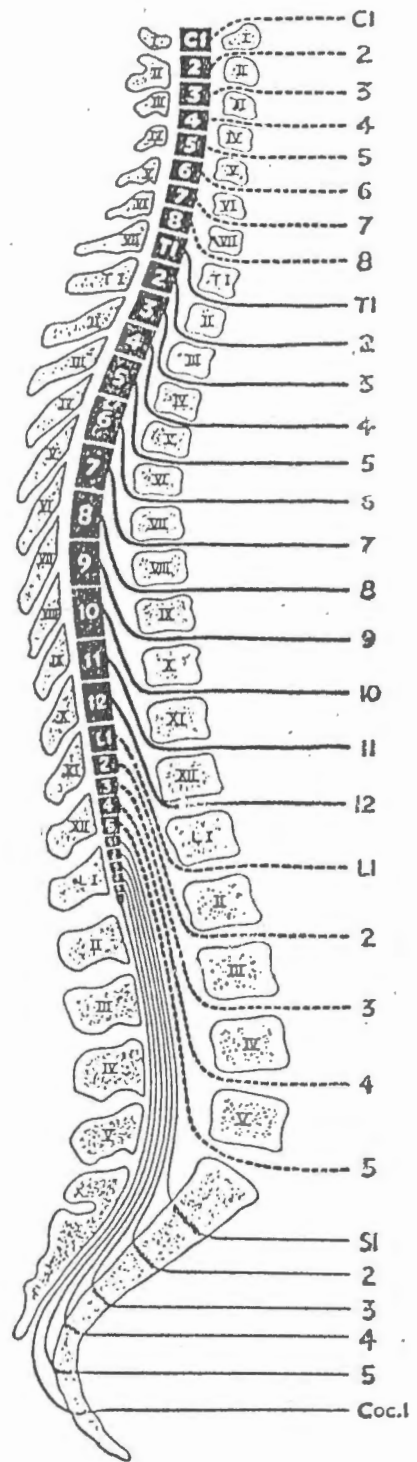
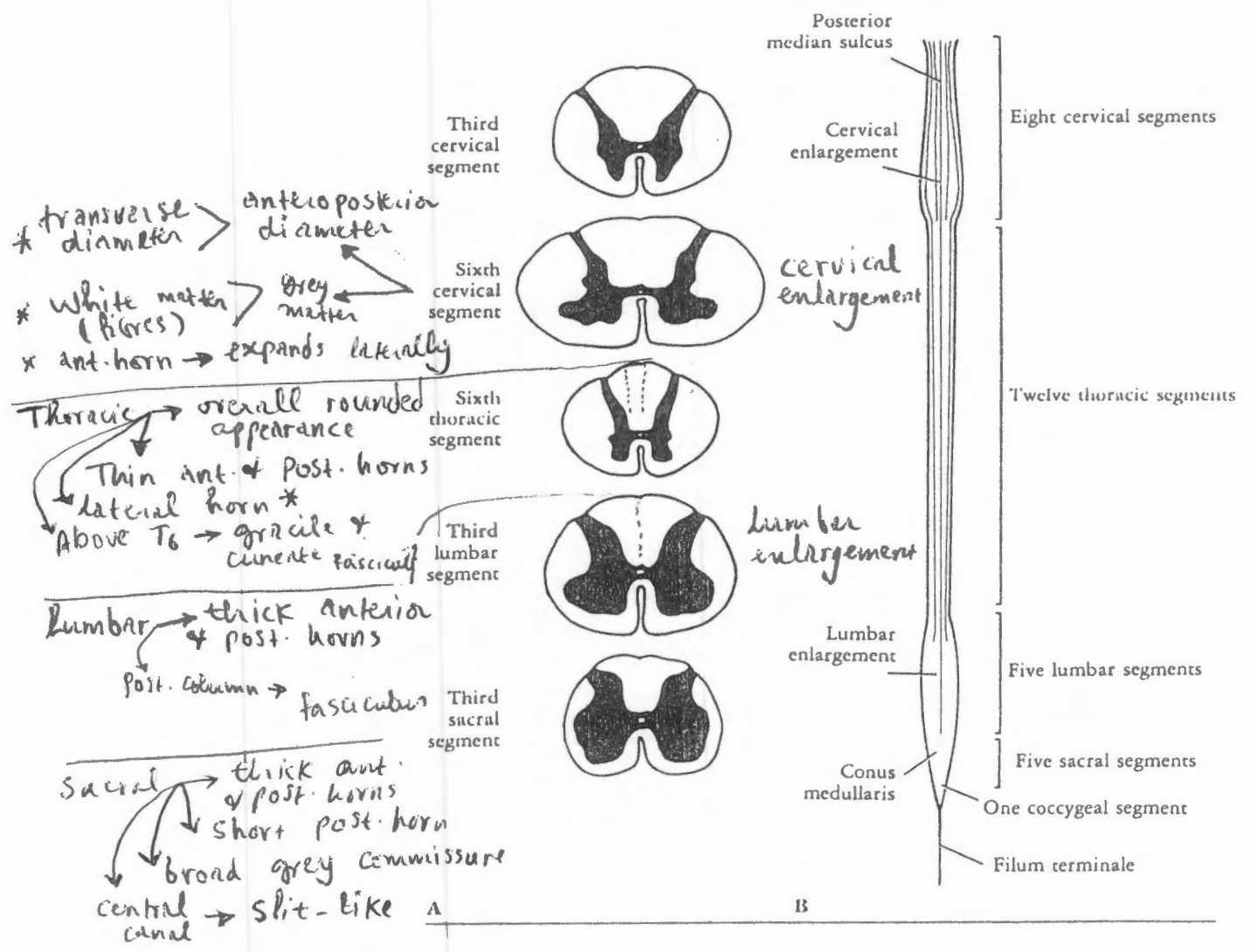


Fig. 84

Two diagrams to illustrate the relation between the spinal cord and the vertebral column



8(53)B

Bustami 1999

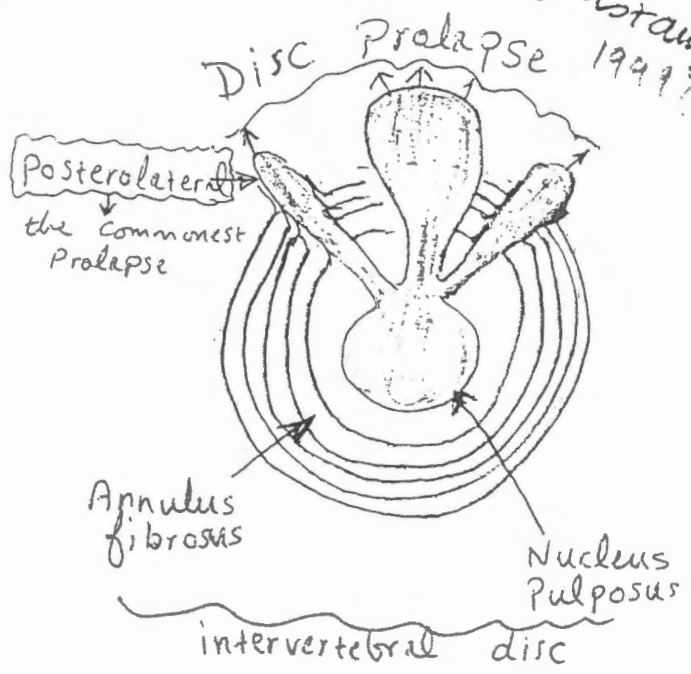
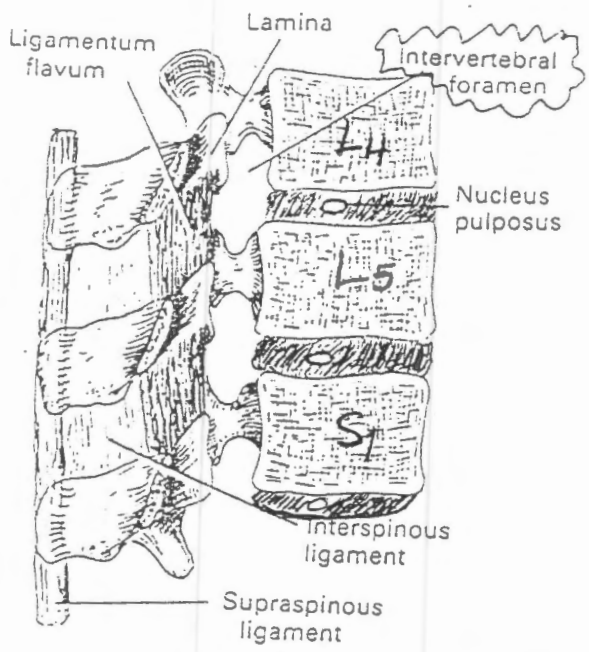


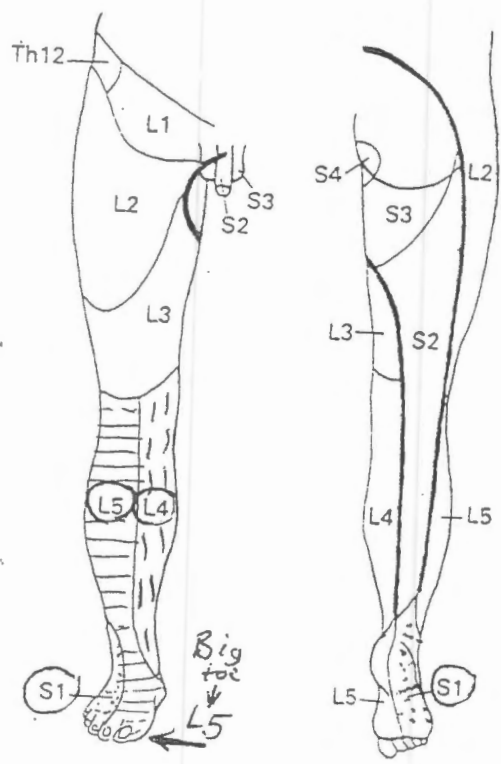
Fig. 6.68 Bisected vertebral column. The left half is seen from the right, so showing the inside of the vertebral canal, intervertebral discs in section, and the boundaries of two intervertebral foramina.

**Most Common Lumbar Disc Syndromes**

Root	Disc Interspace	Reflex Affected	Motor Weakness	Sensory Changes (if any)
L4	L3-L4	Knee jerk	Knee extension	Anteromedial leg
L5	L4-L5	Hamstring jerk	Large toe dorsiflexion	Large toe Anterolateral leg
S1	L5-S1	Ankle jerk	Foot, plantar flexion	Foot, lateral border

Dermatomes of lower limb

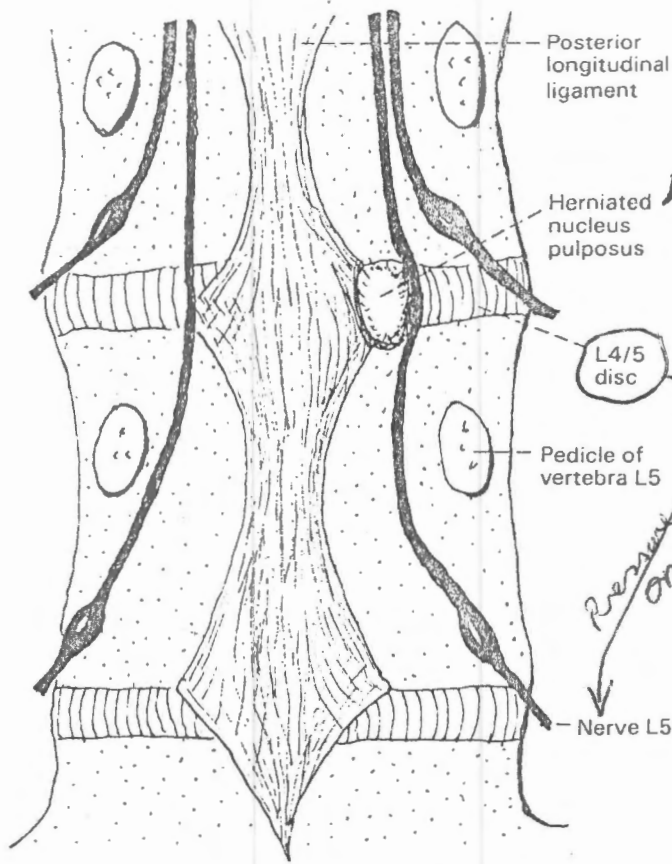
Myotomes of lower limb



quadriceps → Knee extension  
 L2, L3, L4 → Iliopsoas → thigh on hip flexion  
 adductor group → thigh adduction

L5 → Tibialis anterior } Ankle & big toe DORSIFLEXION  
 Extensor hallucis longus  
 hamstring  
 [check: have patient walk on heels]

S1 → gastrocnemius → Ankle plantar-flexion  
 [check: have patient walk on tiptoes]



0780080000 (56/A)

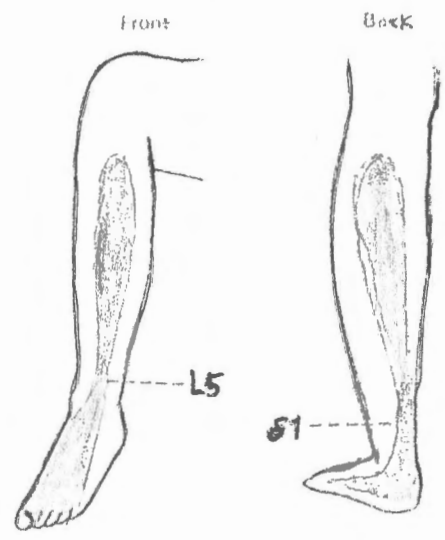


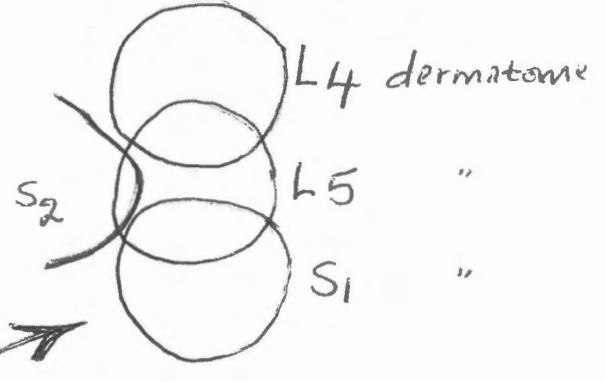
Fig. 8-17 Prolapse of L4/5 disc usually presses on L5 nerve roots. (Only posterior roots are shown.)

**Lumbar roots**  
Fully 95% of all cases of prolapsed intervertebral disc occur just above or below the fifth lumbar vertebra. The nucleus pulposus herniates posterolaterally as a rule and compresses the pair of roots traveling to the next foramen of exit (Fig. 8-17).

- Lumbar disc Prolapse is characterized by  $\left\{ \begin{array}{l} \text{backache} \\ \text{Sciatic pain (Sciatica)} \end{array} \right.$   
- Backache is caused by  $\left\{ \begin{array}{l} \text{tearing of annulus fibrosus} \\ \text{pressure on dura mater} \end{array} \right.$

**Innervation of dura mater and vertebral ligaments**

Each spinal nerve gives off a recurrent branch within the intervertebral foramen. The recurrent branch supplies the dura mater, the posterior longitudinal ligament of the vertebral column, and the outermost 8-10 lamellae of the annulus fibrosus of the intervertebral disc. The dura mater is exquisitely sensitive to stretching, and clinical evidence indicates extensive overlap of innervation. Stretching of the dural sheath of a single spinal nerve gives rise to pain over five or more dermatomes on the back (see later).



- Sciatica  $\rightarrow$  caused by pressure on posterior root fibres  
 $\rightarrow$  it is felt in the buttock, back of thigh & leg  
 $\rightarrow$  it is increased by pressure within the lumbar cistern (subarachnoid space) e.g. by coughing or sneezing  
 $\rightarrow$  also increased by stretching the affected root  $\rightarrow$  straight leg raising test

- An **L4/5** disc prolapse → produces pain over the **L5 dermatome**, there may be weakness of Dorsiflexion of the ankle or great toe

- With an **L5/S1** prolapse (the commonest) → pain is felt at the back of the leg & sometimes in the sole of foot → plantarflexion & eversion are weak and the ankle jerk (S1 segment) is reduced or absent

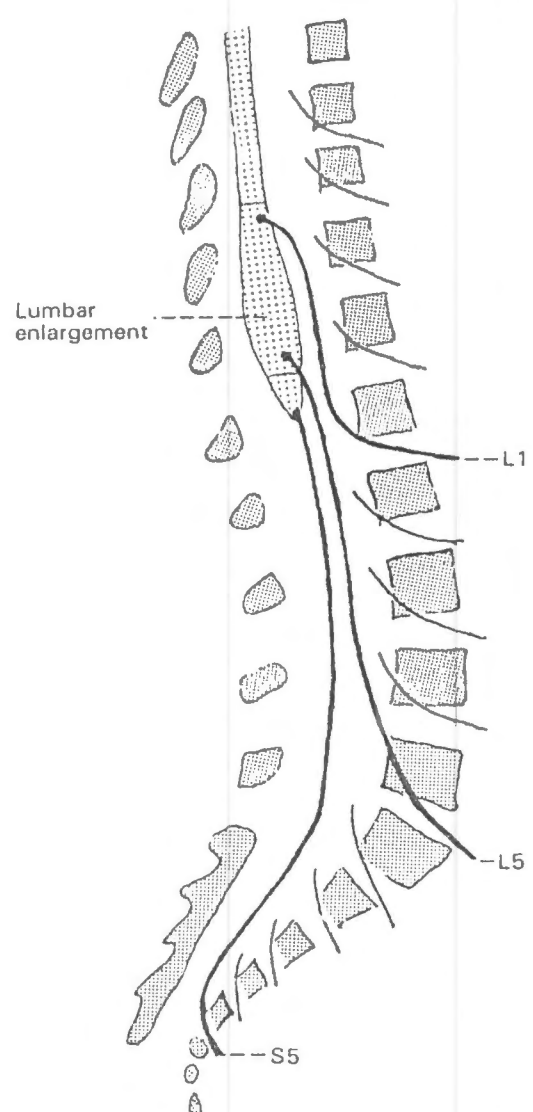
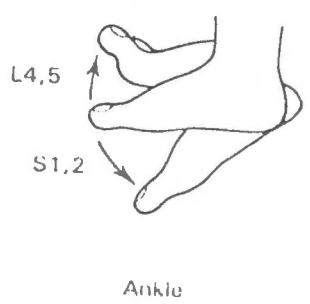


Fig. 8-8 Lumbar and sacral nerve roots. Only three are shown in continuity.

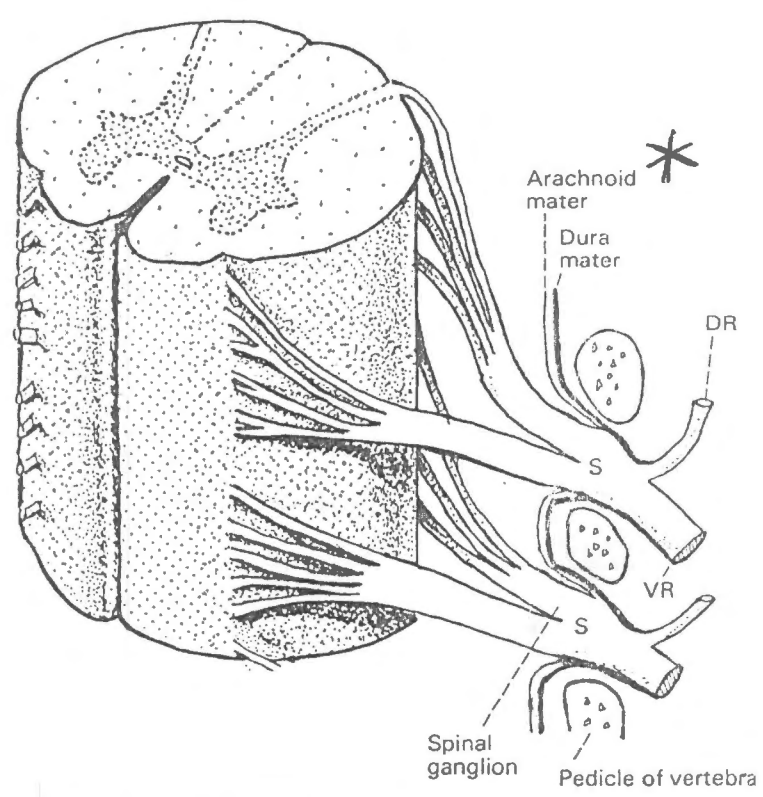


Fig. 8-9 Two thoracic spinal cord segments and spinal nerves. DR, dorsal ramus; S, spinal nerve; VR, ventral ramus.

**Thoracic roots**

These are rarely affected, because only rotary movements are permitted between the thoracic vertebrae. However, nerve roots may be compressed by vertebral collapse from trauma or metastatic cancer.

The T1 syndrome is a rare condition in which the first thoracic anterior root is torn from the spinal cord by violent traction, for instance when someone is pulled along the ground by one hand. The two presenting features are (a) wasting of the intrinsic muscles of the hand, and (b) Horner's syndrome (pupillary constriction, drooping of the upper eyelid (Chapter 31).

The root length increases progressively from rostral (superior) to caudal (inferior) levels

- Remember T1 (trunk) may be involved in CA apex of lung