

血 Hematology 血



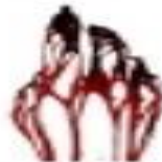- Histology
- Biochemistry
- Pathology
- Pharmacology
- Physiology
- Microbiology

● Handout

● Slide

● Sheet

- Dr. name :
Dr Tariq Aladily
- Lecture number :
PBL-2
- Done BY :



Clinical approach in Hematology

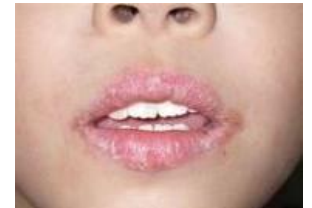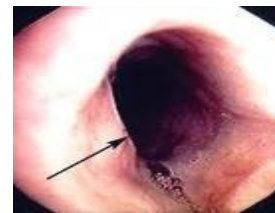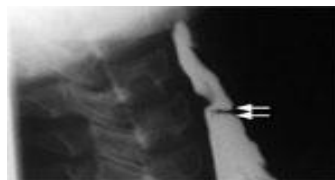
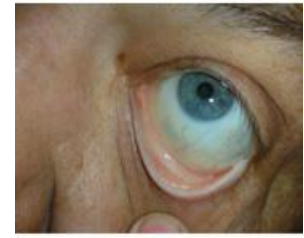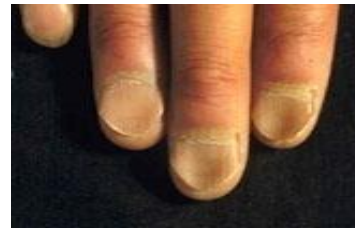Case one

24 yr old female complains of
Dizziness, Fatigue, Shortness of breath especially on
exertion and Headaches for the last 2 months. She
has been losing scalp hair.

She does not eat red meat and has reported heavy
menstrual bleeding.

Her physical exam showed
Lab and Xray test showed

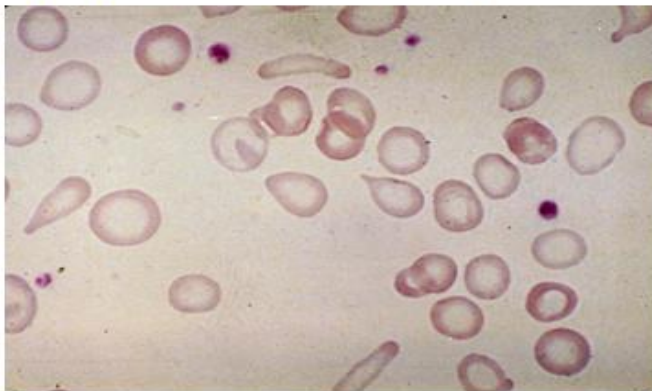
Likely Diagnosis



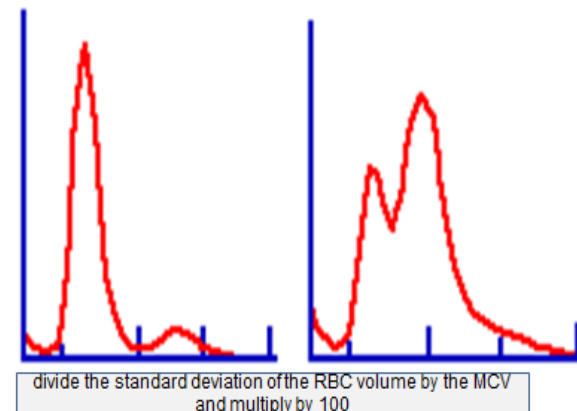
Investigations

- Hb 8 g/dl, MCV 65 fl, RDW 20%, MCH 19 pg, Retcs 0.8%
- Blood film
- RDW
- serum Ferritin 2 ng/ml, TIBC 450 $\mu\text{g/dL}$, serum Fe 10 $\mu\text{g/dL}$, B12, Folate : normal
- Dx: IDA

**Severe Hypochromia & Anisocytosis,
Poikilocytosis: Iron Deficiency Anemia**



RDW: Normal + Abnormal



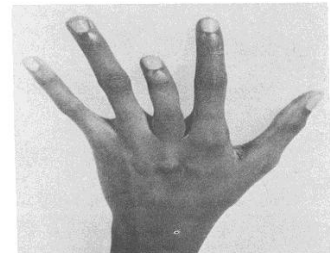
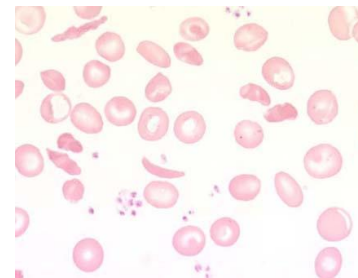
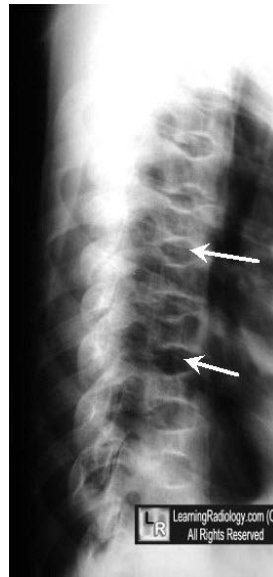
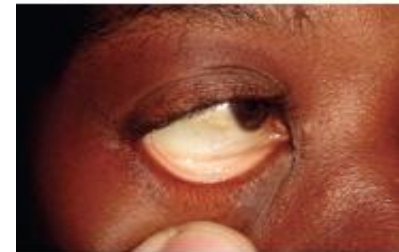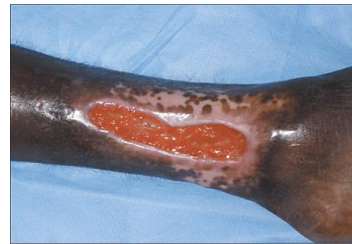Case TWO

18 yr old male complains of acute pain in his back, Dizziness, Fatigue, Shortness of breath and Headaches for the last 6 hours. He has had similar attacks.

Physical exam showed

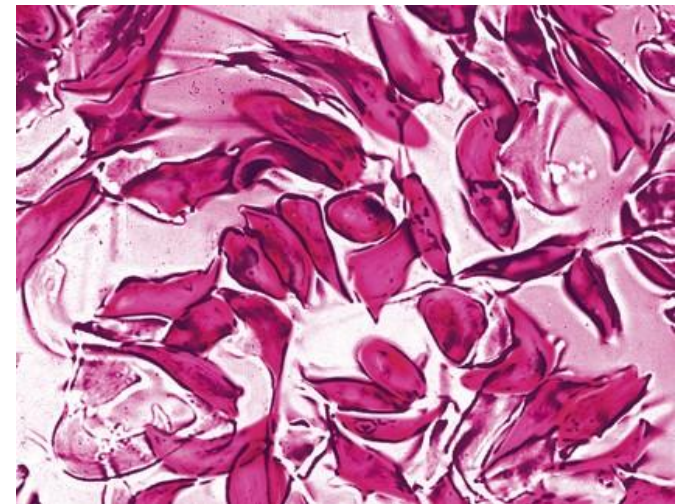
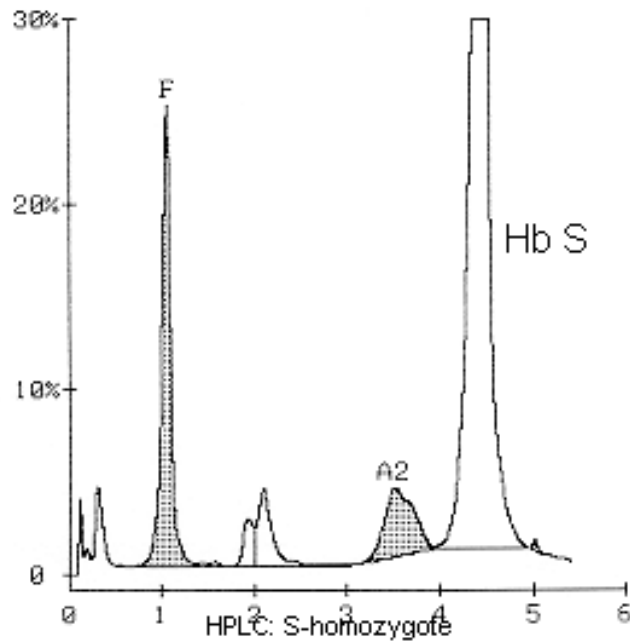
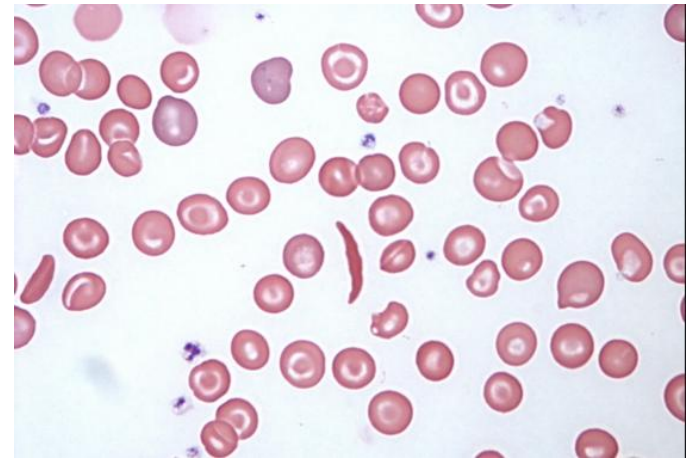
Lab and Xray test showed

Likely Diagnosis



Investigations

- Hb 9g/dl, MCV 80 fl, RDW 18%
- Blood film
- Sickling test: reducing agent
- Hg electrophoresis



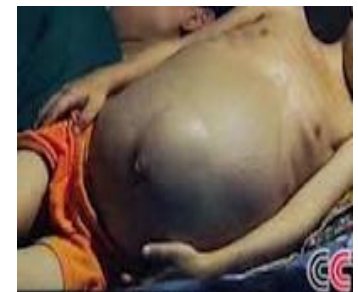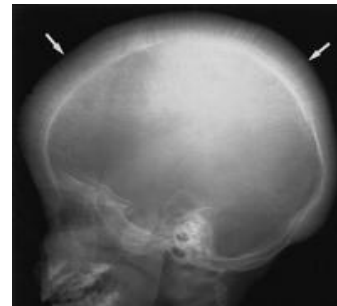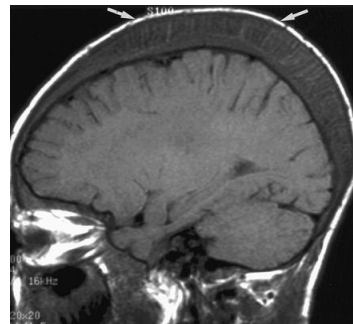
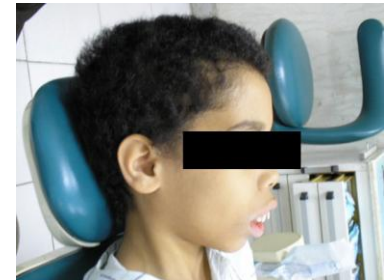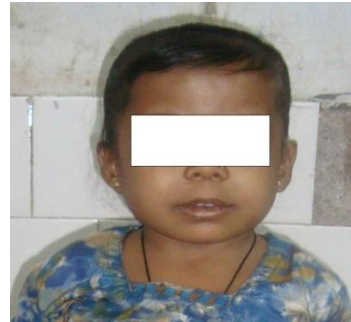Case Three

13 yr old male complains of skin pigmentation, abdominal swelling and pallor. He has been receiving blood transfusions since the age of 9 months.

Physical exam showed

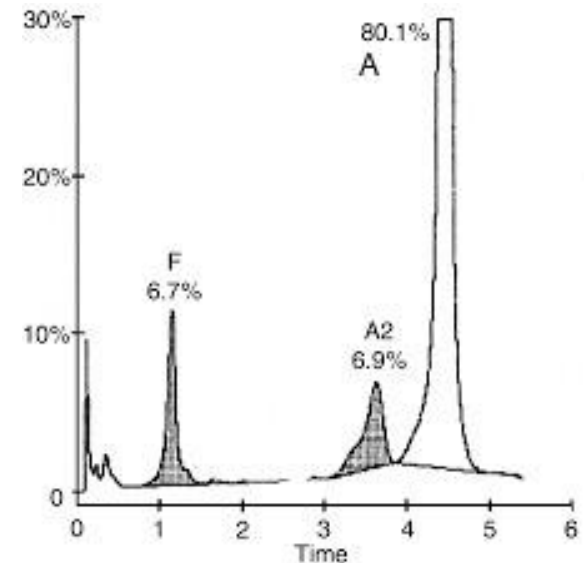
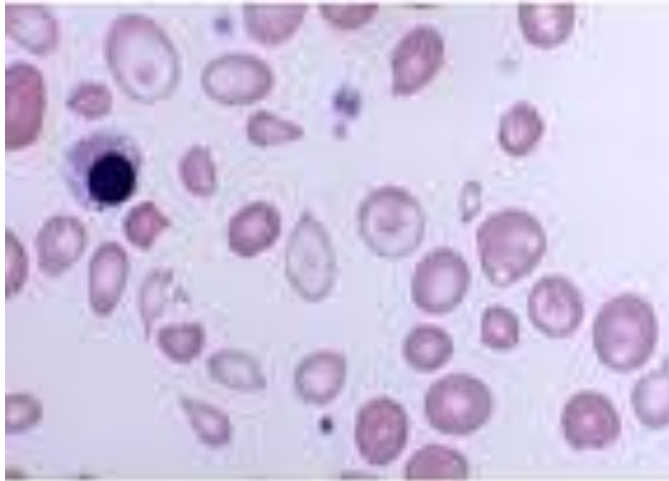
Lab and Xray test showed

Likely Diagnosis



Investigations

- Hb 5.6g/dl, MCV 55 fl, RDW 18%, Retcs 12%
- Blood film
- Serum Ferritin 6000ng/ml
- Hb electrophoresis

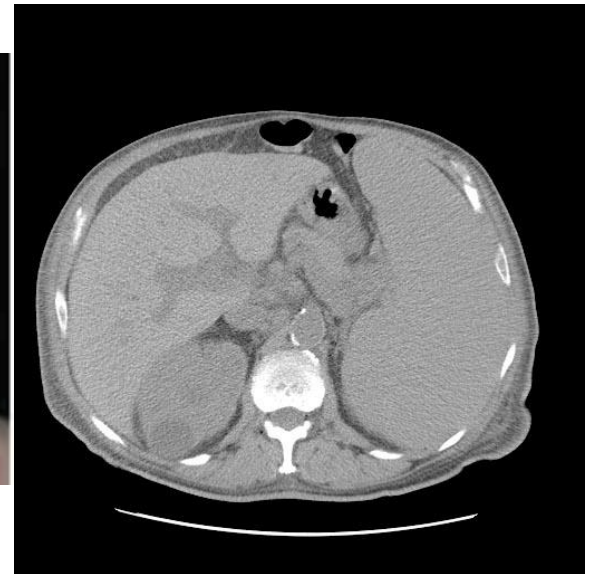
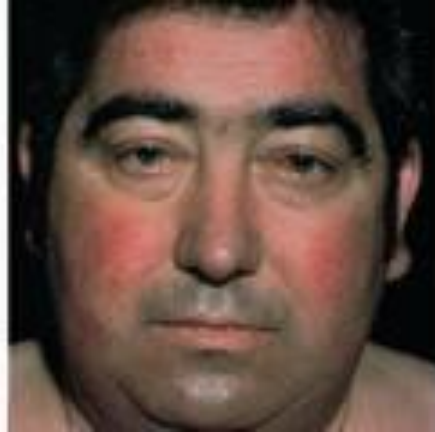
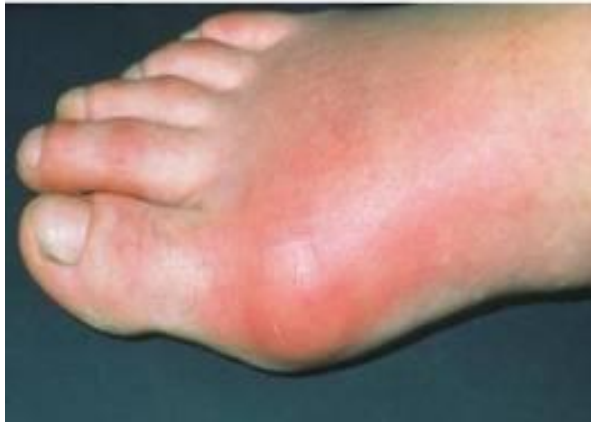Case four

50 yr old man complains for several weeks of hotness in his face, itching and severe acute pain in his big toe.

Physical findings

Likely diagnosis

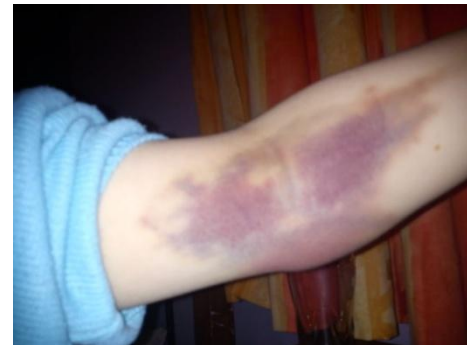

Investigations

- Hb 19, WBC 17,000, Platelets 500K
- Serum Uric acid 12mg/dl (<6)
- Serum erythropoietin 10 mU/ml (2-19)
- Jak2Mutation +

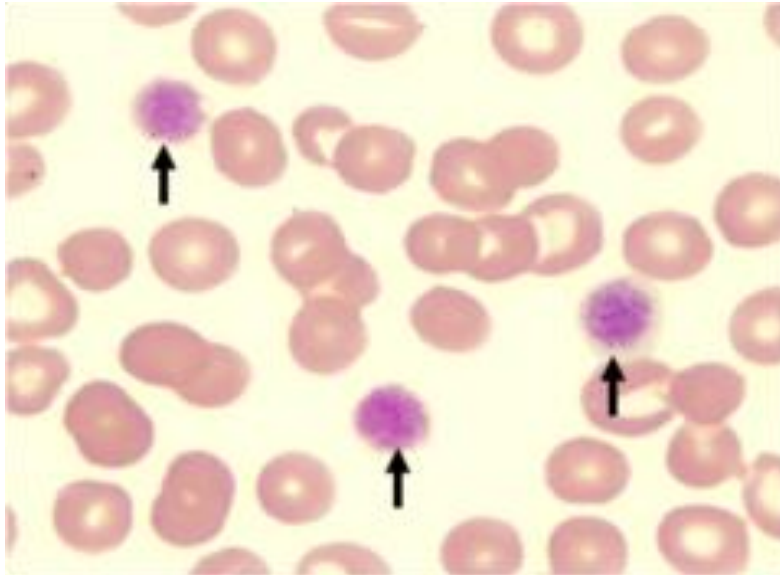
Case five

- 3 year old kid presented with unexplained large bruises over skin. Physical examination showed no signs of anemia. Abdominal palpation of the left upper quadrant showed palpable small movable mass.



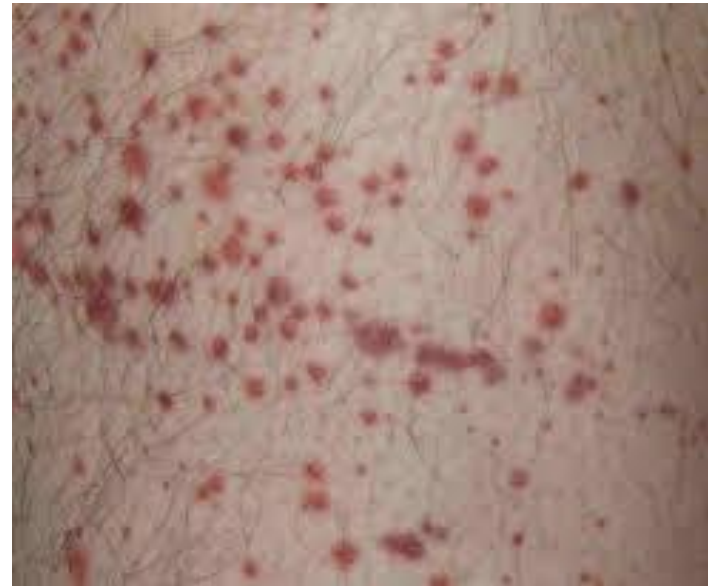
Investigations

- Hg 15, WBC 8, Plt 50
- Blood film
- PT, PTT: normal
- Bleeding time: 19 min (3-10)



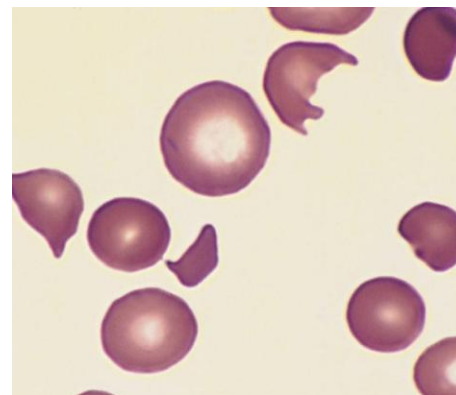
Case six

- 22 year old man, presented with widespread skin rash, fatigue, fever, confusion, decreased urination.
- Physical examination



Investigations

- Hg: 9, WBC 10, Plt 30
- Blood film
- PT, PTT: normal
- Bleeding time: 40 min
- Fibrin degradation products: negative
- Serum LDH: 1,000 (<400)
- Blood urea nitrogen: high

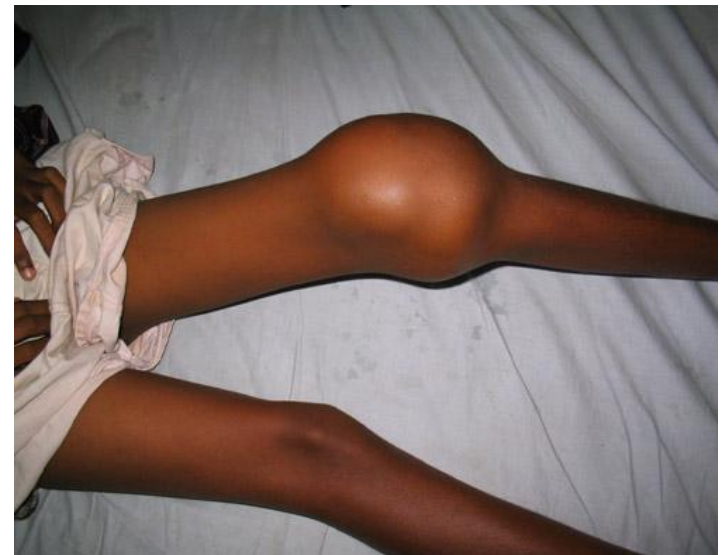
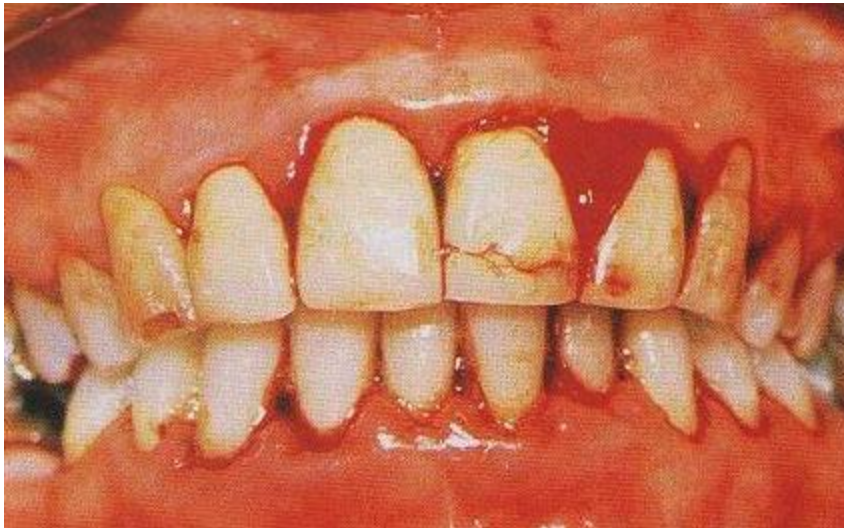
Case SEVEN

19 yr old boy complains of repeated attacks of large joint painful swelling especially in his knees for several years. His maternal uncle has similar condition.

Physical findings

Likely diagnosis



Investigations

- Hg: 6, WBC 8, Plt 180
- PT 12/12 s, PTT 100/30s, BT 7/20 min
- Mixing study: PTT: 30/30
- Factor VIII: <1%, Factor IX 100%

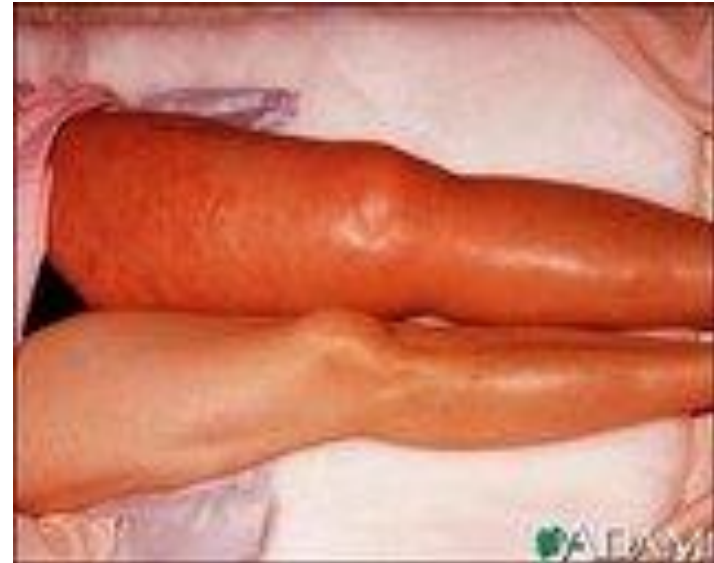- Diagnosis: Hemophilia A/ Severe

Case Eight

49 yr old lady complains of painful swelling and hotness of her L leg following coming back from visiting her relatives in USA. She had repeated attacks of cough with hemoptesis and shortness of breath.

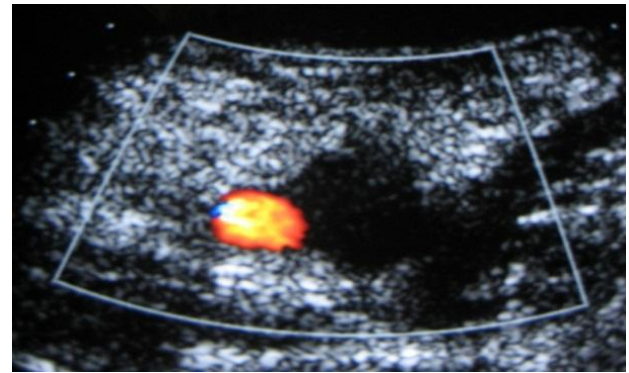
Physical findings

Likely diagnosis



Investigations

- 1- Duplex Us: DVT common femoral vein with PE
- 2- Found to have Protein C deficiency

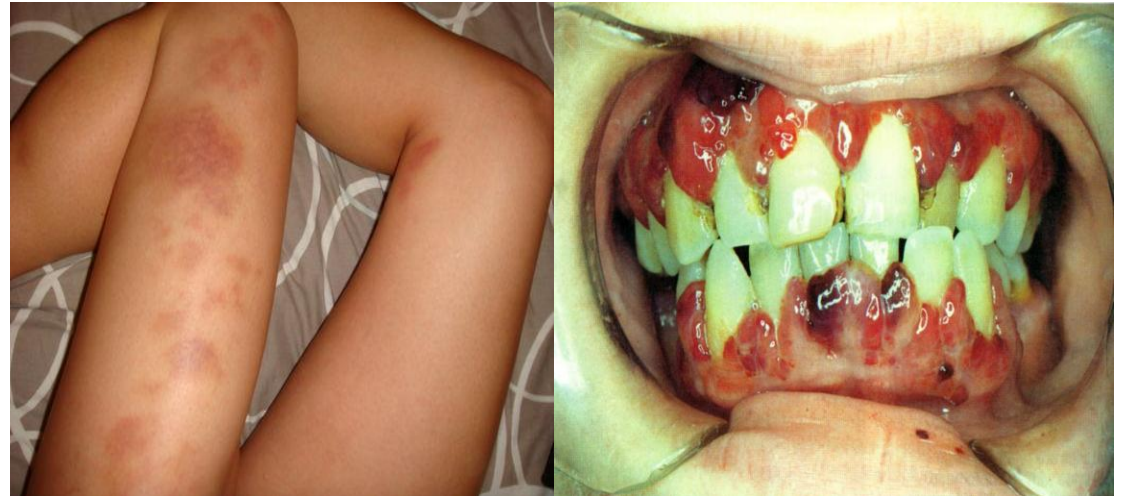


Case Nine

29 yr old lady complains of fever and painful gums for 1 week. She developed easy bruising and hemorrhagic spots on her trunk.

Physical findings

Likely diagnosis



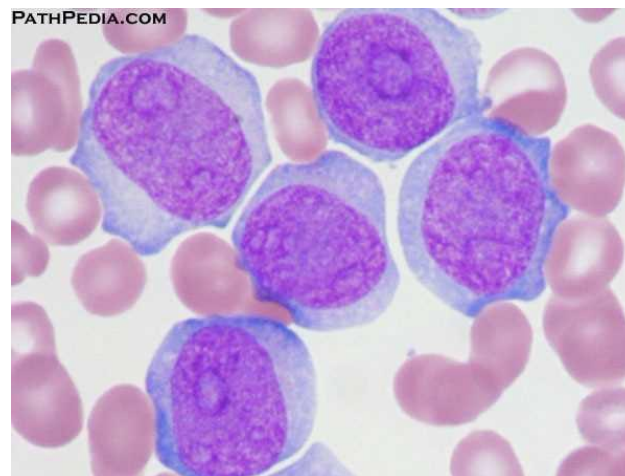
Investigations

Hb 8.5 g/dl, Wbc 37,000, 70% blasts, 12%
monocytes. Platelets 24

Serum uric acid 10 mg/dl

Bone marrow: 80% blasts

CD34 +

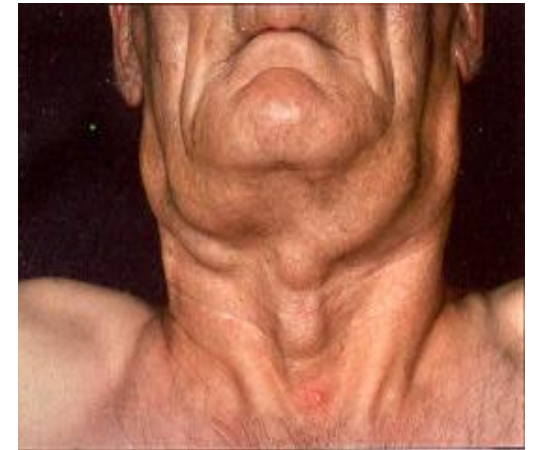
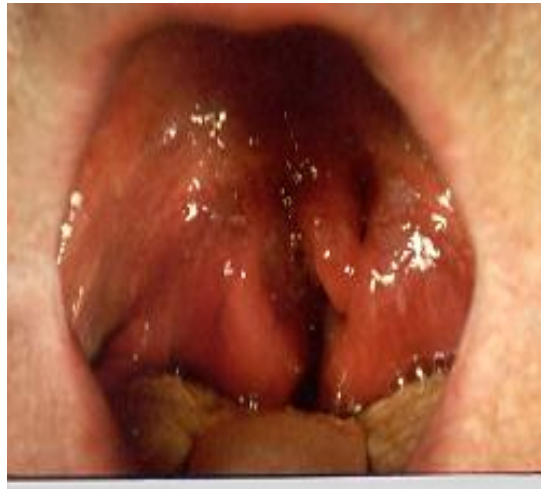
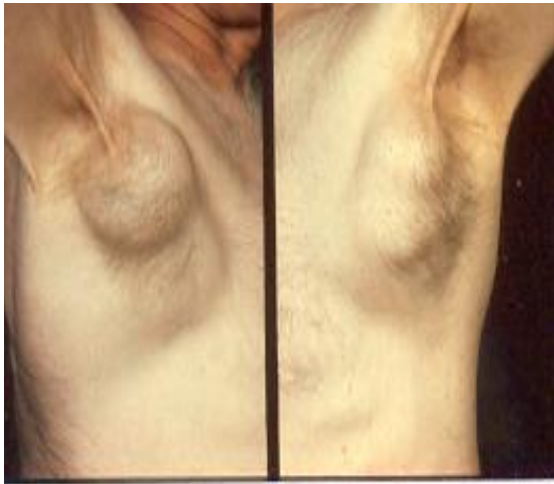
Case TEN

69 yr old man complains of fever and cervical and axillary swelling for several months with occasional fever and productive purulent cough.

Physical findings

Likely diagnosis



Investigations

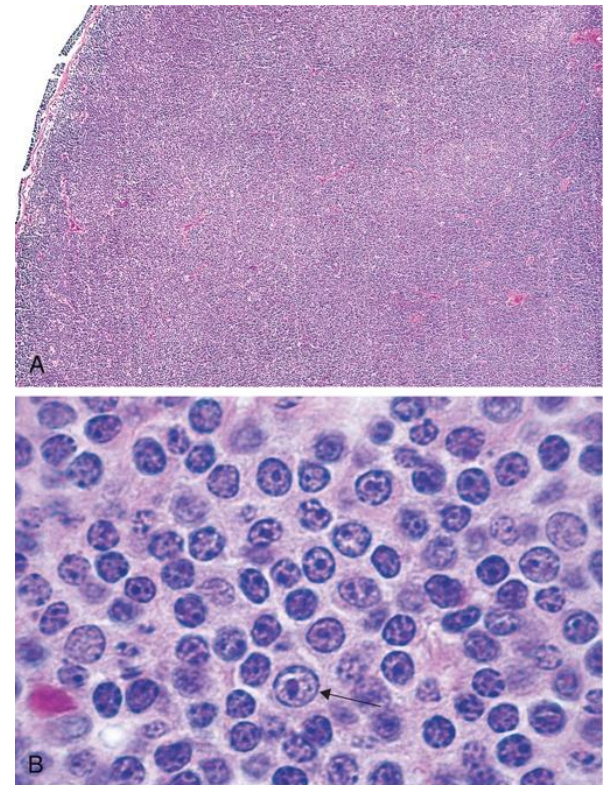
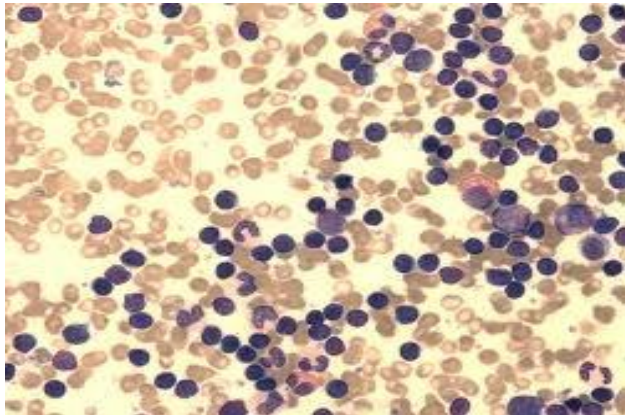
Hb 10, WBC 123, Plt 95

Blood film

Serum LDH: 1200

CD3: negative, CD20: positive

Dx: SLL/ CLL



Kumar et al: Robbins Basic Pathology, 9e.
Copyright © 2013 by Saunders, an imprint of Elsevier Inc.

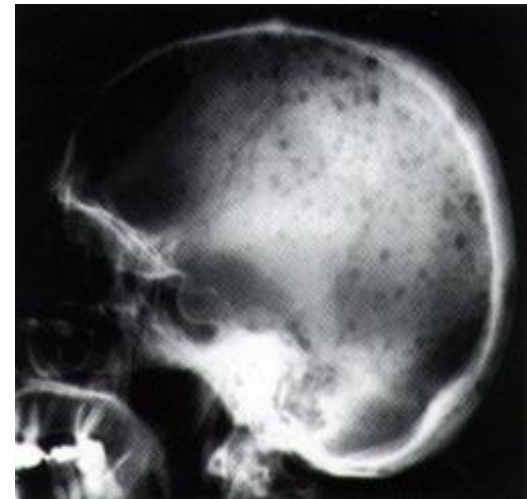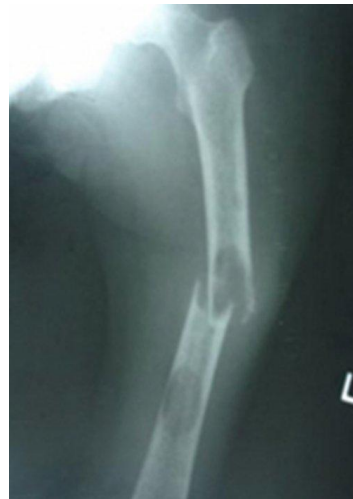Case ELEVEN

57 yr old man complains of back pain for several months and fracture of his L leg 2 days ago.

Lab and Xrays

Physical findings

Likely diagnosis



Investigations

- Hg: 7, WBC: 8, Plt 200
- Blood film
- ESR: 120
- BUN: high
- Serum albumin: low, B2 microglobulin: high
- Serum calcium: 13 mg/dL (5-10)
- Serum protein electrophoresis: peak IgG-Kappa

