# Brachial plexuses and axillary lymph nodes

## Introduction about nervous system

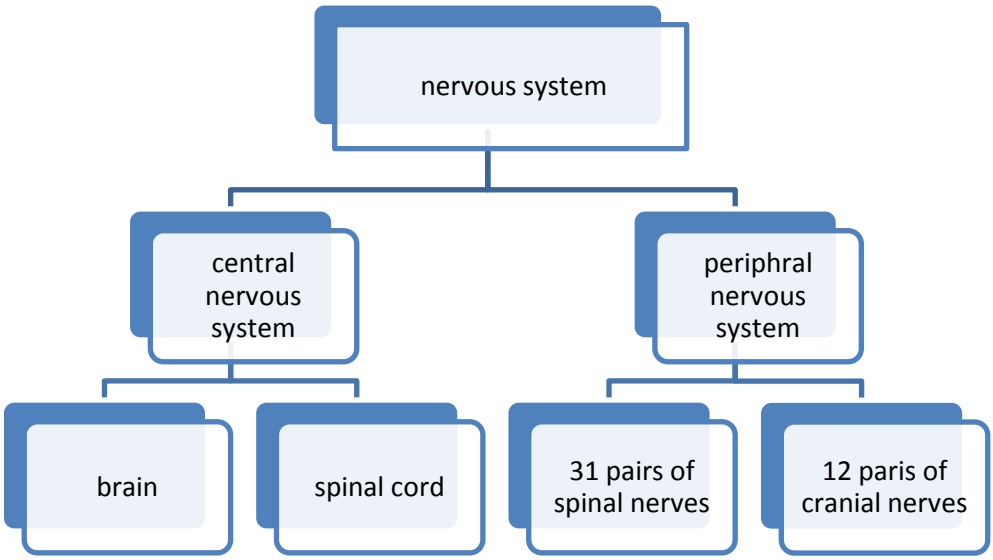


- **Central nervous system :**

  It consists of brain and spinal cord and it is called central nervous system because it consists of nerves (nerve cells) .

  Any trauma in these cells ( nerve cells) >> no regeneration , and it leaves a permanent disability .

  So .. the contents of central nervous system( brain and spinal cord) are protected by skull (for brain) and vertebral column (for spinal cord) >

- **Peripheral nevous system :**

  It consists of peripheral nerves , and they are divide according to their origin into :

  1. 31 Pairs of spinal nerve : they have an origin from spinal cord .
  2. 12 pairs of cranial nerve: they have an origin from inside the skull . (for-brain and brain stem ) .

     And they called a cranial nerves because they pass through foramen at the base of skull then they go to face , necj and shoulder.

- **Autonomic nervous system :** (sympathetic and parasympathetic nerves )
  It is an involuntary system , and sympathetic and parasympathetic nerves are woking in opposite direction .
  For example : sympathetic increase the heart beat and parasympathetic decrease the heart beat .

---

Note : peripheral nerves are axons

- Cell body in spinal cord and brain . peripheral are the axons (long axons ) which go to the muscles (skeletal and smooth) or to blood vessels and glands .
- Peripheral nerves can be :
  1. Motor ( somatic+ voluntary ) : that go to the muscles to do contraction.
  2. Sensory : it comes from the skin or from eye , ear (sensations) to the spinal cord then to the center .
     - Any nerve consist of motor or sensory or mixed of them .
     - In spinal cord there is 31 segment ( each pair of spinal nerve has on segment .. 31 pairs of spinal nerves = 31 segment )
     - Spinal nerve has :
       1. Anterior root
       2. Posterior root ( it has ganglia ( group of nerve cells "sensory nerves" ) )

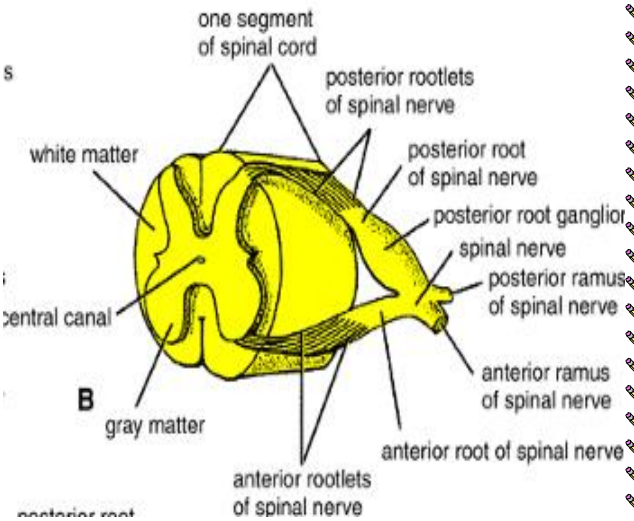


Both anterior and posterior root form a spinal nerve (mixed of sensory which enter the spinal cord and motor which leave the spinal cord )

>> for example : muscles of the hand innervated by ulnar nerve ( which pass behind themedial epicondyle, and if there is an injury in this nerve that will cause a claw hand )

**ulnar nerve come from T1 and C8 .

** IN T1 : the motor nerve of ulnar nerve pass through the anterior root then to the spinal nerve which divide into posterior ramus (which go to the back ) and anterior ramus ( to lateral and anterior ) then to the muscles of hand .. and that what we called "**motor** " , while **sensory** come from the skin of hand to the dorsal root of spinal cord .

**>> each spinal nerve has motor an sensory ( mixed nerve ) , and it has efferent fibers which go to skeletal muscles and afferent fibers (sensory) which enter the spinal cord , and it has posterior ramus and anterior ramus .**

- **IN BRACIAL PLEXUSES WE DEAL WITH ANTERIOR RAMUS ( which go to the upper limb)**
- Dorsal ganglia (sensory ganglia )
- The red one ( where is the arrow ) is motor and it comes from anterior gray horn of spinal cord (nerve cell ) and it can head dorsaly to the back or ventraly or lateral cutaneous (skin on lateral side ) or anterior cutaneous and to muscles ( muscular branches)
- Go to skin mean that it take a sensation from the skin then it turn back to spinal cord
- Motor mean that it goes to muscles with connection to the sympathetic trunk .

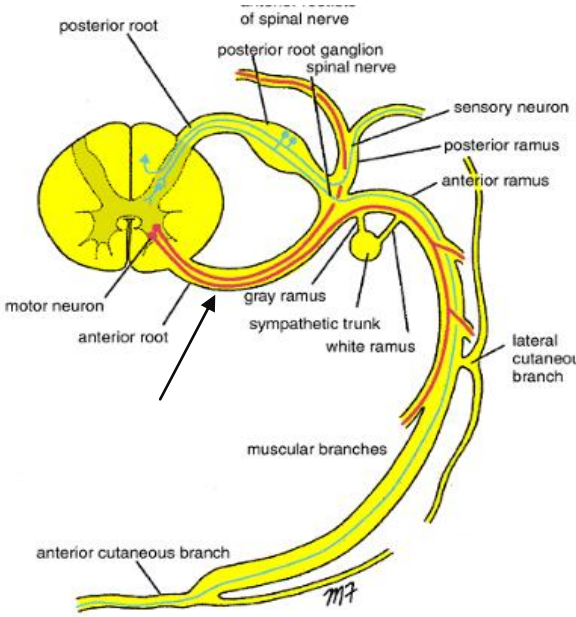


**** Note :**

- gray horn >> nerve cell , white horn >> fibers

---

**Plexuses** : it is a group of nerves

Brachial plexuses >> in cervical region

- spinal cord extend from the base of skull (foramen magnum ) to L2 ( lumber vertebra number 2 ) and the complementary of spinal cord ( L3,l4… ) is cauda equina .
- the region of cervical nerves consist of 7 vertebra but the number of pairs of spinal nerve is 8 , because first nerve is above the first cervical vertebra .
- cervical nerve are from C1 to C8 , and they gather to form the brachial plexuses which consist of three cords ( lateral , posterior , medial ) and nerves ( ulnar nerve , radial nerve , axillary nerve , musculocutaneous nerve )
- also lumber and sacral nerve form a lumboscaral trunk which supplies the lower limb .

---

- **brachial plexuses:** it consist of cervical spinal nerves that begin from C5 to T1 and sometimes they begin from C4 to T2 .
- (C5,C6,C7,C8,T1) >>are a cervical brachial plexuses.
- the root of brachial plexuses ( origin of cervical spinal nerves ) can be found between two muscles :
    1. scalenus anterior
    2. scalenus medius muscle

---

Autonomaic system → sympathetic ( spread by spinal nerve )

Autonomaic system → Parasympathetic (cranial nerve )

And it is involuntary

Somatic system >> skeletal muscle .

---

# Brachial plexuses

Roots → trunks → divisions → cords → nerves

It starts by root ( C5-T1) OR (C4- T2) . which can be found between two muscles : scalenus anterior and scalenus medius muscle

## 1# TRUNKS : (in posterior triangle of the neck )

- **C5+c6 >> upper trunk**
- **C7>> middle trunk**
- **C8+T1 >> lower trunk**

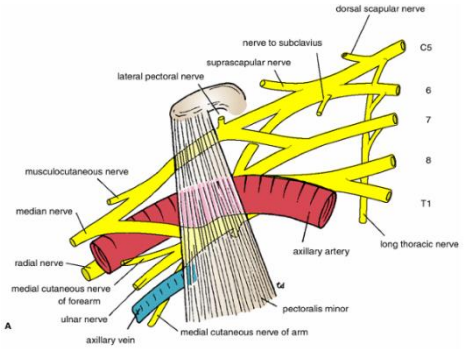

## #2 divisions :

- Each trunk divides into anterior division and posterior division and these divisions can be found behind the clavicle .

## #3 cords :

- Posterior 3 divisions of all trunks >> **posterior cord**
- Anterior division of upper and middle >> **lateral cord**
- Anterior division of lower trunk >> **medial cord**
  ** cords arranged according to their names ( around second part of axillary artery )
  ****lateral cord >>** lateral to the axillary artery
  ****posterior cord >>** posterior to the axillary artery
  ****medial cord >>** medial to the axillary artery .

## #4 branches of cords :

- **<u>Lateral cord : 3 branches</u>**
  1. **Lateral pectoral nerve ( for pectoralies major )**
  2. **Musculocutaneous nerve ( biceps , coracobrachialis, brachialis ,and ends as lateral cutaneous of arm )**
  3. **Lateral root of median nerve**

- **<u>Medial cord :</u>**
  1. **Medial pectoral nerve (pectoralies major and pectoralies minor )**
  2. **Medial cutaneous nerve of arm and medial cutaneous nerve of forearm (skin on the medial part of arm and forarma)**
  3. **Ulnar nerve ( between vein and artery )**

4. **Medial root of median nerve ( lateral to axillary artery**

- **<u>Posterior cord :</u>**
  1. **Upper and lower subscapular nerves ( subscapularies muscles )**
  2. **Thoracodorsal nerve ( to latissimus dorsi muscle )**
  3. **Axillary nerve**
  4. **Radial nerve**

# # other branches :

1. **Long thoracic nerve ( to srratus anterior muscle which do the rotation with tarpezius and it elevate the scapula above 90 degree) and it comes from the roots ( c5,c6,c7)**
2. **Nerve to subclavius ( c5 and c6 ) from the upper trunk and it supplies the subclavius muscle .**
3. **Suprascapular nerve : ( from the upper trunk ) and it supplies suprsspinatus and infraspinatus .**
4. **Dorsal scapular nerve : ( from c5 only ) and it supplies rhomboids and levator scapulae.**

**>>other branches from roots : Dorsal scapular nerve and Long thoracic nerve**
**>> other branches from upper trunk : Nerve to subclavius and Suprascapular nerve**

- **in the axilla .. three cords and their branches .**

---

- **<u>phrenic nerve</u> : ( cervical spinal nerve (c3,c4,c5) )**

**this nerve is motor to the diaphragm which is very important in respiration .**

- **90 % of respiration is the descend of diaphragm .**

---

- **lateral pectoral nerve : supplies pectoralies major**
- **Musculocutaneous : supplies biceps , coracobrachialis, brachialis**
- **Medial pectoral nerve : supplies pectoralies( major + minor )**
- **Cutaneous nerve : upper lateral cutaneous and lower lateral cutaneous.**
- **Posterior cutaneous nerve**
- **Medial cutaneous nerve of arm ( from T1 " thoracic spinal nerve number 1 " )**
- **Lateral side of axilla (T2 ) lateral cutaneous branch of the second intercostal nerve (intercostobrachial) supplies the skin on the medial side of the arm**
- **Medial cutaneous nerve : for foram**
- **Ulnar nerve : ( C8+T1) >> to the muscle but there is no branches in arm , only in forarm and hand.**
- **Medial root of median nerve : from medial cord .**
- **Lateral root of median nerve : from lateral cord**
- **Posterior cord : subscapulaies muscles ( upper and lower )**
- **Axillary nerve enter the quadrangular space**
- **Radial nerve : ( triceps , brachialis and extensor muscles ) it passes through the radial groove on back then to the lateral side of the arm .**
- **Lower subscapular nerve >>supplies teres major**
- **Axillary nerve >> supplies teres minor**
- **Thoracodorsal nerve >> supplies latissimus dorsi muscle (climbing muscle )**

## Axillary vein :

Begins on the lower border of teres major formed by brachial artery and basilica vein .

And ends at outer border of first rib and becoming a subclavien vein .

The main tuberties is the cephalic vein  and it is correspond to the branches of the axillary artery.

- First part :  The highest thoracic vein
- Second part :
    1. thoracoacromial vien
    2. lateral thoracic vein

- Lower part ( third part ) :
    1. subscapular vein
    2. anterior and posterior circumflex humeral veins

## Axillary lymph nodes

six groups of lymph nodes :

**#1 : anterior pectoral group :** ( anterior axillary because it is on the anterior wall of axilla  " deep to pectoralise major)

- Lying along the lower border of the pectoralis minor behind the pectoralis major
- receive lymph vessels from the lateral quadrants of the breast and superficial vessels from the anterolateral abdominal wall" above umbilic "  ( lateral half of breast )

**#2 posterior group :** subscapular group ( on posterior wall of axilla )

- Lying in front of the subscapularis muscle
- receive superficial lymph vessels from the back, down of the level of the iliac crests.

**#3 lateral group :**

- Lying along the medial side of the axillary vein
- receive most of the lymph vessels of the upper limb (except those superficial vessels draining the lateral side)

#4 central group :

- Lying in the center of the axilla in the axillary fat
- receive lymph from the above three groups
  first three groups >> central group >> apical group

**#5 Infraclavicular (deltopectoral) group:**

- they are located outside the axilla
- They lie in the groove between the deltoid and pectoralis major muscles
- receive superficial lymph vessels from the lateral side of the hand, forearm, and arm

**#6 apical group :**

- Lying at the apex of the axilla at the lateral border of the first rib
- receive the efferent lymph vessels from all the other axillary nodes.

The apical nodes drain into the subclavian lymph trunk

*On the left side : thoracic duct (lard duct )
*On the right side lymphatic duct
And both of them end on the begning of the brachiocephalic vein >> to the right atrium through super vena cava

- breast cancer >> enlarge >> spreading through lymp vessels
- medial half of breast >> internal mammary lymph

- nodes behind the sternum >> cervical lymph nodes
- some of surgeries in cancer breast are : mastectomy (removeing  of the breast )
- in early stages : simple mastectomy ( removing of part of the breast )

  and in both types : all lymph nodes are removed .

good luck .